



Case Report

Idiopathic scrotal calcinosis: A brief case report

Shivani Panhotra¹, Mohammad Jaseem Hassan^{1,*}, Shivali Sehgal¹, Sabina Khan¹,
Sujata Jetley¹

¹Dept. of Pathology, Hamdard Institute of Medical Sciences and Research, Delhi, India



ARTICLE INFO

Article history:

Received 08-11-2019

Accepted 30-11-2019

Available online 07-01-2020

Keywords:

Idiopathic calcinosis
scrotal calcinosis
dystrophic calcification
epidermal inclusion cyst

ABSTRACT

Idiopathic Scrotal Calcinosis (ISC) is a rare benign lesion involving the scrotal skin which is characterized by the presence of single or multiple calcified nodules. It usually presents during third decade of life. Many theories about the etiopathogenesis have been proposed, one of which is dystrophic calcification in the background of epidermal inclusion cyst over a period of time. Clinically, scrotal calcinosis may be confused with epidermal inclusion cysts, steatocystoma, cutaneous circumscription or benign tumors like lipoma, fibroma or others.

Our patient, 25 year old male presented with multiple painless swellings over scrotal skin. Clinical diagnosis of multiple sebaceous cysts was made. Surgical excision of all the nodules was done and sent for histopathological examination. Microscopy revealed presence of amorphous basophilic calcified deposits in the dermis, predominantly without epithelial lining. The histopathological diagnosis of idiopathic scrotal calcinosis was made.

© 2019 Published by Innovative Publication. This is an open access article under the CC BY-NC-ND license (<https://creativecommons.org/licenses/by/4.0/>)

1. Introduction

Idiopathic Scrotal Calcinosis (ISC) is a rare benign condition involving the scrotal skin which is characterized by the presence of single or multiple calcified nodules. Usually there is no associated systemic disease.¹

ISC usually presents between 20-40 years of age. These lesions are mostly asymptomatic but tend to increase in number and size before the appearance of clinical symptoms like heavy sensation of scrotum, discharge of chalky material or any other. Previous literature suggests various theories regarding pathogenesis of this lesion, one of which is dystrophic calcification in epidermal inclusion cyst over a period of time.²

Clinically, these lesions presents as hard white coloured nodules over scrotal skin. Epidermal inclusion cyst, cutaneous horn, steatocystoma, benign lesions like fibroma, lipoma may be considered in differential diagnosis because of the similar clinical presentation.³

Here, we present a case of ISC in 25 year old male who presented with multiple nodules over scrotum.

2. Case report

A 25 year old patient presented with multiple, varying sized nodules over scrotal skin. The patient noticed the increase in number and size of these nodules over a period of two years. There was no history of pain, prior trauma or any systemic disease. Clinical diagnosis of multiple sebaceous cysts was made. Surgical excision of all the nodules was done and sent for histopathological examination.

Gross examination showed a single grey brown skin flap which measured 4.3x3x2cm. External surface revealed multiple bosselations varying in size from 0.2 to 1.2cm in diameter. On cut section through these nodules, cystic cavity filled with chalky white areas identified(Figure 1).

Microscopic examination revealed unremarkable epidermis with presence of amorphous basophilic calcified deposits in the dermis, predominantly without epithelial lining. Few of these calcified deposits showed stratified

* Corresponding author.

E-mail address: jaseemamu@gmail.com (M. Jaseem Hassan).

squamous epithelial lining with or without granular cell layer (Figures 2 and 3). Multinucleated giant cells, few histiocytes and lymphocytes were also noted in the surrounding fibrocollagenous stroma (Figure 4). Skin adnexal structures were also present. No cytological atypia seen. The histopathological diagnosis of idiopathic scrotal calcinosis was made.

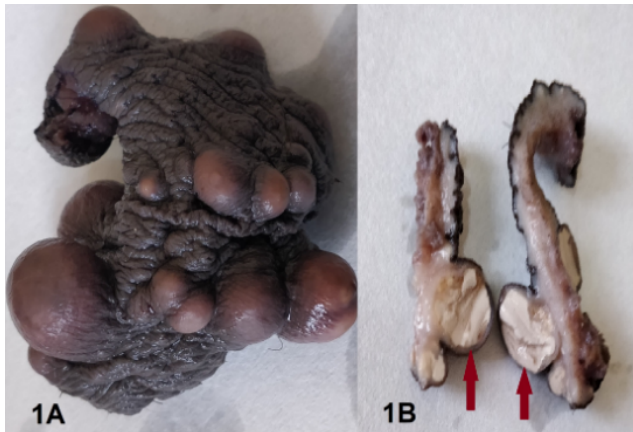

Fig. 1: 1A: Gross picture showing skin flap with multiple bosselations. 1B: Cut section of nodules show chalky white deposits (arrow)

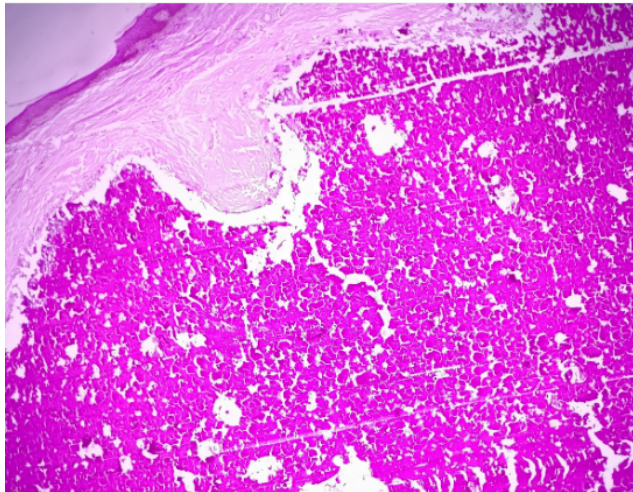


Fig. 2: Microphotograph showing epidermis with presence of amorphous basophilic calcified deposits in the dermis without epithelial lining. (H&E x 400)

3. Discussion

Idiopathic scrotal calcinosis is a rare benign disease that involves scrotal skin, first described by Lewinski.⁴ It usually presents with single or multiple nodules. The common age of presentation is third decade of life. These nodules are variable in size, dark in colour, firm in consistency and

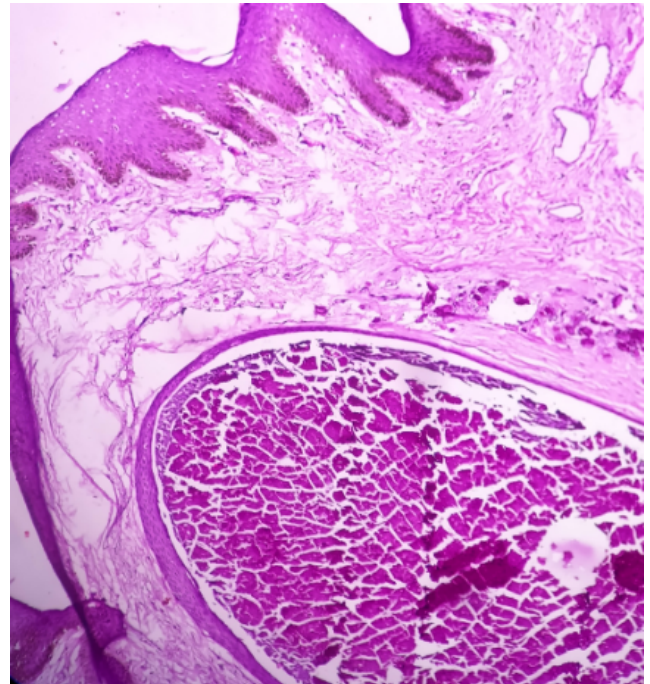


Fig. 3: Micro photograph showing dermal calcified deposits within cystic cavity lined by stratified squamous epithelial lining. (H&E x 100)

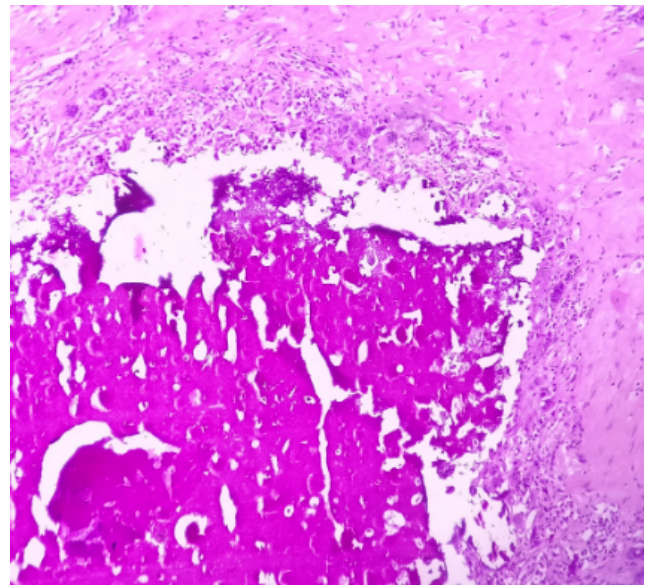


Fig. 4: Microphotograph showing multinucleated giant cells, few histiocytes and lymphocytes in the surrounding fibro collagenous stroma. (H&E x 100)

are usually asymptomatic. Pain, itching and chalky-white discharge may be associated symptoms. Our case presented with asymptomatic, multiple calcified nodules over scrotal skin in third decade of life, supporting previous literature.³

The etiopathogenesis of ISC is still controversial. Previous studies suggest that scrotal calcinosis is not associated with any disorder mainly the calcium–phosphorus metabolism or parathyroid hormonal imbalance, approving the idiopathic origin. Some authors believe that these nodules are because of dystrophic calcification in a background of epidermal inclusion cysts, or calcification secondary to trauma.⁵ Few studies found the peculiar pathological pattern of cysts (Pilar or epidermal), with calcification of keratinous material within the lumen. No cyst lining was observed in older lesion, as a result of enlargement of cyst and attenuation of cyst wall. Foreign body giant cells and mono nuclear inflammation was also found with resorption of cyst wall.

Histopathological findings show amorphous basophilic calcified deposits in the scrotal dermis. Multinucleated foreign body giant cells and chronic inflammatory cell infiltrate may be present.⁶ Our case histology revealed focal lining epithelium at places, which is stratified squamous epithelium with and without granular cell layer. These findings support that some of the scrotal calcinosis are as a result of dystrophic calcification from epidermal cyst.

Scrotal calcinosis may be clinically confused with epidermal inclusion cysts, steatocystoma, cutaneous circumscription or benign tumors like lipoma, fibroma. Our case was clinically diagnosed as multiple sebaceous cysts. Histopathology plays important role for definitive diagnosis.

Surgical excision is the only treatment of choice with excellent prognosis.⁷

4. Conclusion

ISC is a rare benign disease of scrotum, the etiology of which is still controversial. Majority favors dystrophic calcification of epidermal inclusion cysts. Surgical excision is only treatment for improving quality of life and has

excellent prognosis.

5. Conflict of interest

None

6. Source of funding

None

References

1. Saad AG, Zaatari GS. Scrotal Calcinosis: is it idiopathic? *Urology*. 2001;57:365.
2. Raed A, Hani A, Abumelha S. Idiopathic scrotal calcinosis: Case report. *Clin Case Rep Res*. 2017;3:1–2.
3. Tareen R, Ibrahim RM. Idiopathic scrotal calcinosis: A case report. *Int J Sur Case Rep*. 2018;44:51–53.
4. Karray O, Dhaoui A, Boulma R, Bellil K, Khouni H. Scrotal Calcinosis: two case reports. *J Med Case Rep*. 2017;11:312.
5. Andola SK, Patil SK. Idiopathic scrotal Calcinosis: A case series. *Indian J Dermatopathol Diagn Dermatol*. 2014;1:86–89.
6. Chang CI, Soon K, Kwi C, Seung M, Bae J, Ko J. Idiopathic Calcinosis Cutis of the scrotum: A Case Report. *Korean J Urol Oncol*. 2017;15:88–91.
7. Dubey S, Sharma R, Maheshwari V. Scrotal Calcinosis: Idiopathic or dystrophic? *Dermatol Online J*. 2010;16:5.

Author biography

Shivani Panhotra Demonstrator

Mohammad Jaseem Hassan Associate Professor

Shivali Sehgal Assistant Professor

Sabina Khan Associate Professor

Sujata Jetley Professor

Cite this article: Panhotra S, Jaseem Hassan M, Sehgal S, Khan S, Jetley S. Idiopathic scrotal calcinosis: A brief case report. *Arch Cytol Histopathol Res* 2019;4(4):352-354.