



## Guest Editorial

# Fibrous pseudotumor of scrotum –A relatively lesser known entity causing great concern

Indranil Chakrabarti<sup>1,\*</sup>, Shamim Akhter Mimi<sup>2</sup>

<sup>1</sup>Dept. of Pathology, North Bengal Medical College, Darjeeling, West Bengal, India

<sup>2</sup>Dept. of Pathology, Sylhet MAG Osmani Medical College, Sylhet, Bangladesh



## ARTICLE INFO

### Article history:

Received 01-03-2020

Accepted 05-03-2020

Available online 18-03-2020

© 2020 Published by Innovative Publication. This is an open access article under the CC BY-NC-ND license (<https://creativecommons.org/licenses/by/4.0/>)

### Keywords:

Fibrous pseudotumor

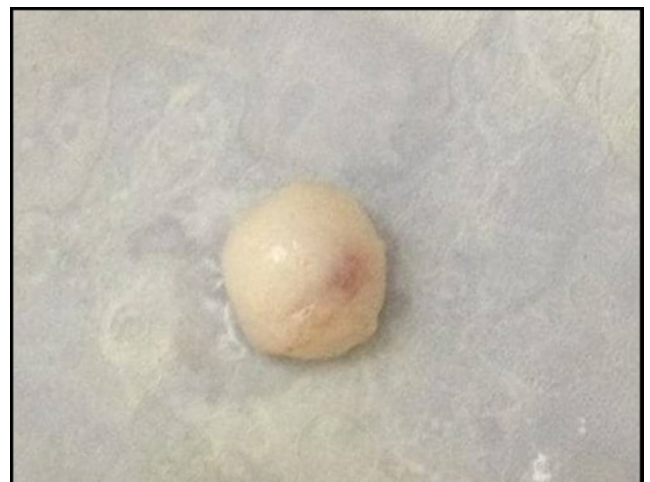Scrotum

testis

Sir,

A 47-year old male presented to the Surgery outpatient department with an intrascrotal swelling which he discovered accidentally on self palpation. There was no other complaint but the patient was very apprehensive about the swelling. No history of trauma, previous surgery or any infection could be elicited. On palpation, the mass appeared to be a small, firm, non-tender nodule measuring 1.2 x 1 x 0.5 cm near the epididymis and could be felt separately from the testis. On ultrasound, a mixed echoic nodular lesion measuring 10mm X 09 mm was noted in the right side of scrotum close to the lower pole of the right testis and appeared connected to the tunica. The right testis and right epididymis were reported normal. There was no associated hydrocele. The nodule was excised and sent for histopathological examination. There was no attachment to the tunica or epididymis. The specimen was an encapsulated, firm, white nodule measuring 1 cm in diameter. (Figure 1). On cut section, it was solid, white and appeared fibrotic. Histopathology revealed an encapsulated lesion showing densely hyalinized, plaque-like fibrous lesion with only scattered lymphocytes. (Figure 2). No

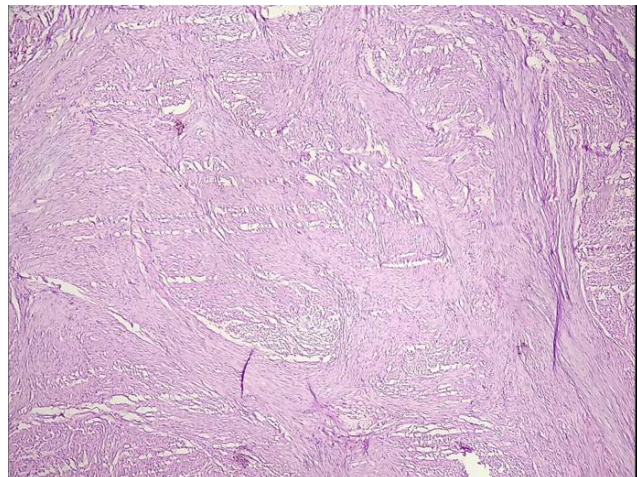
calcification was noted. There was no mitosis or atypia. The tumor was positive for vimentin and SMA. A diagnosis of fibrous pseudotumor was rendered. The patient was asymptomatic at 1 month of follow-up.



**Fig. 1:** Gross image of the encapsulated circumscribed resected mass

\* Corresponding author.

E-mail address: [drinch@rediffmail.com](mailto:drinch@rediffmail.com) (I. Chakrabarti).



**Fig. 2:** Photomicrograph showing the densely fibrotic and hyalinized lesion. Lymphocytes were sparse. (H &E stain, x100)

Intrascrotal tumors are a source of great anxiety and concern as most of testicular tumors are malignancies. But tumors of paratesticular tissue, though uncommon, are rarely malignant. Fibrous pseudotumors are benign tumors presenting as scrotal masses and often create great clinicopathological confusion with malignancies. Although it is the second most common benign tumor of paratesticular region following adenomatoid tumor, only around 200 cases have been published in literature.<sup>1</sup> Miyamoto et al reported a mean age of 42 years at presentation and also described three distinct histological variants: a) Plaque-like b) inflammatory sclerotic and c) myofibroblastic.<sup>2</sup> As per this classification, the case described here was plaque-like as the lesion showed dense fibrosis without significant inflammation. Fibrous pseudotumors can present as solitary or multiple (sometimes numerous) discrete or confluent, mostly unilateral, hard nodules or rarely band-like thickening encasing the testis (fibromatosis periorchitis).<sup>3</sup> The differential diagnosis include solitary fibrous tumor, leiomyoma, fibroma of tunica, neurofibroma, and idiopathic fibromatosis<sup>4</sup> and meticulous examination of histopathology and relevant immunohistochemistry may aid in clinching the diagnosis. These lesions are extratesticular

in location and may arise from tunica vaginalis, epididymis, spermatic cord or tunica albuginea. The exact cause of this benign fibro-inflammatory proliferative disorder is unknown; possible causes include prior trauma, infection, infarction etc or it may be idiopathic like our present case. Awareness of the lesion is very important to prevent unnecessary orchidectomy as surgical excision of fibrous tumors is curative in most of the uncomplicated cases. Imaging studies particularly Magnetic resonance imaging (MRI) studies are very helpful in ruling out testicular malignancies due to better delineation of extratesticular tissue by this modality.

### 1. Source of funding

None.

### 2. Conflict of interest

None.

### References

1. Dieckmann KP, Struss WJ, Frey U, Nahler-Wildenhain M. Paratesticular fibrous pseudotumor in young males presenting with histological features of IgG4-related disease: two case reports. *J Med Case Rep.* 2013;7(1):225.
2. Miyamoto H, Montgomery EA, Epstein JI. Paratesticular Fibrous Pseudotumor: A Morphologic and Immunohistochemical Study of 13 Cases. *Am J Surg Pathol.* 2010;34:569–574.
3. Germaine P, Simerman LP. Fibrous Pseudotumor of the Scrotum. *J Ultrasound Med.* 2007;26:133–138.
4. Seethala RR, Tirkes AT, Weinstein S, Tomaszewski JE, Malkowicz SB, et al. Diffuse fibrous pseudotumor of the testicular tunics associated with an inflamed hydrocele. *Arch Pathol Lab Med.* 2003;127:742–744.

### Author biography

**Indranil Chakrabarti** Associate Professor

**Shamim Akhter Mimi** Associate Professor

**Cite this article:** Chakrabarti I, Mimi SA. **Fibrous pseudotumor of scrotum –A relatively lesser known entity causing great concern.** *IP Arch Cytol Histopathology Res* 2020;5(1):1-2.