



Original Research Article

ER, PR status in leiomyomas- A study of 102 cases in rural Tamil Nadu

Anusha Babu Rajendran^{1,*}¹Dept. of Pathology, Melmaruvathur Athiparasakthi Institute of Medical Sciences and Research, Melmaruvathur, Tamil Nadu, India

ARTICLE INFO

Article history:

Received 17-02-2020

Accepted 18-02-2020

Available online 18-03-2020

Keywords:

Er

Pr

Leiomyoma

ABSTRACT

Introduction: Leiomyomas are benign tumors arising from the smooth muscle. The uterus is the most common site for the leiomyomas. The leiomyomas are steroid dependant tumors. Classically, believed to be estrogen dependant tumors are now being viewed as progesterone dependant also. Uterine leiomyomas are the most common cause for hysterectomies in the reproductive age group. Hence a knowledge of the hormone dependancy of these tumors can be used in the treatment of leiomyomas

Aim : To study the estrogen receptor(ER) and progesterone receptor (PR) status in leiomyomas of uterus.

Materials and Methods: A retrospective study of 331 hysterectomy specimens, done for leiomyomas, during the period June 2013-May 2015 was carried out of which 102 cases were chosen to study the ER, PR status in the leiomyomas by Immunohistochemical (IHC) staining.

Results: It was observed that out of 102 cases 61.76% were positive for estrogen receptor and 87.30% positivity was seen for PR

Conclusion: Leiomyoma (22.62%) was the commonest condition noted in hysterectomy specimens. The hormone receptor status of the leiomyoma shows that they are more progesterone dependant than estrogen dependant substantiating the fact that the growth of leiomyoma is dependent on the progesterone.

© 2020 Published by Innovative Publication. This is an open access article under the CC BY-NC-ND license (<https://creativecommons.org/licenses/by/4.0/>)

1. Introduction

Leiomyomas or fibroids are benign smooth muscle tumors, whose most common site of origin is the myometrium of the uterus. They are the most common cause for hysterectomy in the reproductive and peri-menopausal age group (CrameSF et al.¹ and Beum S et al.²). They are mostly asymptomatic but may present with menstrual disturbances (Gori M et al.³). These symptoms are mainly due to the hyper-estrogenic status associated with these tumors. The pathogenesis of these tumors is still unclear; however recent evidences show that they are due to the steroid hormones, estrogen and progesterone (Nissoe M et al.)⁴ This could warrant for alternative methods of treatment in avoidance of hysterectomies especially in the reproductive age group. This has given rise to

hormonal therapeutic agents such as GnRH analogues, Selective estrogen receptor modulators (SERMs), Selective Progesterone Receptor Modulator (SPRMs), Aromatase inhibitors (AI) etc. to be used in the treatment of fibroids. Since the leiomyomas are hormone dependant tumors, this study is an attempt to correlate the steroid receptor status of a leiomyoma for understanding the pathogenesis of the these tumors.

2. Materials and Methods

A retrospective study was carried out on 331 hysterectomy specimens, done for leiomyomas, during the period June 2013-May 2015, of this 102 cases were chosen to study the ER, PR status in the leiomyomas . Immunohistochemical (IHC) staining was used for staining the estrogen receptor and progesterone receptor in the leiomyomas.

* Corresponding author.

E-mail address: anusharajendran88@hotmail.com (A. B. Rajendran).

2.1. Inclusion criteria

Hysterectomy specimens done for leiomyomas received

2.2. Exclusion criteria

Myomectomy specimens, endometrial biopsies, endocervical biopsies, endometrial curetting were not included in the study.

Blocks from the archives which were inadequate for doing immunohistochemical staining (IHC), tissue blocks which were not fixed properly and those which showed inadequate staining after IHC were excluded and receptor status was assessed in 102 cases only.

Age Group: All women in reproductive and post-menopausal age group.

Sample Size: 102 cases

3. Methodology

3.1. Consent form

A informed consent form was obtained from the patients for the purpose of research on their hysterectomy specimens

3.2. Histopathological evaluation

H & E stained slides were retrieved for all 331 cases. The slides were reviewed and representative blocks were used from the leiomyoma sections for the purpose of IHC.

3.3. Special staining technique

Retrieved formalin fixed paraffin embedded tissue blocks of 100 cases of leiomyomas were checked for immunohistochemical staining. Some of the blocks were inadequate, few were poorly fixed thereby IHC could not be done and few on which IHC was done showed inadequate staining and hence only 102 cases were assessed for receptor status.

Special histological stain used was immunohistochemical stain: 102 cases of randomly selected leiomyomas were subjected to immunohistochemical staining for estrogen receptor and progesterone receptor, following standard staining protocol.

3.4. Scoring of the immunohistochemistry

The Allred system of scoring was used to score the immunohistochemical stain for estrogen receptor and progesterone receptor.

Sum of proportion score and intensity score is taken to say whether it is positive or negative

0-2-negative

3-8 -positive (Table 1)

4. Observation and Results

4.1. Estrogen receptor status in leiomyoma

In the present study estrogen receptor was studied in the leiomyoma of 102 cases out of the 331 cases.

It was observed that out of 102 cases 63 cases were positive for estrogen receptor which is 61.76%. (Figure 1)

ESTROGEN RECEPTOR

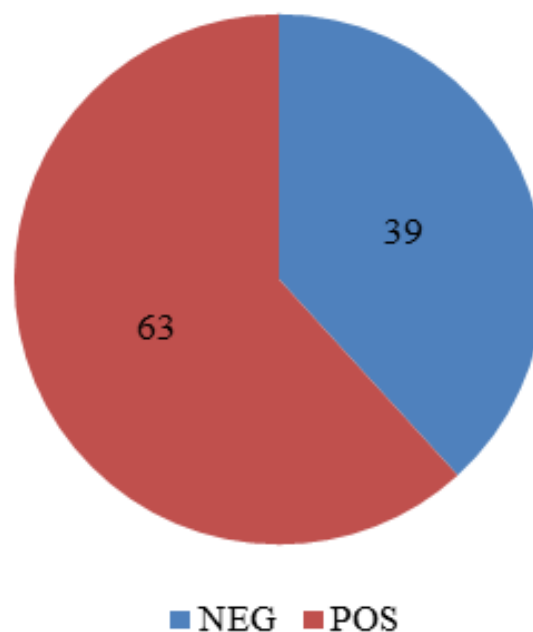


Fig. 1: Estrogen receptor status in leiomyoma

4.2. Estrogen receptor and corresponding type of leiomyoma

The 102 cases were classified on the basis of type of leiomyoma and it was observed that 66.7% (24 cases out of 36) of intramural and submucosal (22 cases out of 33) leiomyomas showed estrogen receptor positivity and only 51.5% (17 out of 33 cases) of subserosal leiomyomas had estrogen receptor positivity. The p-value (0.38) was calculated, for the correlation of type of leiomyoma with ER positivity using Fischer's Chi-square test. It was observed that the p-value was not significant statistically indicating that the ER expression is independent of the site of leiomyoma. (Table 2)

Depending on the Allred system of scoring, it was found that the median score for submucosal fibroid was '5' and it was '3' each for intramural and subserosal fibroids. This score had a p-value of 0.65 by Kruskal -Wallis test (non-parametric anova test). The p-value was not found to be statistically significant which indicates that the ER

Table 1: Allred semi-quantitative system of scoring of IHC for ER and PR

Proportion score	Observation	Intensity score	Observation
0	None	0	None
1	1%	1	Weak
2	1-10%	2	Intermediate
3	10-33%	3	Strong
4	33-66%		
5	66-100%		

Table 2: Estrogen receptor and corresponding type of leiomyoma

Type of leiomyoma	Estrogen receptor		Total	P-value
	Neg	Pos		
Submucosal	11 33.3%	22 66.7%	33	0.38
Intramural	12 33.3%	24 66.7%	36	
Subserosal	16 48.5%	17 51.5%	33	
Total	39 38.2%	63 61.8%	102	

Table 3: Estrogen receptor and corresponding type of leiomyoma (allred scoring)

Type of leiomyoma	Estrogen receptor score			P-value
	Freq.	Median	Min, max	
Submucosal	33	5	(0,8)	0.65
Intramural	34	3	(0,8)	
Subserosal	33	3	(0,8)	
Total	100	4	(0,8)	

expression does not differ in different sites. (Table 3)

4.3. Progesterone receptor status in leiomyoma

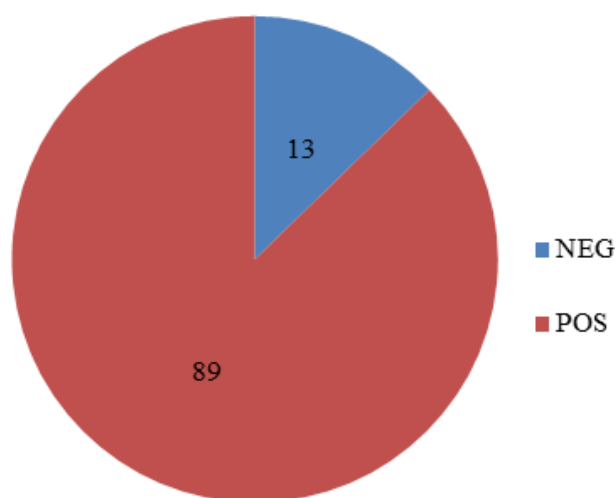
In this study progesterone receptor was studied in the leiomyomas of 102 cases. It was observed that out of the 102 cases subjected to immunohistochemistry for progesterone receptor in the leiomyomas, 89 cases were positive. This works up to 87.30% positivity. (Figure 2)

4.4. Progesterone receptor and corresponding type of leiomyoma

It was observed that out of the 102 cases, 33 cases which were sub-mucosal fibroids 27 were positive for PR (81.8%), in intramural fibroids, 33 out of 36 were positive (91.7%). 29 out of 33 (87.9%) cases of subserosal fibroids were positive for PR. The p-value (0.49) was calculated, for correlating the PR positivity and different types of leiomyoma, using Fischer's Chi-square test. It was observed that the p-value was not significant statistically indicating that the PR expression is independent of the site of leiomyoma. (Table 4)

Depending on the Allred system of scoring, it was found that the median score was ' 7 ' each for submucosal,

PROGESTERONE RECEPTOR

**Fig. 2:** Progesterone receptor status in leiomyoma

intramural and subserosal fibroids. This score had a p-value of 0.88 by Kruskal -Wallis test (non-parametric anova test). The median value was the same for all the types which

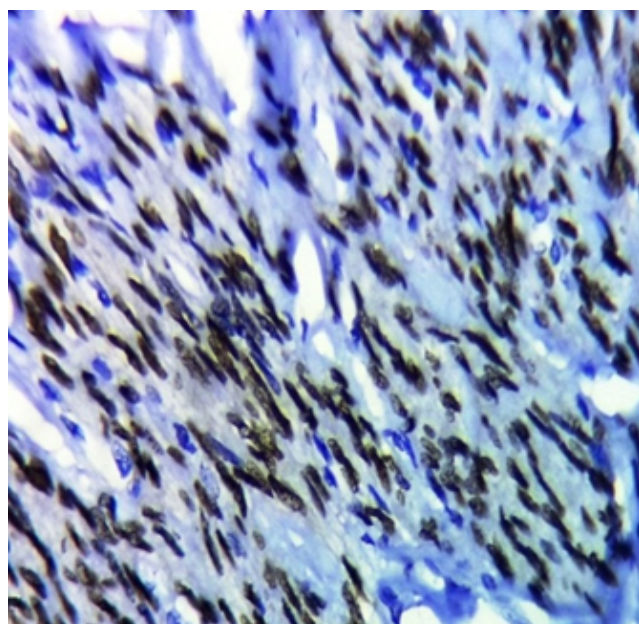
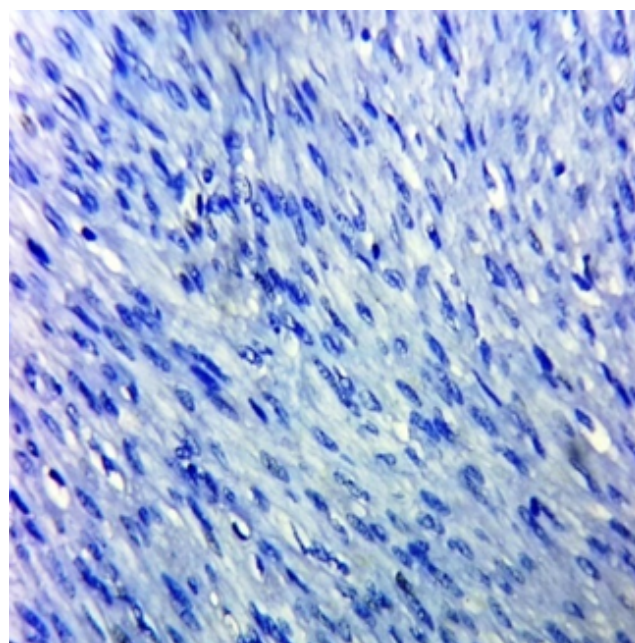
Table 4: Progesterone receptor and corresponding type of leiomyoma

Type of leiomyoma	Progesterone receptor		Total	P-value
	Neg	Pos		
Submucosal	6 18.2%	27 81.8%	33	0.49
Intramural	3 8.3%	33 91.7%	36	
Subserosal	4 12.1%	29 87.9%	33	
Total	13 12.7%	89 87.3%	102	

Table 5: Progesterone receptor and corresponding type of leiomyoma (allred scoring)

Type of leiomyoma	Progesterone receptor score			P-value
	Freq.	Median	Min, max	
Submucosal	33	7	(0,8)	0.88
Intramural	34	7	(0,8)	
Subserosal	33	7	(0,8)	
Total	100	7	(0,8)	

indicates that the PR expression does not differ in different sites. (Table 5)

**Fig. 3:** Estrogen receptor positive (40X-IHC)**Fig. 4:** Estrogen receptor negative(40X-IHC)

5. Discussion

The leiomyomas are the most common benign tumors of the uterus in the reproductive and post menopausal age group. This is of importance owing to the fact that they are the most common cause for hysterectomies in the women in the reproductive age group. In the current study of two years, 331 hysterectomies had leiomyomas. Of these 102 cases

were chosen at random for the study of ER, PR status

5.1. Estrogen receptor status in leiomyoma

1. In vitro studies by Kawaguchi K et al.⁵ suggests estradiol in the proliferation of leiomyoma. Recent studies suggested by Vu K et al.⁶ and Nissole M et al.⁴ show that leiomyoma shrinkage in GnRH pretreated cases is due to decrease in cellular proliferation. Studies have demonstrated that leiomyomas over

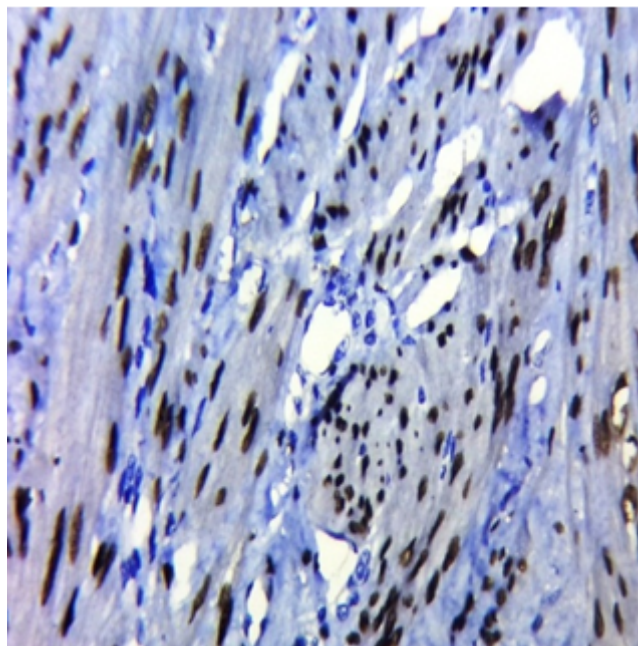


Fig. 5: Progesterone receptor positive (40X-IHC)

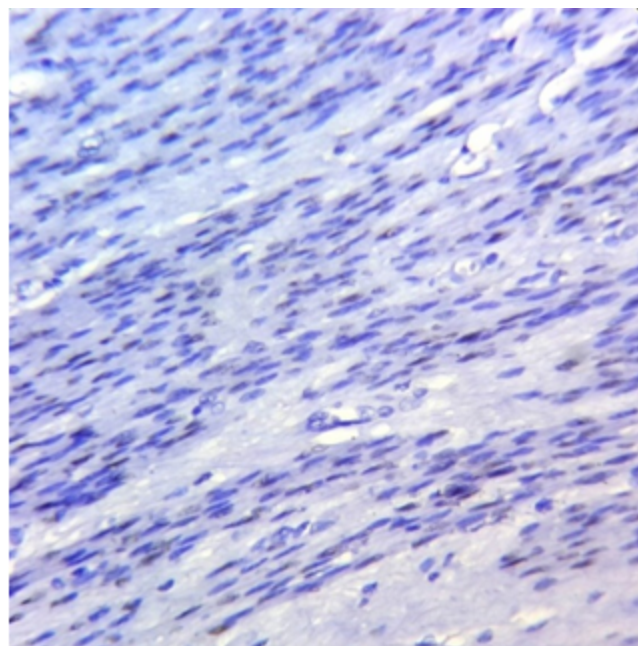


Fig. 6: Progesterone receptor negative(40X-IHC)

express aromatase p-450 which catalyses androgen conversion to estrogen, this by autocrine / paracrine mechanism influences the growth of the leiomyomas (Bulun SE et al.⁷ and Shozu M et al.⁸). Shozu M et al.⁸ also observed that GnRH agonist therapy down regulates aromatase p450 in the leiomyomas which is an additional mechanism for shrinkage of leiomyomas with GnRH agonist therapy. All these studies provide evidence that leiomyomas are under the influence of estrogen.

5.2. Estrogen receptor in leiomyoma and corresponding type of leiomyoma

It was observed that out of 102 cases, 63 cases were positive for estrogen receptor, which is 61.76%.

The 102 cases were classified on the basis of the type of leiomyoma and it was observed that 66.7% (24 cases out of 36) each of intramural and subserosal (22 cases out of 33) of submucosal leiomyomas showed estrogen receptor positivity and only 51.5% (17 out of 33 cases) had estrogen receptor positivity. The subserosal leiomyomas had lesser positivity for estrogen receptors than other types. These values were not statistically significant indicating that the estrogen receptor and type of leiomyoma are independent of each other.

5.3. Progesterone receptor status in leiomyoma

Various studies by Tiltman AJ et al.,⁹ Kawaguchi K et al.,⁵ Murphy AA et al.,¹⁰ Friedman AJ et al.¹¹ and Reinsch RC et al.¹² have suggested the critical role of progesterone in the growth of a leiomyoma.

In the current study, it was observed that out of the 102 cases subjected to immunohistochemistry, for progesterone receptor in the leiomyomas, 89 cases were positive. This works up to 87.25% positivity.

Nissole M et al.⁴ observed that PR content in the leiomyoma persisted well into the secretory phase compared to ER, this led them to propose three hypothesis to explain the effect of progesterone on leiomyomata. Firstly, leiomyomata could escape estrogen regulation that is present in normal tissue containing progesterone receptors. Secondly, leiomyoma may be more sensitive to estrogen, leading to permanently high concentrations of estradiol which could provoke a high PR content. Thirdly, increased expression of PR in leiomyoma could be the consequence of over-expression of functional ER, that results in increased organ sensitivity to estradiol (Brandon DD et al.¹³).

5.4. Progesterone receptor and corresponding type of leiomyoma

It was observed that out of the 102 cases, 33 cases which were submucosal fibroids 27 were positive for PR (81.8%),

in intramural fibroids 33 cases out of 36 were positive (91.7%). 29 out of 33 (87.9%) cases of sub-serosal fibroids were positive for PR. The maximum progesterone receptor positivity was seen with intramural myomas. These values were not statistically significant indicating that the progesterone receptor and type of leiomyoma are independent of each other.

6. Conclusion

Leiomyoma (22.62%) was the commonest condition noted in hysterectomy specimens. The hormone receptor status of the leiomyoma shows that they are more progesterone dependant than estrogen dependant substantiating the fact that the growth of leiomyoma is dependent on the progesterone. This also opens the gates for a more conservative mode of treatment using anti-progestins and avoiding hysterectomy. It is thus concluded that, leiomyomas are estrogen and progesterone dependant tumors with various endometrial changes associated with them which could be due to the hormonal influence. This however needs further studies on a larger scale to establish the association and for the detailed understanding of the mechanisms involved in the pathogenesis.

6.1. Limitations

The blocks from the archives which were retrieved were excluded based on their fitness for IHC and finally only 102 cases could be taken up for IHC analysis for ER and PR in the leiomyomas, this could be the reason for the results not being statistically significant for correlation. Had a larger number been analysed, the data could have become statistically significant.

The Allred system of semi-quantitative scoring was used, a computerized quantitative method could give a better idea of the positivity for the receptors corresponding to the endometrial changes.

7. Source of funding

None.

8. Conflict of interest

None.

References

1. Cramer SF, Patel A. The Frequency of Uterine Leiomyomas. *Am J Clin Pathol.* 1990;94(4):435–438.
2. Begum S, Khan S. Audit of leiomyoma uterus at Khyber Teaching Hospital, Peshawar. *J Ayub Md Coll.* 2004;16(2):46–49.
3. Gowri M, Mala G, Murthy S, Nayak V. Clinicopathological study of uterine leiomyomas in hysterectomy specimens. *J Evol Med Dent sci.* 2013;2(46):9002–9009.
4. Nisolle M, Gillerot S, Casanas-Roux F, Squifflet J, Berliere M, et al. Immunohistochemical study of the proliferation index, oestrogen receptors and progesterone receptors A and B in leiomyomata and normal myometrium during the menstrual cycle and under gonadotrophin-releasing hormone agonist therapy. *Hum Reprod.* 1999;14(11):2844–2850.
5. Kawaguchi K, Fujii S, Konishi I, Okamura H, Mori T. Ultrastructural study of cultured smooth muscle cells from uterine leiomyoma and myometrium under the influence of sex steroids. *Gynecol Oncol.* 1985;21(1):32–41.
6. Vu K, Greenspan DL, Wu TC, Zacur HA, Kurman RJ. Cellular proliferation, estrogen receptor, progesterone receptor, and bcl-2 expression in GnRH agonist-treated uterine leiomyomas. *Hum Pathol.* 1998;29(4):359–363.
7. Bulun SE, Simpson ER, Word RA. Expression of the CYP19 gene and its product aromatase cytochrome P450 in human uterine leiomyoma tissues and cells in culture. *J Clin Endocrinol Metab.* 1994;78(3):736–743.
8. Shozu M, Sumitani H, Segawa T, Yang HJ, Murakami K, et al. Inhibition of in situ expression of Aromatase P450 in Leiomyoma of the Uterus by Leuprorelin Acetate. *J Clin Endocrinol Metab.* 2001;86(11):5405–5411.
9. Tiltman AJ. The Effect of Progestins on the Mitotic Activity of Uterine Fibromyomas. *Int J Gynecol Pathol.* 1985;4(2):89–96.
10. Murphy AA, Kettel LM, Morales AJ, Roberts VJ, Yen SS. Regression of uterine leiomyomata in response to the antiprogestone RU 486. *J Clin Endocrinol Metab.* 1993;76(2):513–517.
11. Friedman AJ, Barbieri RL, Doubilet PM, Fine C, Schiff I. A randomized, double-blind trial of a gonadotropin releasing hormone agonist (leuprolide) with or without medroxyprogesterone acetate in the treatment of leiomyoma uteri. *Fertil Steril.* 1988;49(3):404–409.
12. Reinsch RC, Murphy AA, Morales AJ, Yen SSC. The effects of RU 486 and leuprolide acetate on uterine artery blood flow in the fibroid uterus: A prospective, randomized study. *Am J Obstet Gynecol.* 1994;170(6):1623–1628.
13. Brandon DD, Erickson TE, Keenan EJ, Strawn EY, Novy MJ, et al. Estrogen receptor gene expression in human uterine leiomyomata. *J Clin Endocrinol Metab.* 1995;80(6):1876–1881.

Author biography

Anusha Babu Rajendran Assistant Professor

Cite this article: Rajendran AB. ER, PR status in leiomyomas- A study of 102 cases in rural Tamil Nadu. *IP Arch Cytol Histopathology Res* 2020;5(1):3-8.