



## Case Report

# Adenomyomatous polyp – A culprit for infertility: rare case report

Ekta Rani<sup>1,\*</sup>, Nikita Goyal<sup>2</sup>, Prabhjot Kaur<sup>2</sup>, Neha Bhardwaj<sup>2</sup>, Hitesh Marwah<sup>2</sup>

<sup>1</sup>Dept. of Pathology, GGS Medical College, Faridkot, Punjab, India

<sup>2</sup>Dept. of pathology, Adesh Institute of Medical Sciences and Research, Bathinda, Punjab, India



### ARTICLE INFO

#### Article history:

Received 09-02-2020

Accepted 18-04-2020

Available online 11-06-2020

#### Keywords:

Adenomyomatous

Polyp

Infertility

Smooth muscle

### ABSTRACT

Adenomyomatous polyp is a rare subtype of endometrial polyp. About 1.3% of endometrial polyps are adenomyomatous polyps. It affects females of fourth decade and above. This polyp is comprised of smooth muscles, endometrial glands and endometrial stroma. We report a case of 38-year female with history of secondary infertility. To the best of our knowledge, no case of adenomyomatous polyp has ever been presented with the complaint of inability to conceive, in the literature.

© 2020 Published by Innovative Publication. This is an open access article under the CC BY-NC license (<https://creativecommons.org/licenses/by-nc/4.0/>)

## 1. Introduction

Adenomyomatous polyp is a rare subtype of endometrial polyp in which smooth muscle is the prominent stromal component.<sup>1</sup> About 1.3% of endometrial polyps are adenomyomatous polyps.<sup>2</sup> This lesion affects the females of fourth decade and later. Grossly it is very difficult to distinguish adenomyomatous polyp from ordinary endometrial polyp.<sup>3-5</sup> This polyp is comprised of smooth muscles, endometrial glands and endometrial stroma.<sup>1</sup>

There was no history of hormonal therapy. We report a case of 38-year female with history of secondary infertility.

## 2. Case Report

A 38 years female presented with a complaint of secondary infertility to the OPD at Adesh institute of medical sciences and research, Bathinda. There was no history of hormonal therapy. Hysteroscopy guided polypectomy under general anaesthesia was performed and the specimen was sent to the department of Pathology. On gross examination, a polypoidal grey white to tan tissue measuring

0.6x0.6x0.2cm was received. Hematoxylin stained slides examined show a polypoidal tissue lined by columnar to flattened lining epithelium. Subepithelium show small to elongated endometrial glands embedded in an edematous stroma. Intermixed are seen intersecting fascicles of smooth muscle fibres along with scattered blood vessels and chronic inflammatory infiltrate comprising of Lymphocytes, plasma cells and eosinophils. On histopathology Adenomyomatous polyp was the diagnosis (Figures 1 and 2).

## 3. Discussion

Endometrial polyps of adenomyomatous type are rare. The origin is focal hyperplasia of basalis leading to the localized overgrowth of endometrial tissue containing variable amount of endometrial glands, stroma, smooth muscles and blood vessels. These polyps are sessile or pedunculated masses, single to multiple and vary in sizes from 0.5cm to 3 cm in diameter or may be larger.<sup>6</sup>

It is known that Adenomyomatous polyp usually seen in fourth decade and later in females which is in concordance to our case.

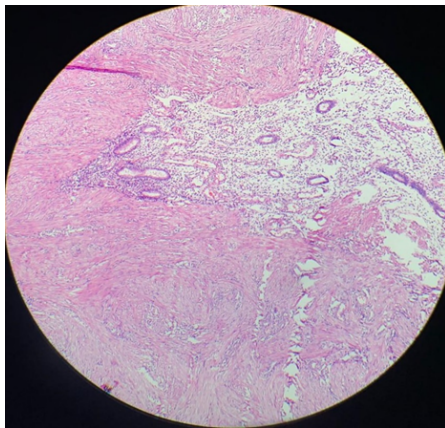
There is no history of any hormonal therapy in the present case that is similar to the studies of Fitzhugh et al,<sup>3</sup>

\* Corresponding author.

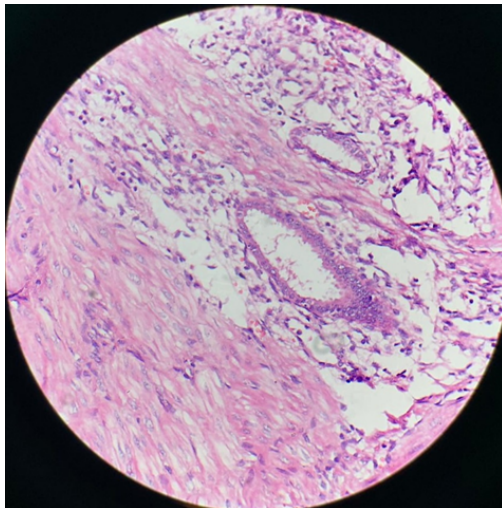
E-mail address: [eku.2001@gmail.com](mailto:eku.2001@gmail.com) (E. Rani).

**Table 1:** Review of cases of adenomyomatous polyp in literature and comparison with present case

Authors	Patient age	Hormonal therapy (tamoxifen)	Symptoms	Year of publication
Nasu et al <sup>1</sup>	63	Yes	None	1997
Fitzhugh et al <sup>3</sup>	32	No	Menometrorrhagia	2008
Takeuchi et al <sup>7</sup>	64	Yes	None	2005
Nasu et al <sup>8</sup>	37-57	No	Menorrhagia	1995
Sato et al <sup>4</sup>	33	No	None	2007
Silverberg SG <sup>5</sup>	44	No	Menorrhagia	1975
Huang et al <sup>9</sup>	66	No	Postmenopausal bleeding	2017
Babu et al <sup>6</sup>	23	No	None	2012
Bhagyalakshmi et al <sup>10</sup>	25	No	Menorrhagia	2018
Present case	38	No	Secondary infertility	



**Fig. 1:** H&E(10x)- shows endometrial glands embedded in an edematous stroma. Intermixed are seen intersecting fascicles of smooth muscle fibres.



**Fig. 2:** H&E(40x)- Endometrial gland and stroma along with smooth muscle fibres.

Nasu et al.<sup>8</sup> Sato et al<sup>4</sup>, Silverberg SG,<sup>5</sup> Huang et al,<sup>9</sup> Babu et al<sup>6</sup> and Bhagyalakshmi et al.<sup>10</sup> Only two authors Nasu et al,<sup>1</sup> and Takeuchi et al<sup>7</sup> have history of tamoxifen therapy.

The most common presenting symptom is the bleeding per vaginum either menorrhagia or post-menopausal bleeding (Fitzhugh et al<sup>3</sup>, Nasu et al,<sup>8</sup> Silverberg SG<sup>5</sup>, Huang et al<sup>9</sup> and Bhagyalakshmi et al.<sup>10</sup>) In the studies of Nasu et al,<sup>1</sup> Sato et al<sup>4</sup> and Babu et al<sup>6</sup> the patients were asymptomatic. Our case is unique in the way of presentation as secondary infertility. To the best of our knowledge, no case of adenomyomatous polyp has ever been presented with the complaint of inability to conceive, in the literature.

About 1.3% of endometrial polyps are adenomyomatous polyps.<sup>2</sup> Incidence of endometrial polyps is higher in women treated with tamoxifen (8 to 36 %) than in untreated women (0-10 %)<sup>7</sup>

Treatment modalities depends on the size of the polyp and symptoms. Polypectomy suffices in small, asymptomatic lesions while hysterectomy is mandatory for the larger one causing frustrating symptoms.

#### 4. Conclusion

Adenomyomatous polyp of endometrium is a rare entity which could be a possible culprit for the infertility.

#### 5. Source of Funding

None.

#### 6. Conflict of Interest

None.

## References

1. Nasu K, Arima K, Yoshimatsu J, Miyakawa I. Adenomyomatous Polyp of the Uterus in a Patient Receiving Tamoxifen. *Jpn J Clin Oncol.* 1997;27(5):350–2.
2. Peterson WF, Novak ER. Endometrial Polyps. *Obstet Gynecol.* 1956;8:40–9.
3. Fitzhugh VA, Murphy G, Heller DS. Adenomyomatous polyp of the endometrium: a case report. *J Reprod Med.* 2008;53:231–4.
4. Sato H, Nanjo H, Tanaka H, Tanaka T. Arias-Stella reaction in an adenomyomatous polyp of the uterus. *Acta Obstet Gynecol Scand.* 2007;86(1):106–8.
5. Silverberg SG. Adenomyomatosis of Endometrium and Endocervix—A Hamartoma? *Am J Clin Pathol.* 1975;64(2):192–9.
6. Babu YP. Adenomyomatous polyp of the uterus: Report of an autopsy case and review of the literature. *J Forensic legal med.* 2012;19:236–8.
7. Ascher SM, Johnson JC, Barnes WA. MR imaging of the uterus in postmenopausal women receiving tamoxifen therapy for breast cancer: histopathological correlation. *Radiol.* 1996;200:105–10.
8. Nasu K, Sugano T, Miyakawa I. Adenomyomatous polyp of the uterus. *Int J Gynecol Obstet.* 1995;48(3):319–21.
9. Huang C, Hong MK, Ding DC. Endometrial adenomyoma polyp caused postmenopausal bleeding mimicking uterine malignancy. *Gynecol Minim Invasive Ther.* 2017;6:129–31.
10. Bhagyalakshmi. Diffuse multiple giant adenomyomatous endometrial polyps- a rare case report. *JNTR Uni Health Sci.* 2018;7:216–8.

## Author biography

**Ekta Rani** Assistant Professor

**Nikita Goyal** Junior Resident

**Prabhjot Kaur** Junior Resident

**Neha Bhardwaj** Junior Resident

**Hitesh Marwah** Junior Resident

**Cite this article:** Rani E, Goyal N, Kaur P, Bhardwaj N, Marwah H. Adenomyomatous polyp – A culprit for infertility: rare case report. *IP Arch Cytol Histopathology Res* 2020;5(2):163-165.