



## Case Report

# Pineal parenchymal tumour of intermediate differentiation: A case report

Jyoti Verma<sup>1</sup>, Ram Nawal Rao<sup>1,\*</sup>

<sup>1</sup>Dept. of Pathology, Sanjay Gandhi Postgraduate Institute of Medical Sciences, Lucknow, Uttar Pradesh, India



## ARTICLE INFO

### Article history:

Received 26-11-2019

Accepted 21-05-2020

Available online 11-06-2020

### Keywords:

Pineal parenchymal tumours  
Pineal parenchymal tumours with  
Intermediate differentiation  
Pineoblastoma and Pineocytoma.

## ABSTRACT

Pineal parenchymal tumours (PPTs) represent one third of the pineal region tumours. PPTs are subdivided into pineocytoma (PC), pineoblastoma (PB) and PPT with intermediate differentiation (PPTID). We report radiological, morphological and immunochemical features which permit to grade these tumours. Tumors of the pineal region can arise from multiple cellular origins and thus represent a very heterogeneous group of pathologies. Within the subgroup of pineal parenchymal tumors, there is a histopathologic spectrum ranging from pineocytoma to pineal parenchymal tumors of intermediate differentiation to pineoblastoma. The current World Health Organization classification and the histopathologic features of the pineal parenchymal tumor subtypes with intermediate differentiation are described.

© 2020 Published by Innovative Publication. This is an open access article under the CC BY-NC license (<https://creativecommons.org/licenses/by-nc/4.0/>)

## 1. Introduction

Pineal parenchymal tumour of intermediate differentiation (PPTID) is a pineal gland neoplasm, introduced as a distinct entity, first defined by the World Health Organization in 2000, represent a very rare class of central nervous system neoplasm. It is intermediate in malignancy between pineocytoma and pineoblastoma and corresponds to grade II or III neoplasm. Pineal region tumours are uncommon and account for less than 1% of all intracranial tumours and 10% of pineal parenchymal tumors. Sixty percent (60%) of PPT were classified as Pineocytomas before PPTID was introduced as a distinct entity. Because of limited number of reported cases, classification of PPT is still a matter of controversy.

## 2. Case Report

A 13 year old female presented in Neurosurgery department with complaints of holocranial headache and progressive vision loss, ataxia and urinary incontinence since three months. MRI showed a well defined lesion measuring 5x3x2.5 cm in the posterior third ventricle involving

pineal gland region, extending to foramen monro, causing compression of aqueduct leading to hydrocephalus. Lesion was T1 hypointense and T2 isointense. Intra-operative findings showed a pinkish, soft lobulated, mildly vascular and partly suckable mass.

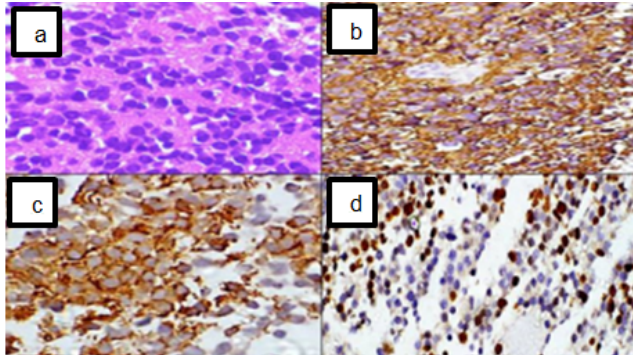
Squash cytology smears was cellular and composed of medium to large sized monomorphic tumour cells with vesicular chromatin, conspicuous nucleoli, well defined nuclear margin and moderate amount of clear to eosinophilic cytoplasm with sprinkling of lymphocytes at places.

Histopathological examination of squash remnant and definitive biopsy showed a tumor composed of diffuse sheets and nests of tumor cells of medium to large size. Focally the tumour cells showed moderate amount of clear cytoplasm with centrally placed round to oval nuclei, regular nuclear membrane, granular evenly dispersed chromatin, occasional prominent nucleoli (Figure 1a). Areas of diffuse sheets with eosinophilic granular cytoplasm was evident. Few of the cells were of plasmacytoid morphology with eccentrically placed nuclei and voluminous eosinophilic cytoplasm. Rosette formation was not evident and mitosis was low. No necrosis was evident.

\* Corresponding author.

E-mail address: [rnawalrao@gmail.com](mailto:rnawalrao@gmail.com) (R. N. Rao).

Differential diagnosis of Pineal parenchymal tumours, Papillary tumour of pineal region, Central neurocytoma, Germ cell tumour, Ependymoma, Oligodendroglioma and Metastasis were considered. Immunohistochemistry was performed and tumour cells are positive for Synaptophysin (Figure 1 b) and NSE immunostaining (Figure 1c) in tumour cells. Ki 67 proliferation index was 10-12% (Figure 1d). Pineal parenchymal tumour of intermediate differentiation was made on basis of above histopathological findings and immunohistochemical positivity of Synaptophysin, NSE and Ki proliferation index (5-6%) findings.



**Fig. 1:** (1a H&e) Section showed a tumor disposed in diffuse pattern, comprising of mild to moderately pleomorphic, round to oval hyperchromatic nuclei, salt and pepper chromatin, inconspicuous nucleoli and moderate amount of eosinophilic cytoplasm. Occasional rosette formation and frequent mitosis were noted. There was no evidence of necrosis, (1b) Synaptophysin immunostaining is positive in tumour cells, (1c) NSE immunostaining is positive tumour cells, and (1d) ki 67 proliferation index was 5-6%.

### 3. Discussion

Pineal parenchymal tumour of intermediate differentiation (PPTID) are rare neoplasm and little is known regarding their clinical course and patient outcome. It is an aggressive neoplasm with heterogeneity than pineocytoma and commonly present with local infiltration and distant CSF dissemination. This category includes tumours with histological features intermediate between pineocytoma and pineoblastoma or tumours that have mixed areas of both above entity.

The clinical presentation of a PPTID is similar to that of other pineal region masses. Diplopia and headache are the most common symptoms. If large enough, PPTID can cause hydrocephalus, leading to associated symptoms of elevated intracranial pressure such as ataxia.<sup>1</sup> PPTID have a broader patient age spectrum.

In 2007, PPTID was established as a distinct entity to categorize a group of tumours that were between pineoblastomas and pineocytomas in histological grade.<sup>2</sup> Although pineoblastomas and pineocytomas comprise the

majority of pineal parenchymal tumours, PPTID have reported rates between 10–20%.<sup>3</sup> Histologically, PPTID appear as diffuse sheets of small round uniform cells and are characterized by moderate cellularity, mild-to-moderate nuclear atypia and moderate mitotic activity. On immunohistochemical staining, these neoplasms are strongly positive for synaptophysin and neuron-specific enolase.

It has a wide range of reported mitotic counts from 0 to rarely >6/10 hpf in large published series. Jouvett A et al<sup>4</sup> proposed a prognostic grading of four grades: In low grade PPTID, 5 year survival is 74% and recurrence occurs in 26% of cases. In high grade PPTID, 5 year survival is 39% and recurrence occurs in 56% of cases. The presence of necrosis, mitotic rate and immunohistochemical expression of neurofilament protein are used to classify PPTIDs as grade II or III pathologically.<sup>5</sup> It has been defined that grade 2 tumour has <6 mitoses and strongly immunopositive for neurofilaments and grade 3 will have, >6 mitoses or <6 mitoses, but without strong immunostaining for neurofilaments.<sup>4</sup> Transformation of PPTID to Pineoblastoma has been seen.

In addition, clear-cut diagnostic criteria for PPTID were not defined until recently, which probably resulted in a number of false-positive cases of PB being reported.<sup>6</sup> This point is illustrated by the analysis of Fauchon et al.<sup>7</sup> who used stringent diagnostic criteria. In their series, overall survival at 5 years was only 10% in patients with PB, as compared with the 51% overall survival at 5-year follow-up.<sup>8</sup>

### 4. Conclusion

PPTID are extremely rare tumor entities, but because of paucity of literature and limited number, their optimal treatment options are also a challenge to define. Because of small number of cases and limited data available regarding pathological features and biological behaviour of PPTID, the relevance of grading criteria of pineal parenchymal tumors (PPTs) including mitotic count, NFP expression, and Ki-67 proliferation index requires confirmation by further studies. Criteria is yet to be established and the treatment strategy and prognostic outcome still remains controversial.

### 5. Source of Funding

None.

### 6. Conflict of Interest

None.

### References

1. Lutterbach J, Fauchon F, Schild SE, Chang SM, Pagenstecher A, Volk B, et al. Malignant Pineal Parenchymal Tumors in Adult Patients: Patterns of Care and Prognostic Factors. *Neurosurg*. 2002;51(1):44-56.

2. Amendola BE, Wolf A, Coy SR, Amendola MA, Eber D. Pineal tumors: analysis of treatment results in 20 patients. *J Neurosurg.* 2005;102(2):175–9.
3. Louis DN, Ohgaki H, Wiestler OD, Cavenee WK, Burger PC, Jouvet A, et al. The 2007 WHO Classification of Tumours of the Central Nervous System. *Acta Neuropathol.* 2007;114(2):97–109.
4. Komakula S, Warmuth-Metz M, Hildenbrand P, Loevner L, Hewlett R, Salzman K, et al. Pineal parenchymal tumor of intermediate differentiation: imaging spectrum of an unusual tumor in 11 cases. *Neuroradiol.* 2011;53(8):577–84.
5. Jouvet A, Saint-Pierre G, Fauchon F. Pineal parenchymal tumors: a correlation of histological features with prognosis in 66 cases. *Brain Pathol.* 2000;10:49–60.
6. Sato K, Kubota T. Pathology of pineal parenchymal tumors. *Progr Neurol Surg*;23:12–25.
7. Fauchon F, Jouvet A, Paquis P, Saint-Pierre G, Mottolese C, Hassel MB, et al. Parenchymal pineal tumors: a clinicopathological study of 76 cases. *Int J Radiat Oncol Biol Phys.* 2000;46(4):959–68.
8. Jouvet A, Saint-Pierre G, Fauchon F, Privat K, Bouffet E, Ruchoux MM, et al. Pineal parenchymal tumors: A correlation of histological features with prognosis in 66 cases. *Brain Pathol.* 2000;10:49–60.

### Author biography

**Jyoti Verma** Senior Resident

**Ram Nawal Rao** Professor

**Cite this article:** Verma J, Rao RN. Pineal **parenchymal tumour of intermediate differentiation: A case report.** *IP Arch Cytol Histopathology Res* 2020;5(2):177-179.