



Original Research Article

Lymph node tissue thyroglobulin washout measurement in metastatic papillary thyroid carcinoma

Luis E. Barrera-Herrera¹, Viviana Barrera-Penagos¹, Mauricio A Palau-Lázaro^{1,2}, Humberto Rivera-Gonzalez^{3,2}, Deyanira González-Devia^{4,2}, Jose A Hakim-Tawil^{5,2}, Javier A Romero-Enciso^{6,2}, Paula A Rodriguez-Urrego^{1,*}

¹Pathology and Laboratories/Fundación Santa Fe de Bogota, Colombia

²School of Medicine/Universidad de los Andes, Colombia

³Diagnostic Imaging/Fundación Santa Fe de Bogotá, Colombia

⁴Internal Medicine/ Fundación Santa Fe de Bogotá, Colombia

⁵Head and Neck surgery/ Fundación Santa Fe de Bogotá, Colombia

⁶Diagnostic Imaging/Fundación Santa Fe de Bogotá, Colombia



ARTICLE INFO

Article history:

Received 17-10-2020

Accepted 12-11-2020

Available online 30-12-2020

Keywords:

Papillary thyroid carcinoma

thyroglobulin

local lymph node assay

Neoplasm metastasis

ABSTRACT

Aims and Background: Papillary thyroid carcinoma is the most frequent subtype of thyroid carcinoma and usually has a favorable prognosis, however, locoregional metastases are reported in approximately 5-20% of the cases. Literature reports that when using a combination of ultrasound, fine needle aspiration and tissue thyroglobulin levels to diagnose metastases, sensitivity and specificity radically increase. The aim of this study was to validate tissue thyroglobulin measurement in local patients and compare these results to radiological and histopathological diagnosis.

Materials and Methods: A cross-sectional study was carried out to measure tissue thyroglobulin levels in lymph nodes obtained by fine needle aspiration and/or biopsy from patients with adenopathy suspected of metastatic papillary thyroid carcinoma. Tissue thyroglobulin was measured by chemiluminescence and was considered positive for metastatic papillary thyroid carcinoma when levels were ≥ 1.7 ng / mL in patients with a history of thyroidectomy and > 36 ng/mL in patients without a history of thyroidectomy (4).

Results: Our results confirm that the measurement of TTG by chemiluminescence can be made from the same tissue sample, giving the patient and the clinician greater diagnostic certainty.

Conclusions: TTG measurement through chemiluminescence is a low-cost technique that can improve diagnostic performance of pathological analysis. Levels can be measured from the same needle used in cytology/biopsy providing both the patient and clinician greater diagnostic certainty, increasing the diagnostic sensitivity and specificity of the procedure without the need for further invasive interventions.

Key Message: TTG measurement through chemiluminescence is a low-cost technique that can improve diagnostic performance of pathological analysis.

© This is an open access article distributed under the terms of the Creative Commons Attribution License (<https://creativecommons.org/licenses/by/4.0/>) which permits unrestricted use, distribution, and reproduction in any medium, provided the original author and source are credited.

1. Introduction

Well differentiated thyroid cancer, including papillary thyroid carcinoma (PTC), is usually considered as a disease with favorable prognosis. However, locoregional

metastases have been reported in approximately 5-20% of the cases.¹ Traditionally, for thyroid nodule diagnosis, assessment of recurrence and metastases evaluation, ultrasound is the initial recommended study.² It has an estimated sensitivity of 34.5% and specificity of 73.5%. Furthermore, implementation of fine needle aspiration (FNA) as diagnostic technique has increased sensitivity up to 75% and specificity up to 93.5%. In some cases, FNA

* Corresponding author.

E-mail address: Paula.Rodriguez@fsfb.org.co (P. A. Rodriguez-Urrego).

is not diagnostic due to the presence of cystic metastases that provide insufficient sample in order to give a definitive diagnosis. In that regard, some authors wash the needle and measure levels of thyroglobulin (Tg) in the FNA sample. When used these combined tests, the reported sensitivity and specificity reaches 100%.¹ This is the first study that verifies the validation of tissue Tg (TTG) in Colombia and Latin America, comparing radiology results, washout TTG and pathological diagnosis of FNA and/or lymph node biopsy.

2. Materials and Methods

A cross-sectional study was conducted in the pathology specimens obtained from all patients who underwent FNA and/or lymph node biopsy for suspicious metastatic PTC at the University Hospital Fundación Santa Fe de Bogotá between April 2015 and May 2016. This project was approved by the ethics committee of the University Hospital.

Abnormal ultrasound criteria included at least one of the following: microcalcifications, cystic changes, hyperechoic cortex, round shape and irregular margins.³ The radiologist performed ultrasound-guided FNA and/or lymph node biopsy.⁴ (iU22 or HDI 5000, Philips Medical Systems, Bothell, WA). Aspiration was done vacuuming with a 22-gauge needle connected to a 10 mL syringe, material was immediately smeared and fixed in 95% alcohol. If a biopsy was performed, the tissue was immediately fixed in 10% buffered formalin. As soon as both FNA and/or lymph node biopsy were completed, the needle used for the procedure was washed with 1 cc of normal saline solution and sent for Tg measurement by chemiluminescence (Beckman Coulter). TTG levels were considered suspicious for metastatic PTC when results were ≥ 1.7 ng/mL in patients with thyroidectomy history, and > 36 ng/mL in patients without thyroidectomy history.⁴ FNA and/or lymph node biopsy results were divided into the following diagnostic categories: benign, positive for metastatic malignancies and unsatisfactory (no representation of sampled tissue). Results were compared with follow up resection tissue when the patients underwent additional surgery.

3. Results

A total of 52 samples obtained from 39 patients with history of enlarged neck lymph nodes were submitted to biopsy due to suspicious ultrasound criteria.² 4 samples were excluded; 3 because of pre-analytical phase error and 1 due to inadequate location. 48 samples were included for final analysis which corresponded to 36 patients. There were 3 men (8,3%) and 33 women (91,7%), with a median age of 48 years (range 13–78 years), 29 (80,5%) corresponded to patients with previous thyroidectomy history. The

lymph node distribution by zone showed 58.3% (n=28) located in jugular zone levels II-III-IV, 14.6% (n=7) in supraclavicular/level IV, 10.4% (n=5) submandibular/ level Ib, 8.3% (n=4) paratracheal, 4.2% (n=2) spinal and 4.2% (n=2) central/ level VI.

From 48 samples, 44 (91.5%) had a satisfactory pathology sample and 4(8.5%) had an unsatisfactory pathology sample. Among the 44 satisfactory cases, 93.2% (n=41) had concordant pathology and TTG and 6.8% (n=3) had discordant pathology and TTG. Among concordant cases 68.3% (n=28) were true negative for PTC, and 31.7% (n=13) were true positive for metastatic PTC (Table 1). When considering the positive pathology and TTG concordant cases (n=13) only 9 had histological confirmation with concordant surgical resection (Table 2). Likewise, among 28 negative pathology and TTG concordant cases, only 4 underwent surgical resection, all of them ultimately consistent with the previous pathology and TTG results (Table 3). Regarding the analysis of the positive pathology and TTG concordant cases (n=13), the average TTG level was 3509, 22 ng/mL with a widespread range between 1.96 to 23.350 ng/mL. Average Anti-thyroglobulin antibodies (Anti-Tg) was 11, 87 IU/mL and average serum thyroglobulin (sTg) was 15, 15 ng/mL (Table 2). Analysis of the negative pathology and TTG concordant cases (n=28) showed an average TTG, Anti-Tg and sTg of 0, 19 ng/mL, 15,70 IU/mL and 0, 28 ng/mL respectively (Table 3). Evaluation of the 4 cases with unsatisfactory pathology had average TTG levels of 0, 7 ng/mL, Anti-Tg of 5, 1 IU/mL and sTg of 0, 07 ng/mL (Table 4).

Ultrasound findings were analysed in all the cases. Among the positive cases (Table 2), average lymph node size was 11, 13 mm and only 4 (30, 76%) had cystic change (CC). Features found in negative cases (Table 3) showed an average lymph node size of 11,35 mm and only one case (3,57%) had CC, this patient underwent surgical resection and the final surgical pathology specimen was negative for carcinoma (Table 3). Radiological findings for the unsatisfactory cases showed average lymph node size of 8,5 mm and no cases showed CC (Table 4).

The Kappa index was excellent ($k=0,846$) when comparing pathologic findings Vs TTG. However, 3 cases had TTG levels which were discordant with the pathologic diagnosis. Two of these cases had a positive pathologic category but a negative TTG. In one of them, the resection specimen confirmed a Thyroid Anaplastic Carcinoma, an entity that is a high-grade primary thyroid tumor that loses thyroglobulin expression (Table 5 and Figure 1 A and B). The second discordant case was a false negative cytology consisting of a lymph node FNA the showed only cystic changes, with no epithelial representation; however, due to the correlation made between the TTG level (43,3 ng/mL) and the ultrasound findings, the case was ultimately signed as positive (Table 5, Figure 1, C and D). The third case

corresponded to a soft tissue neoplasm located in the neck, which was positive for neoplasia but negative for TTG because it was not of thyroid origin (Table 5 and Figure 1, E and F).

Table 1: FNA/ biopsy correlation with tissue thyroglobulin(TTG)

	TTG		
	Positive*	Negative	Total
Cytology/ biopsy			
Positive PTC	13	2	15
Negative PTC	1	28	29
Unsatisfactory	0	4	4
Total	14	34	48

Note: * Suspicious for metastatic PTC ≥ 1.7 ng/mL inpatients with thyroidectomy or > 36 ng/mL in patients without thyroidectomyhistory

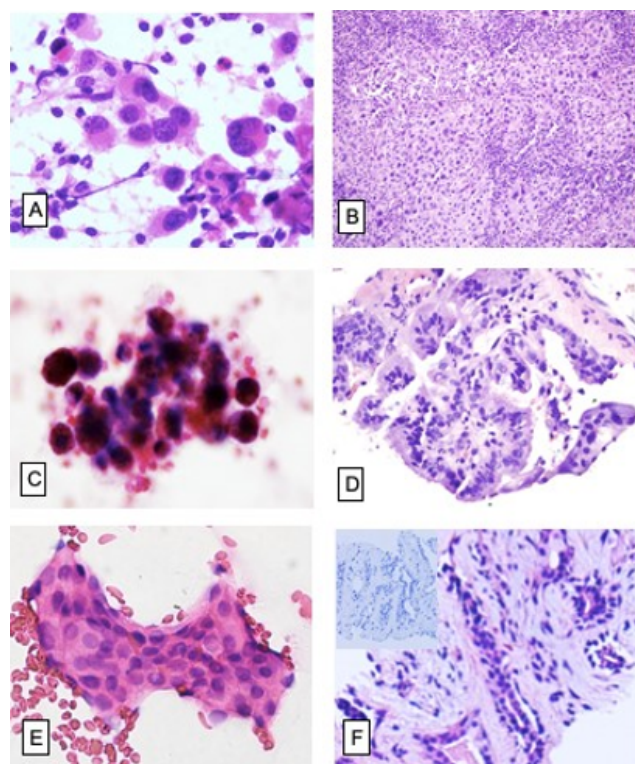


Fig. 1: (A) Patient with suspicious radiology, FNA was positive for poorly differentiated carcinoma with numerous highly atypical cells (H&E 400X) with negative TG levels. (B) Resection specimen confirmed an Anaplastic Thyroid Carcinoma (H&E 400X). Case 2. (C) False negative cytology: Patient with suspicious radiology, that underwent FNA showing haemorrhagic cystic changes without epithelial representation (H&E 1000X) and positive TTG levels. (D) Following resection specimen confirmed PTC (H&E 400X). Case 3. (E) Patient that had neck mass with suspicious radiology, FNA was positive for epithelial neoplasia (H&E 400x) and negative TTG. (F) Follow up biopsy showed a well differentiated epithelial neoplasia, TTF-1 was negative confirming Non-thyroid origin (H&E 400X).

Table 2: Concordant positive cases pathology and TTG

Case #	Demo graphics	Age	Gender	Thyroid ectomy	Clinical labs	Radiologic findings				Pathologic findings				Surgical resection follow-up
						Anti-Tg	sTg	Size (mm)	EH	miCa	CC	TTG	Category	
1	39	F	Yes	8,27	12,1	9	No	Yes	No	9400	Positive	Yes	No	PTC
2	39	F	Yes	8,27	12,1	8,2	Yes	No	Yes	1886,7	Positive	Yes	No	PTC
3	40	F	Yes	9,94	7,86	6	No	Yes	Yes	51,54	Positive	Yes	Yes	PTC
4	40	F	Yes	9,94	7,86	7,2	Yes	Yes	Yes	32,47	Positive	No	Yes	PTC
5	42	M	Yes	21	22	8,6	No	No	No	23350	Positive	No	Yes	PTC
6	44	F	Yes	20,21	0	14	No	No	No	37,48	Positive	Yes	No	PTC
7	47	F	Yes	NA	0,58	9,4	No	No	No	1,96	Positive	Yes	No	-
8	47	F	Yes	NA	0,58	8,5	Yes	Yes	No	8,4	Positive	Yes	No	-
9	49	F	Yes	NA	NA	19	Yes	Yes	No	655,24	Positive	No	No	-
10	49	F	Yes	NA	NA	12,7	Yes	Yes	No	4670	Positive	No	No	-
11	51	M	Yes	8,69	44,2	15	Yes	Yes	No	4,31	Positive	Yes	No	PTC
12	51	M	Yes	8,69	44,2	20	Yes	Yes	No	208,6	Positive	Yes	No	PTC
13	62	F	Yes	NA	NA	7,2	Yes	Yes	Yes	5313,2	Positive	No	Yes	PTC

Anti-Tg:Anti-thyroglobulin antibodies (IU/mL), sTg: Serum thyroglobulin (ng/mL), TTG:Tissue thyroglobulin (ng/mL), , EH : Heterogeneous echogenicity, miCa:Microcalcifications, CC: Cystic change

Table 3: Concordant negative cases pathology and TTG.

Case #	Demographics	Thyroidectomy	Clinical labs		Radiological findings			Pathological findings			Surgical resection follow-up				
			Anti-Tg	sTg	Size	EH	miC	CC	TTG	Category		Lymphocytes	CC	Epithelial cells	Desiccation artifact
1	13	F	No	.	12	Yes	No	No	0,1	Negative	Yes	No	No	++	-
2	19	F	Yes	76,42	0,08	Yes	Yes	No	0,3	Negative	-
3	25	F	Yes	.	6,1	No	No	No	0,2	Negative	No	No	No	++	-
4	32	F	Yes	7,21	0,12	No	No	No	0,13	Negative	Yes	No	No	++	-
5	32	F	Yes	7,21	0,12	No	No	No	0,13	Negative	Yes	No	No	++	-
6	37	F	No	.	31	Yes	Yes	No	0,1	Negative	Negative
7	37	F	No	.	25	Yes	Yes	Yes	0,1	Negative	Negative
8	42	F	Yes	5	0,1	8,6	No	No	0,1	Negative	Yes	No	No	++	-
9	45	F	Yes	.	8,3	No	No	No	0,3	Negative	Negative
10	46	F	Yes	.	14	Yes	Yes	No	0,1	Negative	Yes	No	No	++	-
11	46	F	Yes	.	6,4	Yes	Yes	No	0,2	Negative	Yes	No	No	++	-
12	46	F	Yes	6,49	1,93	14	No	No	0,2	Negative	Yes	No	No	++	-
13	46	F	No	-	8	No	No	No	0,1	Negative	Yes	No	No	++	-
14	48	F	Yes	.	9,5	Yes	Yes	No	0,2	Negative	Yes	No	No	++	-
15	54	F	Yes	27,02	0,19	6,8	No	Yes	0,1	Negative	Yes	No	No	++	-
16	55	F	Yes	.	12	No	No	No	0,1	Negative	Yes	No	No	++	-
17	55	F	Yes	5,07	0,11	10	No	No	0,1	Negative	Yes	No	No	++	-
18	55	F	No	.	19	No	No	No	0,1	Negative	-
19	58	F	Yes	12,67	0,01	16	No	Yes	0,3	Negative	Yes	No	No	++	-
20	58	F	Yes	.	14	Yes	Yes	No	1,57	Negative	Yes	No	No	++	-
21	59	F	Yes	.	8	Yes	Yes	No	0,1	Negative	No	No	No	++	-
22	59	F	Yes	.	8	Yes	Yes	No	0,1	Negative	No	No	No	++	-
23	59	F	Yes	5	0,1	9	No	Yes	0,1	Negative	Yes	No	No	++	-
24	59	F	Yes	5	0,1	5	No	Yes	0,1	Negative	Yes	No	No	++	-
25	59	F	No	.	5	No	No	No	0,1	Negative	Yes	No	No	++	-
26	63	F	Yes	.	10	No	No	No	0,1	Negative	Yes	No	No	++	-
27	64	M	Yes	.	24	No	No	No	0,1	Negative	Yes	No	No	++	Negative
28	65	F	Yes	.	12	No	Yes	No	0,1	Negative	Yes	No	No	++	-

Anti-Tg: Anti-thyroglobulin antibodies (IU/mL), sTg: Serum thyroglobulin (ng/mL), TTG: Tissue thyroglobulin (ng/mL), EH: Heterogeneous echogenicity, miCa: Microcalcifications, CC: Cystic change

Table 4: Unsatisfactory samples with negative TTG

Case #	Demographics		Thyroidectomy labs		Clinical				Radiological findings				Pathological findings				Surgical resection follow-up
	Age	Gender	Anti-Tg	sTg	Size	EH	miC	CC	TTG	Category	Lymphocytes	CC	Epithelial cells	Desiccation artifact			
1	34	F	Yes	5	0,04	8	No	No	No	0,1	Unsatisfactory	.	.	.	Negative		
2	45	F	Yes	.	.	12	No	No	No	0,1	Unsatisfactory	No	No	++	-		
3	45	F	Yes	.	.	5	No	No	No	0,3	Unsatisfactory	No	No	++	-		
4	60	F	Yes	5,21	0,11	8	No	No	No	0,2	Unsatisfactory	No	No	++	-		

Anti-Tg: Anti-thyroglobulin antibodies (IU/mL), sTg: Serum thyroglobulin (ng/mL), TTG: Tissue thyroglobulin (ng/mL), EH: Heterogeneous echogenicity, miCa: Microcalcifications, CC: Cystic change

Table 5: Discordant cases: Pathology Vs. TTG

Case #	Demographics		Thyroidectomy labs		Clinical				Radiological findings				Pathological findings				Surgical resection follow-up
	Age	Gender	Anti-Tg	sTg	Size	EH	miC	CC	TTG	Category	Lymphocytes	CC	Epithelial cells	Desiccation artifact			
1	49	F	No	-	-	26	No	No	No	0,1	Positive	No	Yes	+++	Anaplastic Thyroid Carcinoma		
2	78	F	No	-	-	38	Yes	No	Yes	43	Negative	No	No	++	PTC		
3	59	F	No	-	-	10	No	No	No	0,1	Positive	Yes	Yes	++	Soft tissue tumour, located in the neck		

TH: thyroidectomy history, ATG-AB: Anti-thyroglobulin antibodies (IU/mL), S-TG: Serum thyroglobulin (ng/mL), T-TG: Tissue thyroglobulin (ng/mL), Size: Lymph node size (mm), PTC: Papillary thyroid carcinoma, EH: Heterogeneous echogenicity, MiC: Microcalcifications, CC: Cystic change

4. Discussion

PTC can present loco-regional metastases in up to 20% of cases.³ The presence of metastases is considered as a poor prognosis factor and an indication for lymph node dissection.⁵ Tumor recurrence occurs commonly in the neck where ultrasonography is a sensitive method to identify small early recurrences, but it is not very specific.⁶ When pathology is analyzed including TTG measurement, specificity and sensitivity rise up to 100% in detecting malignancy.⁷ Considering that the study of PTC is based primarily on morphological and clinical basis, we hereby present evidence that shows that a combined analysis of cytology/biopsy together with TTG levels can enhance the diagnostic performance of our institution when applied as a complement to the current methodology. Although the number of samples is limited, pathology and TTG concordance for the diagnosis of metastatic PTC was excellent (K=0, 846).

Pathologist as well as physicians must be aware of some considerations. According to the literature false positive TTG are commonly described in lymph nodes with central location,⁸ where it is difficult to distinguish compromised nodes from residual thyroid tissue after total or partial thyroidectomy.⁹ In our series we did not find cases located in the central compartment. Also, cystic metastatic PTC is common, and in these cases, it can be challenging to obtain adequate cytologic material because the follicular epithelium can often be insufficient. In our cases, 3 out of 13 positive cases had CC confirmed by surgical resection, none of the 28 negative pathology cases had CC and only 1 of the unsatisfactory cases had CC, which was ultimately confirmed as positive for metastatic carcinoma with the aid of a positive TTG result. Reviewing the literature, false positive TTG cases have been reported in patients with anti-Tg or high sTg levels. In our study, levels of anti-Tg and sTg did not show interference with concordance in neither positive, negative or unsatisfactory cases.⁶

TTG is useful to reduce false negative cytology results, however, it is important to be aware that in the case a false positive cytology with negative TTG levels, there must be clinical correlation. This is shown by one of our cases which resulted in an anaplastic thyroid carcinoma diagnosis. This tumor usually loses TTG expression and can give us a false negative TTG, therefore, clinical correlation between images, sTg and a reviewing of the corresponding cytology can aid differential diagnosis.¹⁰

Negative levels of TTG in patients with no history of PTC or malignancy different from well differentiated thyroid carcinoma can reassure the clinician and the patient. In our series we found two cases with negative node cytology (jugular and supraclavicular) and TTG levels. These two cases revealed granulomas, one of them showing necrosis with positive ZN staining. One relevant limitation of this study is that the patients with a negative diagnosis

for nodal compromise did not have indication for a follow up resection, therefore we could not compare these results to a resection piece.

In conclusion, TTG measurement through chemiluminescence is a low-cost technique that can improve diagnostic performance of pathological analysis. Levels can be measured from the same needle used in cytology/biopsy providing both the patient and clinician greater diagnostic certainty, increasing the diagnostic sensitivity and specificity of the procedure without the need for further invasive interventions. Among methodological considerations, in order to quantify a correct TTG level in tissue, it is essential to corroborate the validation of the TTG measurement in the laboratory so one can ensure certainty, precision and reproducibility of the study. We recommend that cytology or biopsy is performed simultaneously to TTG, ensuring that the washout is done immediately after the smears and the FNA so levels can be correlated with pathologic findings.

5. Source of Funding

No financial support was received for the work within this manuscript.

6. Conflict of Interest

The authors declare they have no conflict of interest.

References

1. Rocha RM, Santos M, Musso C, de S Santos M, De-Almeida ML, Miguel GPS, et al. Well-differentiated thyroid carcinoma: epidemiological profile, surgical results and oncological response. *Rev Col Bras Cir.* 2018;45(5):e1934.
2. Andrioli M, Valcavi R. Sonography of Normal and Abnormal Thyroid and Parathyroid Glands. *Front Horm Res.* 2016;45(1):1–15.
3. Perri F, Giordano A, Pisconti S, Ionna F, Chiofalo MG, Longo F, et al. Thyroid cancer management: From a suspicious nodule to targeted therapy. *Anticancer Drugs.* 2018;29(6):483–90.
4. Trimboli P, D'Aurizio F, Tozzoli R, Giovannella L. Measurement of thyroglobulin, calcitonin, and PTH in FNA washout fluids. *Clin Chem Lab Med (CCLM).* 2017;55(7):914–25. doi:10.1515/cclm-2016-0543.
5. Miller JE, Al-Attar NC, Brown OH, Shaughnessy GG, Rosculet NP, Avram AM, et al. Location and Causation of Residual Lymph Node Metastasis After Surgical Treatment of Regionally Advanced Differentiated Thyroid Cancer. *Thyroid.* 2018;28:593–600. doi:10.1089/thy.2017.0434.
6. Baldini E, Sorrenti S, Gioia CD, Vito CD, Antonelli A, Gnessi L, et al. Cervical lymph node metastases from thyroid cancer: does thyroglobulin and calcitonin measurement in fine needle aspirates improve the diagnostic value of cytology? *BMC Clin Pathol.* 2013;13(1). doi:10.1186/1472-6890-13-7.
7. Trimboli P, D'Aurizio F, Tozzoli R, Giovannella L. Measurement of thyroglobulin, calcitonin, and PTH in FNA washout fluids. *Clin Chem Lab Med (CCLM).* 2017;55(7):914–25. doi:10.1515/cclm-2016-0543.
8. Zhang X, Howell JM, Huang Y. Cervical Lymph Node Fine-Needle Aspiration and Needle-Wash Thyroglobulin Reflex Test for Papillary Thyroid Carcinoma. *Endocr Pathol.* 2018;29(4):346–50. doi:10.1007/s12022-018-9547-2.
9. Li QK, Nugent SL, Straseski J, Cooper D, Riedel S, Askin FB, et al. Thyroglobulin measurements in fine-needle aspiration cytology of lymph nodes for the detection of metastatic papillary

- thyroid carcinoma. *Cancer Cytopathol.* 2013;121(8):440–8. doi:10.1002/cncy.21285.
10. Li J, Zhang K, Liu X, Hao F, Liu Z, Wang Z, et al. Cervical lymph node thyroglobulin measurement in washout of fine-needle aspirates for diagnosis of papillary thyroid cancer metastases. *Br J Biomed Sci.* 2016;73(2):79–83.

Cite this article: Barrera-Herrera LE, Barrera-Penagos V, Palau-Lázaro MA, Rivera-Gonzalez H, González-Devia D, Hakim-Tawil JA, Romero-Enciso JA, Rodríguez-Urrego PA. Lymph node tissue thyroglobulin washout measurement in metastatic papillary thyroid carcinoma . *IP Arch Cytol Histopathology Res* 2020;5(4):295-301.