



## Case Report

# Angiolymphoid hyperplasia with eosinophilia – A case report

Priyadharsini J<sup>1</sup>, Partho Protim Barman<sup>1</sup>, Priyatharsini Pari<sup>1,\*</sup>

<sup>1</sup>Dept. of Pathology, Sri Lakshmi Narayana Institute of Medical Sciences, Puducherry, India



### ARTICLE INFO

#### Article history:

Received 06-11-2020

Accepted 30-11-2020

Available online 30-12-2020

#### Keywords:

Angiolymphoid hyperplasia with

eosinophilia

Nodule

Vascular neoplasm

### ABSTRACT

**Background:** Angiolymphoid hyperplasia with eosinophilia, a benign vascular tumor is a rare entity. It is characterized by abnormal proliferation of blood vessels with mixed inflammatory infiltrate in the background.

**Case:** We present a case report of Angiolymphoid hyperplasia with eosinophilia in a women of age 47 years. She presented with multiple nodules in the temporal region of scalp. Her IgE levels were normal. Chest X-ray and Skull X-ray was unmarkable and histologically proven to be angiolymphoid hyperplasia with eosinophilia.

**Result:** Multiple nodular lesion in the scalp was diagnosed as Angiolymphoid hyperplasia with eosinophilia.

**Conclusion:** Angiolymphoid hyperplasia with eosinophilia, though a rare entity should be kept in mind for early intervention.

© This is an open access article distributed under the terms of the Creative Commons Attribution License (<https://creativecommons.org/licenses/by/4.0/>) which permits unrestricted use, distribution, and reproduction in any medium, provided the original author and source are credited.

## 1. Introduction

Angiolymphoid hyperplasia with eosinophilia represent the benign end of the spectrum of vascular tumors. This entity is known by various names which includes Epithelioid hemangioma, Inflammatory angiomatous nodule, Papular angioplasia and intravenous atypical vascular proliferation.<sup>1</sup> In 1969, Wells & Whimster first described this rare vascular tumor.<sup>2</sup> The etiology of epithelioid hemangioma remains controversial, whether it is a true neoplasm or reaction to trauma, however former is mostly favoured.<sup>3</sup> It present as a single or multiple nodules in head and neck areas especially around the ear with predilection for middle aged women.<sup>4</sup>

## 2. Case Report

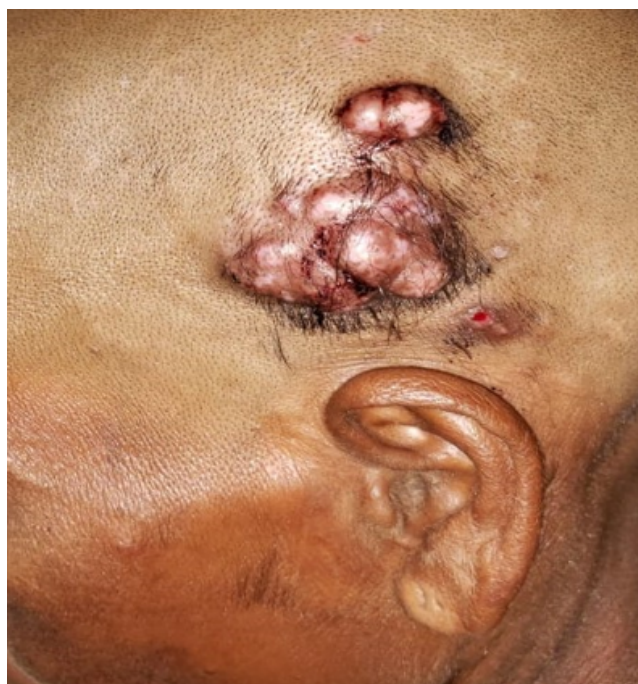A 47 year old female patient presented with multiple nodular swelling in the temporal region of the scalp. She complained of itching and occasional bleeding. She had a positive history of trauma 2 months ago and the swelling

slowly progressed in size during this time course. Chest X-Ray and Skull X-Ray was normal. Serum IgE levels were normal. Peripheral blood smear examination revealed eosinophilia with absolute eosinophil count of 750 cells per microliter.

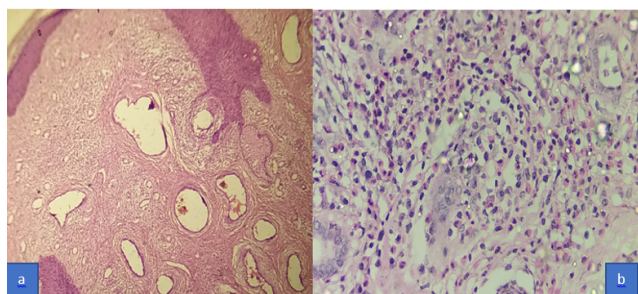
Dermatological examination revealed multiple erythematous nodular lesion with focal ulceration. These nodules range in size from 5cm in greatest dimension to 1 cm in greatest dimension located in left sided temporal region. A biopsy was carried out in one of the lesions and histopathological findings showed proliferation of small sized blood vessels lined by plump endothelial cells with occasional hobnailing in the background of dense inflammatory infiltrate composed of eosinophils, lymphocytes and neutrophils. Surgical excision of the lesion was recommended and patient refused surgery. Follow up of the case revealed a slight increase in size of the lesion.

\* Corresponding author.

E-mail address: [dr.priadharsini@gmail.com](mailto:dr.priadharsini@gmail.com) (P. Pari).



**Fig. 1:** Multiple nodular lesions in the temporal region of left sided scalp.



**Fig. 2:** Microphotograph showing skin with underlying dermis exhibiting abnormal proliferation of blood vessels (a, hematoxylin and eosin, 10 X). Microphotograph showing vessel lumen lined by plump endothelial cells with dense infiltration of eosinophils and lymphocytes.

### 3. Discussion

Angiolymphoid hyperplasia with eosinophilia (ALHE) is a rare slow growing tumor with unknown etiopathogenesis. It present as single or multiple red nodules ranging in size from 2 – 3 cm. It is most common in middle aged adults with predilection to females. ALHE most commonly occur in head and neck region especially in proximity to ears, however it can also occur at other sites like trunk and limbs, oral mucosa, tongue, breast, lymph node, bone and testis.<sup>5,6</sup>

Its pathogenesis is unknown, however the possible contributing factors are arteriovenous shunting, local trauma and elevated serum estrogen levels. The inflammatory cells are thought to play an important role in the proliferation of endothelial cells. Thus the theories of origin of this tumor

is controversial and the leading members are a reactive process, infectious etiology, immunologic or neoplastic process.<sup>5,7</sup>

The differential diagnosis of concern is kimura's disease and is most common in Asian men. Here the patient present with lymphadenopathy, peripheral eosinophilia, increased serum IgE levels and immunologically mediated systemic involvement like membranous nephropathy. Histologically it presents in the deeper part with numerous lymphoid follicle formation, dense fibrosis and eosinophil microabscess. In contrast the ALHE shows numerous abnormal vascular proliferation with dense lymphocyte aggregates and eosinophils. These capillaries are lined by plump endothelial cells with hobnailing, with occasional cytoplasmic vacuoles.<sup>8</sup>

Other differential diagnosis considered are Injection site granuloma, bacillary angiomatosis, epithelioid hemangioendothelioma, cylindroma and angiosarcoma.<sup>9</sup>

The treatment of choice is surgical excision, however the other modalities that can be considered like cryotherapy, photodynamic therapy and application of imiquimod, which are providing promising results.<sup>10,11</sup>

### 4. Conclusion

Angiolymphoid hyperplasia with eosinophilia though a rare entity should be considered when abnormal proliferation of blood vessels are seen. Though it is a benign lesion it does not regress without intervention, so prompt diagnosis is essential for further intervention.

### 5. Authors' Contributions

Dr.P.P, collected the data, collected the reference, and typed the article. Dr.P.J provided gross and histopathological opinion and collected and compiled the data.Dr.P.P.B edited the article.

### 6. Acknowledgments

We thank the Faculty of Department of Pathology,Sri Lakshmi Narayana institute of medical sciences, Puducherry, for their support.

### 7. Source of Funding

No financial support was received for the work within this manuscript.

### 8. Conflict of Interest

The authors declare they have no conflict of interest.

### References

1. Park Y, Chung J, Chang-Gun C. Angiolymphoid hyperplasia with eosinophilia of the tongue: report of a case and review of the literature.

- Oral Oncol.* 2002;38(1):103–6. doi:10.1016/s1368-8375(01)00020-3.
2. Wells GC, Whimster IW. Subcutaneous angiolymphoid hyperplasia with eosinophilia. *Br J Dermatol* . 1969;81(1):1–5. doi:10.1111/j.1365-2133.1969.tb15914.x.
  3. Sampaio S, Rivitti EA. Hiperplasia angiolinfóide com eosinofilia. *Artes Médicas.* 2008;p. 1221–2.
  4. Quattrocchi CM, Jankovic R, Jacquier M, Sánchez A, Bergero A, Bussy R, et al. Hiperplasia angiolinfóide con eosinofilia: reporte de un caso. *Arch Argent Dermatol.* 2012;62:189–92.
  5. Nogueira A, Filho JWA, de Castro MCR, Maceira JP, e Silva MR. Hiperplasia angiolinfóide com eosinofilia: relato de dois casos. *Anais Bras de Dermatol.* 2003;78(1):79–85. doi:10.1590/s0365-05962003000100008.
  6. Tsuboi H, Fujimura T, Katsuoka K. Angiolymphoid hyperplasia with eosinophilia in the oral mucosa. *Br J Dermatol.* 2001;145(2):365–6. doi:10.1046/j.1365-2133.2001.04364.x.
  7. Zaraq I, Mlika M, Chouk S, Chelly I, Mokni M, Zitouna M, et al. Angiolymphoid hyperplasia with eosinophilia: a study of 7 cases. *Dermatol Online J.* 2011;17(1).
  8. de Bastos JT, da Rocha CRM, Silva PMC, de Freitas BMP, de Freire Cassia F, Avelleira JCR, et al. Angiolymphoid hyperplasia with eosinophilia versus Kimura's disease: a case report and a clinical and histopathological comparison. *Anais Bras de Dermatol.* 2017;92(3):392–4. doi:10.1590/abd1806-4841.20175318.
  9. Weiss SW, Goldblum J. Soft tissue tumors. In: 4th Edn. Mosby, Philadelphia; 2001. p. 593.
  10. Sotiriou E, Apalla Z, Patsatsi A, Panagiotidou DD, Ioannides D. Angiolymphoid hyperplasia with eosinophilia: good response to photodynamic therapy. *Clin Exp Dermatol.* 2009;34(8):e629–31. doi:10.1111/j.1365-2230.2009.03348.x.
  11. Youssef A, Hasan AR, Youssef Y, Al-soufi L, Elshimali Y, Alshehbi Z, et al. Angiolymphoid hyperplasia with eosinophilia: a case report. *J Med Case Rep.* 2018;12(1). doi:10.1186/s13256-018-1599-x.

### Author biography

**Priyadharsini J**, Assistant Professor

**Partho Protim Barman**, Professor

**Priyadharsini Pari**, Assistant Professor

**Cite this article:** Priyadharsini J, Barman PP, Pari P. Angiolymphoid hyperplasia with eosinophilia – A case report. *IP Arch Cytol Histopathology Res* 2020;5(4):317-319.