



Original Research Article

Spectrum of pap smear cytology in women presenting in a tertiary care center in north India-a two year study

Honey Bhasker Sharma¹, Megha Bansal^{1,*}, Nikhilesh Kumar¹, Monika Gupta¹¹Dept. of Pathology, TSM Medical College, Lucknow, Uttar Pradesh, India

ARTICLE INFO

Article history:

Received 25-01-2021

Accepted 23-02-2021

Available online 03-04-2021

Keywords:

PAP smear

Malignant

Premalignant

Bethesda system

ABSTRACT

Context: Cervical cancer is the second most common cancer in the world after breast cancer and is the most common gynecological cancer in the developing countries. Pap Smear is a simple and cost effective screening tests for early diagnosis of premalignant and malignant cervical lesions.

Aim: The aim of this study is to evaluate the spectrum of cervical pap smear cytology in a tertiary hospital. The reporting of the pap smear was based on 2014 Bethesda system

Materials and Methods: This is a retrospective two year study done in a tertiary Hospital in TSM Hospital from June 2016 to June 2018. All Pap smears received from women were included in our study. Total of 450 pap smears were stained by conventional papanicolaou technique and reported by Bethesda system 2014.

Results: Out of 450 cases, 411 cases (91.3%) were reported as negative for intraepithelial lesion/malignancy, 31 cases (6.9%) were showing epithelial cell abnormality and 8 cases (1.7%) were unsatisfactory. In negative for intraepithelial lesion cases, 4 cases (0.9%) were atrophic smears, 357 cases (79.3%) were inflammatory and the remaining 50 cases (11.1%) were showing no other changes. In inflammatory cases 53 cases(11.7%) showed presence of microorganisms. 31 cases showing an intraepithelial lesion - 15 cases(3.3%) were ASCUS, 3 cases (0.6%) were AGUS, 6 cases (1.2%) were LSIL, 4 cases(0.8%) of ASC-H, 2 cases(0.4%) were HSIL and one case(0.2%) of squamous cell carcinoma cervix.

Conclusion: Premalignant and malignant lesions of cervix are common and can be diagnosed early by conventional PAP smears.

Key message: Conventional pap smears are essential not only to diagnose premalignant lesions but also to identify the infectious etiologies and guide proper treatment.

© This is an open access article distributed under the terms of the Creative Commons Attribution License (<https://creativecommons.org/licenses/by/4.0/>) which permits unrestricted use, distribution, and reproduction in any medium, provided the original author and source are credited.

1. Introduction

Cervical cancer is an increasing health problem and an important cause of mortality in women worldwide. The incidence of cervical cancer arises worldwide. The difference in incidence between developing and developed countries is large. In developing countries like India, the burden of cervical cancer is still high. According to the world cancer statistics, >80% of all cancer cases are found in developing and low resource countries, because of a

lack of awareness and difficulty in running cytology based screening programmes.¹

More than one fifth of all cervical cancer deaths occur in India.² If diagnosed and treated early morbidity may be reduced by 70% and mortality by 80%. The papanicolaou test also known as Pap test, Pap smears, cervical smear or smear test is a screening method used to detect potentially precancerous and cancerous processes in the cervix. Greek doctor Georgios Papanikolaou invented this test and it was named after him.³

Pap smear is pivotal in cervical cancer screening in developing countries. It also identifies various

* Corresponding author.

E-mail address: drmeghabansal1981@gmail.com (M. Bansal).

inflammatory, infective, benign and malignant pathologies at the earliest.⁴

It is a simple, safe and effective test to detect premalignant and malignant lesions of the cervix at an early age.⁵ It is recommended that females who are having sexual exposure should undergo regular Pap smear testing.⁶ It should be a continuous process in order to prevent people dropping out for follow up visits and treatment procedure.⁷

Pap smear testing is strongly recommended in women in INDIA for early detection and treatment of premalignant, malignant and inflammatory conditions.⁸

First Bethesda system of cervical smear reporting was developed in 1988 and a two tier system i.e low grade squamous intraepithelial lesions (LSIL) and high grade squamous intraepithelial lesion (HSIL) was introduced and also used adequacy criteria alongwith human papilloma virus related preinvasive changes in the cervical epithelium.⁹

Our study aims to present the pap smear results based on Bethesda system2014 by evaluating the benign, infective and precancerous lesions in women presenting to our tertiary care center.

1.1. Subjects and Methods

This study was conducted at a tertiary care institute of Lucknow over a period of two years from June 2016 to June 2018 and a total Of 450 patients were included, who reported to TSM Hospital Lucknow with chief complaints of vaginal discharge , menstrual irregularities, pelvic pain and dyspareunia.

Pregnant patients, patients who were been treated before for frank carcinoma cervix and patients who were bleeding at the time of examination were excluded from the study.

Cervical smears were taken using conventional method of cervical cytology by using pap kit (endocervical brush, Ayres spatula and cotton swab). Smears were fixed immediately in 95% ethylalcohol and stained by Pap staining. Smears were reported as per the Bethesda system 2014.

2. Results

Out of 450 cases, 411 cases (91.3%) were reported as negative for intraepithelial lesion/malignancy, 31 cases (6.9%) were showing epithelial cell abnormality and 8 cases (1.7%) were unsatisfactory. In negative for intraepithelial lesion cases, 4 cases (0.9%) were atrophic smears, 357 cases (79.3%) were inflammatory and the remaining 50 cases (11.1%) were showing no other changes. In inflammatory cases 53 cases (11.7%) showed presence of microorganisms. 31 cases showing an intraepithelial lesion - 15 cases(3.3%) were ASCUS, 3 cases (0.6%) were AGUS, 6 cases (1.2%) were LSI , 4 cases (0.8%) of ASC-H,2 cases(0.4%) were HSIL and one case (0.2%) of squamous

cell carcinoma cervix as shown in Table 1.

Table 1: Spectrum of Cytodiagnosis on Pap smear reporting by Bethesda system 2014 in TSM College

Pap Smear Diagnosis	Number of patients	Percentage of patients%
1.Unsatisfactory	08	1.7
2.NILM	411	91.3
A.Inflammatory	357	79.3
a.Nonspecific	308	67.5
b.Trichomonas vaginalis	03	0.67
c.Candida	16	3.5
d.Bacterial vaginosis	34	7.5
B.Atrophy	04	0.9
C. No other changes	50	11.1
3.Epithelial cell abnormality	31	6.9
a.ASCUS	15	3.30
b.AGUS	03	0.6
c.LSIL	06	1.3
d.HSIL	02	0.4
e.ASC-H	04	0.8
f.SCC	01	0.2

Most common age group showing epithelial cell abnormality was 41-60 yrs of age. The examination of 31 abnormal smears reveal 15 cases (3.3%) of ASCUS with maximum number in age group 51-60 years, AGUS- 3 cases maximum in the ages 31-40 yrs, LSIL -6 cases maximum in the age range 41-50 yrs. HSIL -2 cases maximum in age range 41-50 yrs. Squamous cell carcinoma cervix only one case of age 70 years as shown in table 2. In our study mean age of ASCUS & LSIL was 51 years, 59 yrs for ASC-H, 50 yrs for HSIL & 70 yrs for ca cervix.

Microscopy of inflammatory smears reveal bacterial vaginosis, Trichomonas, Candidiasis, and other non specific infections as shown below in Table 3.

Figure 1 shows candidial hyphae and spores.Figure 2 shows bacterial vaginosis with clue cells. Figure 3 shows ASCUS, Figure 4 shows LSIL.Figures 5 and 6 shows squamous cell carcinoma cervix.

3. Discussion

In a study done by Singh K and Singh A in 2015 they revealed negative for intraepithelial lesions in 156 cases (83.9%) cases and epithelial cell abnormality in 30(16%) cases.¹⁰ In our study we found negative for intraepithelial lesions in 411 cases (91.3%) and epithelial cell abnormalities in 31cases (6.8%).

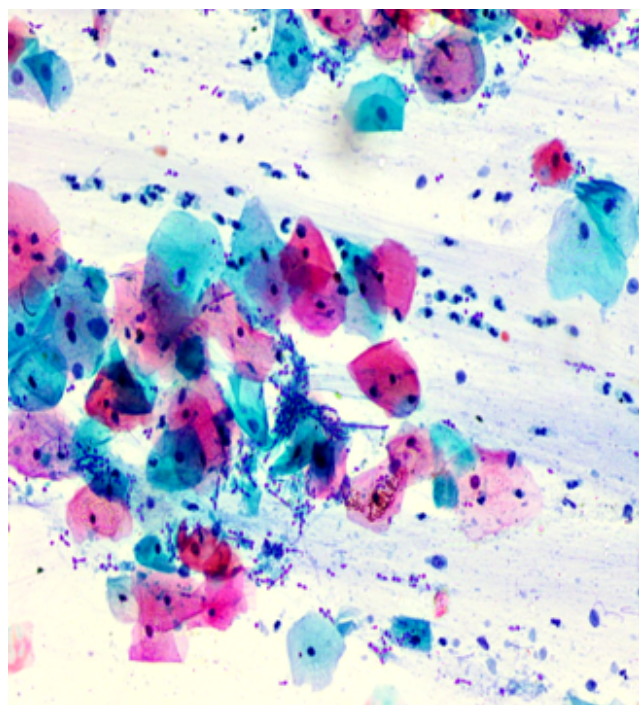
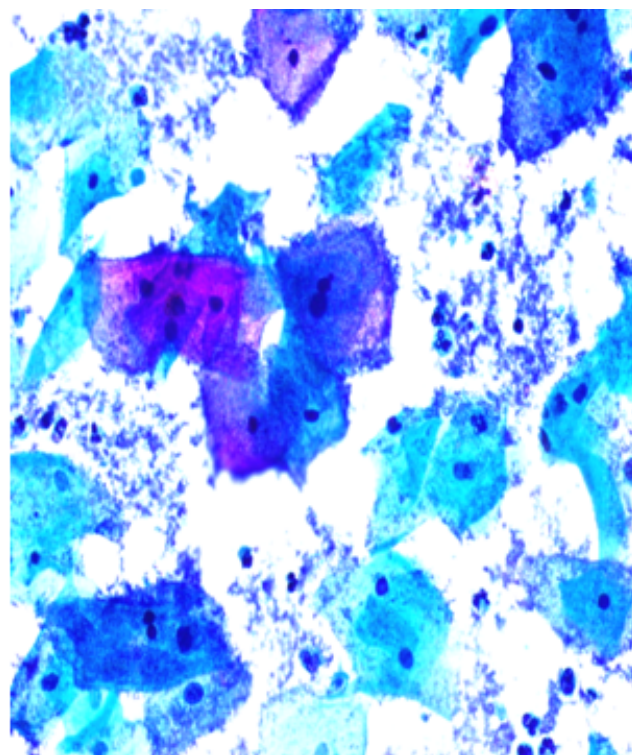
In a study done by Sachan P, Singh M, Patel M, Sachan R in 2018 they found ASCUS in 2.9% of screened women, LSIL in 5.09%, and HSIL in 0.48% cases.¹¹ In their study Lakshmi P et al found ASCUS in 5 cases (2.5%), LSIL in 15 cases(7.5%), and HSIL in 1 case(6%) cases¹²In our study we found ASCUS in 15cases (3.3%), LSIL in 6 cases(1.3%),

Table 2: Agewise distribution of epithelial cell abnormality in Pap smear reporting

Epithelial Cell Abnormality	Age <20yrs	Age 21-30yrs	Age 31-40yrs	Age 41-50yrs	Age 51-60yrs	Age 61-70yrs	Total
ASCUS	-	-	01	05	08	01	15(48.4%)
AGUS	-	-	02	01	-	-	03(9.6%)
ASC-H	-	-	-	-	03	01	04(13%)
LSIL	-	01	01	03	-	01	06(19.3%)
HSIL	-	-	-	02	-	-	02(6.4%)
SCC	-	-	-	-	-	01	01(3.3%)

Table 3: Agewise distribution of Inflammatory smear on Pap smear reporting:

Inflammatory smear	Age <20yrs	Age 21-30yrs	Age 31-40yrs	Age 41-50yrs	Age 51-60yrs	Age 61-70yrs	Total
Non specific inflammation	05	113	110	60	10	06	304(85.3%)
Bacterial vaginosis	02	12	13	07	-	-	34(9.4%)
Trichomonas vaginalis	01	01	01	-	-	-	03(0.83%)
Candida	-	03	07	05	01	-	16(4.43%)

**Fig. 1:** Candidial hyphae and spores**Fig. 2:** Bacterial vaginosis (clue cells)

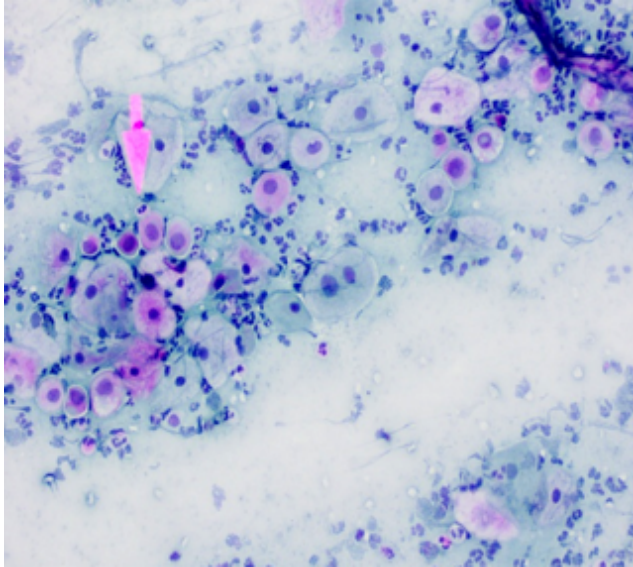
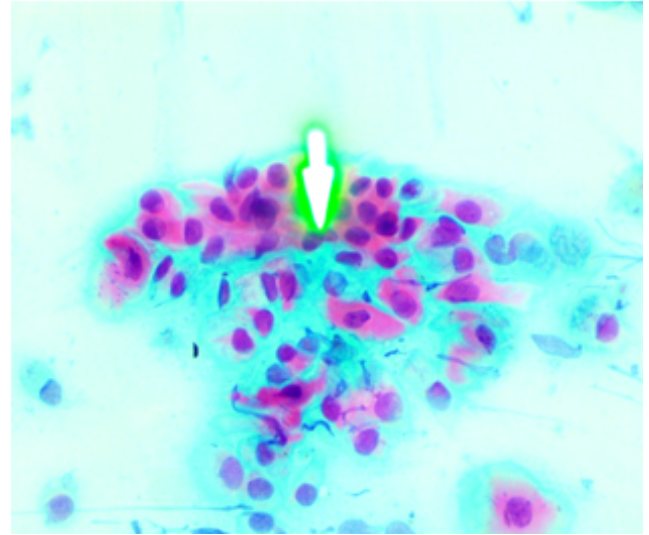
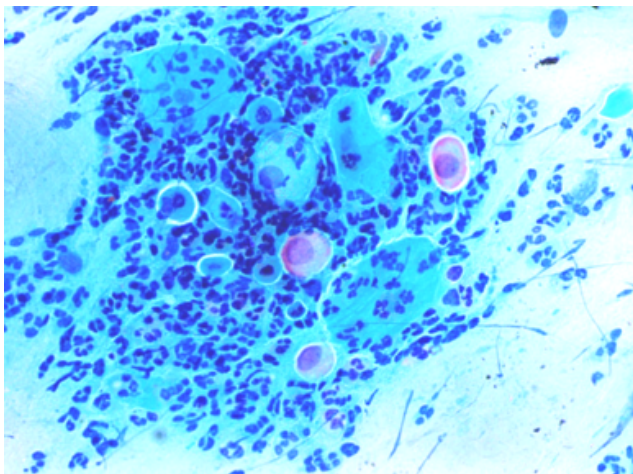
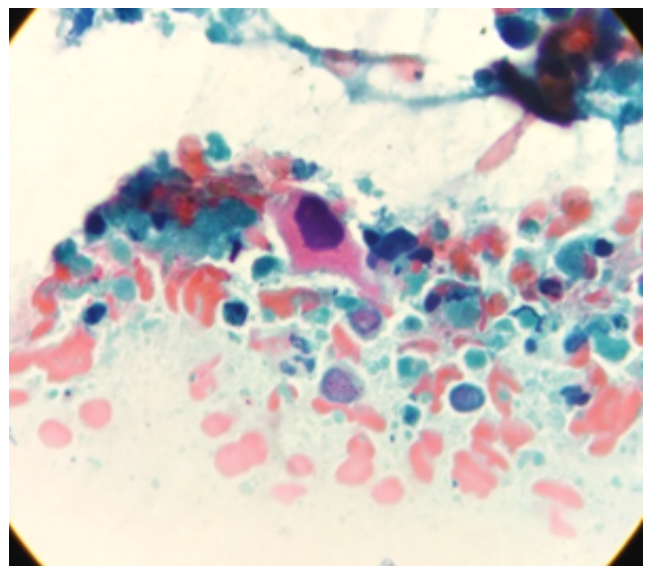
HSIL in 2 cases (0.4%) and AGUS in 3cases (0.6%), ASC-H in 4 cases (0.8%) and SCC cervix in 1 case (0.2%) as shown in Table 4.

In a study done by Warpe B M et al in 2016 , nonspecific inflammation was found in 61.2%, candida infection in 0.8%, Trichomonas infection 7.35% , bacterial vaginosis in 12.24%.¹³ Similar results were obtained in their study by Kalyani R et al in 2016.¹⁴ Study done by Sethi PK et al in 2014 showed similar results.¹⁵ Pudasaini S, et al in 2015 found Bacterial vaginosis (5.3%) was commonest among organisms in their study which was similar to our study.¹⁶

In the study done by Rawat Kiran et al in 2016 mean age of patients with LSIL was 39.1years and those of ASC-H, HSIL & Carcinoma cervix were 54, 51.1 and 64.6 years respectively.¹⁷ While in our study mean age of LSIL was 51 years, 59yrs for ASC-H, 50yrs for HSIL & 70yrs for carcinoma cervix.

Table 4: Comparison of distribution of epithelial cell abnormality in different studies in pap smear study:

Epithelial Abnormality	Sachan P et al(2018) ¹¹	Lakshmi P et al ¹²	Present study
ASCUS	2.9%	2.5%	3.3%
LSIL	5.09%	7.5%	1.3%
HSIL	0.48%	6%	0.4%

**Fig. 3:** ASCUS**Fig. 5:** HSIL**Fig. 4:** LSIL**Fig. 6:** Squamous cell carcinoma CERVIX

4. Conclusion

Premalignant and malignant lesions of cervix are common and can be diagnosed early by conventional PAP smears. Conventional pap smears are essential not only to diagnose premalignant lesions but also to identify the infectious etiologies and guide proper treatment. Cervical cancer commonly occurs in women between ages 60 and 70 years and its precursor lesion occurs 10-20 years earlier. Therefore

it is recommended that women should have atleast one pap smear test before the age of 45 years. Thus, we have to strengthen our health services to spread cervical cancer screening programs, educate and motivate women to visit the hospital for cancer screening.

5. Conflicts of Interest

All contributing authors declare no conflicts of interest.

6. Source of Funding

None.

References

1. Ferlay J, Soerjomataram I, Dikshit R, Eser S, Mathers C, Rebelo M, et al. Cancer incidence and mortality worldwide: Sources, methods and major patterns in GLOBOCAN 2012. *Int J Cancer*. 2015;136(5):E359–E386. doi:10.1002/ijc.29210.
2. Bruni L, Barrionuevo-Rosas L, Albero G, Aldea M, Serrano B, Valencia S, et al. ICO Information Center on HPV and Cancer (HPV Information Centre) Human Papillomavirus and Related Diseases Reports. Last accessed on; 2015.
3. Smear P. By Healthline medical review team. Available from: www.healthline.com/health/papsmearoverview/2015/11.
4. Ghimire PG, Rawat DBC, Sinha K, Jahan K, Shrestha R. Spectrum of cytological patterns in cervical PAP smears in a tertiary care center of Western region of Nepal. *Nepal J Med Sciences*. 2019;4(1):2–8. doi:10.3126/njms.v4i1.24118.
5. Mudassir G, Abid M, Naveed H. The Taliban Conundrum. *J Rawalpindi Med Coll*. 2017;22(01):21–26. doi:10.9790/0837-2201022126.
6. Padmom L, Devi B, Sapru K. Cervical smears-study done in a tertiary care hospital. *J Evol Med Dent Sci*. 2019;8(12):859–62. doi:10.14260/jemds/2019/191.
7. Rose SAA. Pattern of Pap smear cytology: our experience. *International journal of reproduction, contraception, Obstet Gynecol*. 2016;5(10):3290–3.
8. Biradar SS, Rashmi S. An Analysis of Various Cytopathological Patterns on Papanicolaou smears-Cervical Cytology: A Study in Tertiary Care Hospital. *Int J Clin Diagn Pathol*. 2020;3(1):385–99. doi:10.33545/pathol.2020.v3.i1f.202.
9. Nayar R, Wilbur D. The Bethesda System for Reporting Cervical Cytology: Definitions, Criteria, and Explanatory Notes. In: 3rd Edn. New York: Springer; 2015.
10. Singh K, Singh A. A Clinicopathological correlation of pap smear findings in gynecological cases: A retrospective study. *Int J Sci Res*. 2015;4(7):1645–7.
11. Sachan R, Sachan PL, Singh M, Patel ML. A Study on Cervical Cancer Screening Using Pap Smear Test and Clinical Correlation. *Asia-Pacific J Oncol Nurs*. 2018;5(3):337–41. doi:10.4103/apjon.apjon_15_18.
12. Lakshmi P, Gouri S. Study and Analysis of Two Hundred Cervical Pap smears in our Hospital. *Int J Contemp Med Res*. 2016;3(9):2787–90.
13. Warpe B, Warpe S, Sawant S. An institutional based Cervical PAP smear study, correlation with clinical findings and histology in the Konkarn region of Maharashtra state, India. *Walawalkar Int Med J*. 2016;3(1):37–51.
14. Kalyani R, Sharief N, Shariff S. A study of PAP smear in Tertiary Hospital in South India. *J Cancer Biol*. 2016;4(3):1084–90.
15. Sethi PK, Singh A, Kaur H, Sood N. Trends in cervical cytology of conventional Papanicolaou smears according to revised Bethesda system: A study of 638 cases. *IJRRMS*. 2014;4:1–25.
16. Pudasaini S, Prasad KBR, Rauniyar SK, Pathak R, Pande K, Koirala S, et al. Cervical pap smear- A prospective study in a tertiary hospital. *J Pathol Nepal*. 2015;5(10):820–3. doi:10.3126/jpn.v5i10.15639.
17. Rawat K, Rawat N, Mathur N, Mathur M, Chauhan N, Tinna R, et al. A study of cytological pattern of cervical papanicolaou smears in western Rajasthan, India. *International Journal of Reproduction, Contraception, Obstetrics and Gynecology*. 2016;5(9):3186–3190. Available from: <https://dx.doi.org/10.18203/2320-1770.ijrcog20163009>. doi:10.18203/2320-1770.ijrcog20163009.

Author biography

Honey Bhasker Sharma, Associate Professor

Megha Bansal, Associate Professor

Nikhilesh Kumar, Professor and Head

Monika Gupta, Professor

Cite this article: Sharma HB, Bansal M, Kumar N, Gupta M. Spectrum of pap smear cytology in women presenting in a tertiary care center in north India-a two year study. *IP Arch Cytol Histopathology Res* 2021;6(1):7-11.