



Case Report

Invasive mucormycosis in post COVID-19 infection: Case report with review

Sunil V Jagtap^{1,*}, Swati S Jagtap², Vaidehi Nagar¹, Kaushiki Varshney¹

¹Dept. of Pathology, Krishna Institute of Medical Sciences, Deemed University, Karad, Maharashtra, India

²Dept. of Physiology, Krishna Institute of Medical Sciences, Deemed University, Karad, Maharashtra, India



ARTICLE INFO

Article history:

Received 23-05-2021

Accepted 27-05-2021

Available online 29-05-2021

Keywords:

COVID19

Mucormycosis

SARSCoV2

maxillary fungal infection

ABSTRACT

COVID-19 is an infection caused by severe acute respiratory syndrome coronavirus-2 (SARS-CoV-2). Now there are increased cases with super infections by mucormycosis, which were rarely reported in the beginning of the current pandemic of COVID 19. Herewith a case of 47 year-old male patient of post COVID-19 infection having severe hypoxia and was on ventilator, received steroid treatment and also known case of HIV/AIDS. Now admitted to our hospital having fever, facial pain, and swelling mid-face region. His RT-PCR test was positive. On clinical, radio imaging and on histopathological findings diagnosed as maxillary mucormycosis. We are presenting this rare case for its clinical, radio imaging, and on histopathological findings.

© This is an open access article distributed under the terms of the Creative Commons Attribution License (<https://creativecommons.org/licenses/by/4.0/>) which permits unrestricted use, distribution, and reproduction in any medium, provided the original author and source are credited.

1. Introduction

An ongoing global pandemic of coronavirus disease 2019 (COVID-19) caused by (SARS-CoV-2) was first identified in December 2019 in Wuhan, China. The WHO declared a public health emergency of international concern regarding COVID-19 on 30 January 2020, and later declared a pandemic on 11 March 2020.

Now we are facing another devastating worldwide pandemic, caused by severe acute respiratory syndrome coronavirus 2 (SARS-CoV-2).¹ With to date, 24 May 2021, globally there have been 166,814,851 confirmed cases of COVID-19, including 3,458,905 deaths, reported to WHO.² Now there are increased in the super infections which were rarely reported in the beginning of the current pandemic of COVID 19. There is particularly reports about secondary fungal disease mucormycosis are on rise.

Mucormycosis, a rare fungal infection affecting immuno-compromised persons. The cases of mucormycosis has been reported from amongst those battling, and those recently recovered from COVID-19 in many regions of

India. Maharashtra state worst-hit by the second wave of the Covid-19 pandemic. To date 22 may2021, Maharashtra has reported 55,27,092 Covid-19 cases and 86,618 deaths. The state has also reported the highest number of 'black fungus' cases with 1,500 cases and 90 deaths.^{3,4} The COVID 19 pandemic has thrown up yet another challenge for the healthcare sector, with isolated cases of an unusual fungal infection being reported with also showing rise in mortality. With COVID-19 wide range of disease pattern ranging from fever, cough, breathlessness to life threatening pneumonia is noted. The various systemic manifestations and complications have been documented with many of them having emerging manifestations. Recent increase in the incidence of mucormycosis infection of the sinuses has been observed.

2. Case Report

A 47 year-old male patient who recovered from COVID-19, was admitted to our hospital at Karad, Maharashtra, having fever, facial pain, swelling mid-face region. Patient presented with severe pain and numbness over the right and left mid-face region with multiple pus draining sinuses

* Corresponding author.

E-mail address: drsvjagtap@gmail.com (S. V. Jagtap).

over the upper alveolar arch. Losing of teeth were noted. Patient is a known case of HIV since last 10 years and on ART medication. There was no history of hypertension, diabetes or any systemic disease. Patient was infected on March 2021 associated with fever, cough, breathlessness. His RT-PCR test was positive for COVID-19. He developed severe hypoxia and was kept on ventilator. Patient was discharged after 22 days with complete recovery. Then after 15 days developed facial pain, swelling mid-face region. Clinically it was suspected as ? post COVID fungal infection and ? maxillary osteomyelitis. Patient was advised with CT scan PNS, CT scan face and MRI brain. CT /MRI showed mucosal thickening noted in bilateral maxillary, sphenoid and ethmoidal sinuses. Partial obliteration of frontoethmoidal recess on right side. (Figures 1 and 2) Bilateral osteomeatal complexes are blocked. There is thinning of wall of right maxillary sinus predominantly along anterior and posterolateral walls with ill defined soft tissue thickening in the retroantral fat as well as in the premaxillary region. S-shaped deviated nasal septum noted with bony spur towards left cribriform plate, crista galli, hard palate, bilateral zygoma, bilateral orbitals appear normal. Type 1 optic nerve canal noted (Superolateral to sphenoid sinus without indentation). Soft tissue density noted in right middle ear cavity extending to mastoid antrum and mastoid air cells via aditus - features suggestive of otomastoiditis. Ossicular chain appears intact. Visualised brain parenchyma appears normal. Impression: Mucosal thickening noted in bilateral maxillary, sphenoid and ethmoidal sinuses with obliteration of bilateral osteomeatal complexes and right frontoethmoidal recess - Suggestive of chronic sinusitis. Right sided otomastoiditis. Thinning of wall of right maxillary sinus predominantly along anterior and posterolateral walls with ill defined soft tissue thickening in the retroantral region - likely infective (Fungal sinusitis merits consideration).

Patients underwent debridement of bilateral maxillary sinus, ethmoidal sinus, extraction of loose tooth (14), and curratage of alveolar, tooth root, bony tissue from maxilla and soft tissue at necrotic site.

The specimen was sent to pathology department for histopathological diagnosis. We received a specimen consisting of 20 to 25 tiny necrotic bone fragments and soft tissue and 14 teeth from maxilla. On microscopy revealed as tissue lined by stratified squamous epithelium and underlying subepithelial tissue having extensive areas of ulceration, necrosis and inflammation, predominantly of neutrophils along with scattered lymphocytes, plasma cells, macrophages and few giant cells. Areas of inflamed granulation tissue, hemorrhage and congestion was noted. Necrotic areas showed colonies of mucormycosis consisting of broad, non-septate hyphae. (Figures 3 and 4) The PAS, Grocott's methenamine silver stain showed fungal hyphae of

mucormycosis. (Figure 5)

After 1 week of treatment with Amphotericin-B - antifungal therapy showed a reduction in the diffuse opacification of the bilateral sphenoid, ethmoid and maxillary sinuses. Other clinical manifestations were reduced, the care of other parameter were taken.

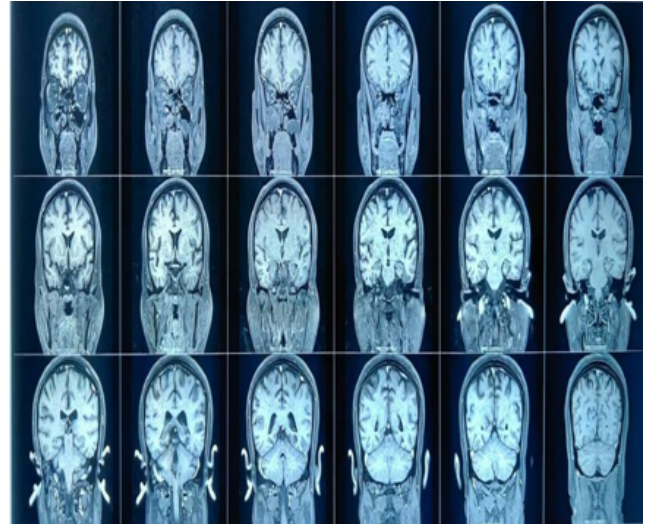


Fig. 1: MRI revealed features suggestive of invasive fungal sinusitis with osteomastoiditis.

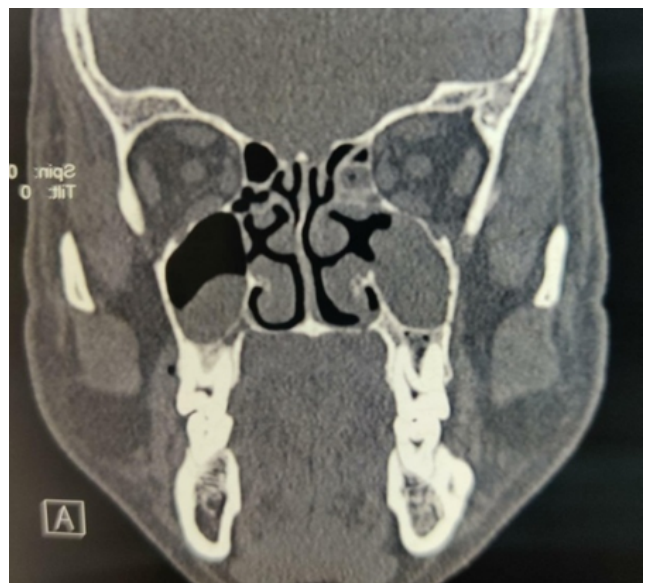

Fig. 2: CT scan face report revealed an mucosal thickening noted in right ethmoid, bilateral maxillary and sphenoid sinuses suggestive of fungal sinusitis.

3. Discussion

The outbreak of Corona virus disease 2019 (COVID-19) has changed the landscape of medicine in many ways.

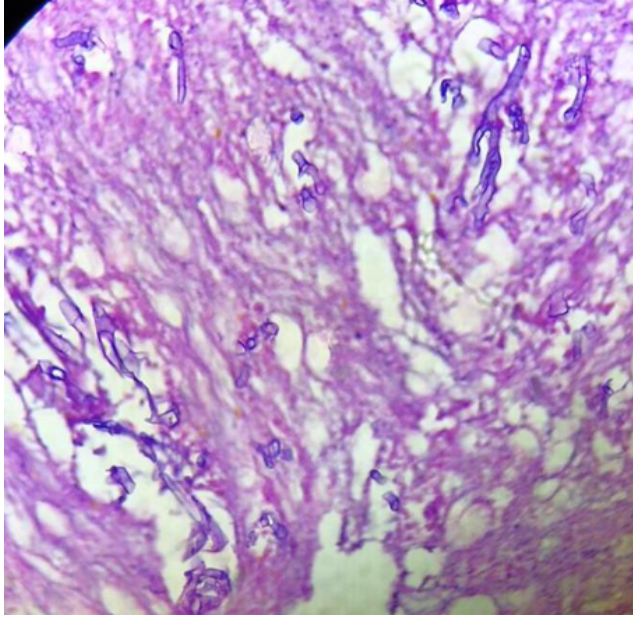


Fig. 3: Areas of inflamed granulation tissue.Necrotic areas showing colonies of mucormycosis consisting of broad, non-septate hyphae.(H&E Stain.100x)

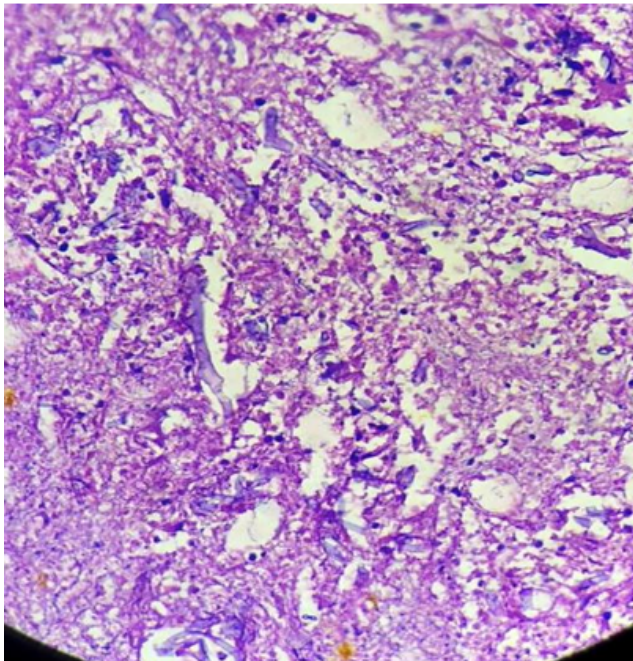


Fig. 4: Necrotic areas showing colonies of mucormycosis.(H&E Stain.100x)




Fig. 5: Grocott's methenamine silver stain showed fungal hyphae of mucormycosis

Being a new disease entity with a high infectivity rate and associated fatality, it is also associated with certain morbidities induced by novel therapeutic protocols resulting in additional challenges.

Diagnostic Test for COVID-19 infection are a Reverse Transcription Polymerase Chain Reaction (RT-PCR): is a one type of molecular diagnostic test, Nucleic Acid Amplification Test (NAAT): one type of molecular diagnostic test, Antigen Test: a diagnostic test that detects specific proteins from the virus. For immune response an Antibody (Serology) Test is done to detects antibodies that are made by your immune system in response to a threat, such as a specific virus; not used to diagnose active infection. Several variants of SARS-CoV-2 have emerged that are spreading globally. The most currently prevalent, all of which share the more infectious D614G mutation, are B.1.1.7, first detected in the UK, which has spread to over 120 countries, others variants are P.1, B.1.429, B.1.351. COVID-19 have mortality range of 0.24% to 1.49%.

Mucormycosis is observed very commonly in the environment. It is caused by exposure to mucor mould which is commonly found in soil, plants, manure, and decaying fruits and vegetables.

Mucormycosis is an opportunistic fulminant fungal infection.The peoples are prone to the infection because the body's inherent immunity is suppressed with medications, receiving high-dose steroids, HIV, transplants, diabetes, cancer etc.⁵ Patients hospitalized in intensive care units for COVID-19 has risk for invasive fungal infections particularly in individuals having chronic respiratory diseases, corticosteroid therapy, intubation/mechanical

ventilation, cytokinic storm etc. Also, it is observed that prolonged hospital stays, indwelling urinary catheters and central venous catheters coupled with antibiotic use, leads to increased chance of fungal infection.

In recent studies observed that, in COVID-19 infected patient who treated with widespread use of broad spectrum antibiotic or steroid and recovered developed secondary bacterial or fungal infection in 8%.⁶

Indian population mucormycosis prevalence is 0.14 per 1000, which is about 80 times higher than developed countries.⁷ Health care sectors across India have been reporting cases of covid-linked mucormycosis (black fungus) were significantly increased during the second wave.

Symptoms of mucormycosis include headache, fever, lethargy, painful eyes, nasal or sinus congestion, facial swelling, partial loss of vision etc. Some may even experience coughing, shortness of breath, bloody vomits, and altered mental status. In the early stages of the disease, patients exhibit facial cellulites, anesthesia, nasal discharge, necrotic turbinates, fever, headache and lethargy.⁸ In our case destruction alveolar soft tissue and underlying maxillary bone causing sinus formation, peridental swelling and ulcerations. Our patient was suffering from HIV/AIDS since last 10 years and on ART. The uncontrolled diabetes, blood sugar is high and the tissues become relatively acidic – a good environment for mucorales fungi to grow. This was identified as a risk for mucormycosis in India.

Mucormycosis is one of the most rapidly progressing and lethal form of fungal infection in humans which usually begins in the nose and paranasal sinuses.⁹

Mucormycosis affects the sinuses, bones, eyes, brain, lungs and other organ systems. These infections manifest as fungal pneumonia, gastro intestinal infection, urinary tract infections, blood stream infections, or fungal rhino-orbital-cerebral infection. The case reports were of rhinocerebral, rhino-orbital, rhino-orbito-cerebral, pulmonary, disseminated or gastrointestinal mucormycosis were noted. In our case there was no evidence disseminated infection. Y.P. Talmi et al noted rhinocerebral mucormycosis is an infection in the sinuses that can spread to the brain. This form of mucormycosis is most common in people with uncontrolled diabetes and in people who have had a kidney transplant.⁵

The mucormycosis usually gains entry through the respiratory tract and exhibits a remarkable affinity for arteries. It invades the arteries, forms thrombi within the blood vessels that reduce blood supply and cause necrosis of hard and soft tissues.¹⁰ Auluck A reported a case of Maxillary necrosis by mucormycosis.¹¹ Tissue necrosis, a hallmark of mucormycosis is often a late sign. Mehta S et al reported two cases having clinical features which pointed towards fungal maxillary osteomyelitis.¹² In severely infected COVID 19 cases the absolute number of T

lymphocytes, CD4+T and CD8+T cells are markedly lower, than moderate cases. Also the various inflammatory markers are at higher levels, like IL-2R, IL-6, IL-10, TNF-alpha.¹³

Patient are investigated for a swabs of tissue or discharge with KOH preparation and confirmatory diagnosis with a biopsy specimen of the involved tissue for mucormycosis. The stains for fungal may be supportive to confirmation. The CT/MRI is required to access disease extent.

The fatality rate of mucormycosis is 46% globally. It may be being triggered by the use of steroids, a life-saving treatment for severe and critically ill Covid-19 patients.^{14–16}

The cases of mucormycosis are rising in patient of judicious using medicines like steroids and Tocilizumab during COVID treatment. In present situation this medicines should be used in recommended doses and for a minimum duration. Physicians should be aware of the possibility of invasive secondary fungal infections in patients with COVID-19 infection. The reduction in immunity can cause mucormycosis, aspergillosis, actinomycosis *candidiasis*, etc.^{17,18}

The Steroids are also used to reduce inflammation in the lungs in Covid-19 cases and observed that it minimizes the end organ damage. But they also reduce immunity and push up blood sugar levels in both diabetics and non-diabetic Covid-19 patients. The reduction in immunity can cause mucormycosis.

To handle this severe fungal infection national multicentric studies that aim to explore the risk of fungal co-infection during COVID-19 has to be taken care of. Combined surgical and antifungal therapy was associated with significantly lower 90-day mortality compared with treatment with antifungals alone.^{19,20}

The main focus should be on the evaluation of the the incidence and the prevention of fungal infection in the course of COVID-19 and this patient should be diagnosed properly monitored carefully and immediate patient management should be started. Optimize immediate COVID-19 patient management is essential.^{21,22}

Prolonged antifungal therapy and cost of treatment made treatment challenging for the patients. With early medical and surgical management survival rates are now thought to exceed 80%. The rise in cases of mucormycosis is due to COVID-19 remain associated with impaired immune system of infected individual, so patient care and immediate patient management essential to improve outcomes.

4. Conclusion

In COVID 19 pandemic, post infection show risk of mucormycosis a fungal co-infection in our case. Prevention of fungal infections should be considered in patients after COVID-19. We are presenting this rare case of mucormycosis in post COVID-19 infection who has received steroid treatment and also case of HIV/AIDS.

5. Source of Funding

No financial support was received for the work within this manuscript.

6. Conflict of Interest

The authors declare that they have no conflict of interest.

References

- Park M, Cook AR, Lim JT, Sun Y, Dickens BL. A Systematic Review of COVID-19 Epidemiology Based on Current Evidence. *J Clin Med*. 2020;9(4):967. doi:10.3390/jcm9040967.
- WHO. COVID-19 Dashboard; 2020. Available from: <https://covid19.who.int/>.
- Skiada A, Pavleas I, Drogari-Apiranthitou M. Epidemiology and Diagnosis of Mucormycosis: An Update. *J Fungi*. 2020;6(4):265. doi:10.3390/jof6040265.
- Available from: <https://www.deccanherald.com/national/covid-19-crisis-which-states-in-india-have-reported-the-highest-number-of-mucormycosis-cases-988666.html>.
- Talmi YP, Goldschmied-Reouven A, Bakon M, Barshack I, Wolf M, Horowitz Z, et al. Rhino-Orbital and Rhino-Orbito-Cerebral Mucormycosis. *Otolaryngol Head Neck Surg*. 2002;127(1):22–31. doi:10.1067/mhn.2002.126587.
- Rawson TM, Moore LS, Zhu N. Bacterial and fungal co-infections in individuals with coronavirus: A rapid review to support COVID-19 anti-microbial prescribing. *Clin Infect Dis*. 2020;71:2459–68.
- Chander J, Kaur M, Singla N, Punia R, Singhal S, Attri A, et al. Mucormycosis: Battle with the Deadly Enemy over a Five-Year Period in India. *J Fungi*. 2018;4(2):46. doi:10.3390/jof4020046.
- Tugsel Z, Sezer B, Akalin T. Facial swelling and palatal ulceration in a diabetic patient. *Oral Surg Oral Med Oral Pathol Oral Radiol Endod*. 2004;98:630–6. doi:10.1016/j.tripleo.2004.07.006.
- Leitner C, Hoffmann J, Zerfowski M, Reinert S. Mucormycosis: necrotizing soft tissue lesion of the face. *J Oral Maxillofac Surg*. 2003;61(11):1354–8. doi:10.1016/s0278-2391(03)00740-7.
- Gupta S, Goyal R, Kaore NM. Rhino-Orbital-Cerebral Mucormycosis: Battle with the Deadly Enemy. *Indian J Otolaryngol Head Neck Surg*. 2020;72(1):104–11. doi:10.1007/s12070-019-01774-z.
- Auluck A. Maxillary necrosis by mucormycosis A case report and literature review. *Med Oral Patol Oral Cir Bucal*. 2007;12:360–4.
- Mehta S, Pandey A. Rhino-Orbital Mucormycosis Associated With COVID-19. *Cureus*. 2020;12(9):10726. doi:10.7759/cureus.10726.
- Chen G, Wu D, Guo W, Cao Y, Huang D, Wang H, et al. Clinical and immunologic features in severe and moderate Coronavirus disease 2019. *J Clin Invest*. 2020;p. 137244.
- Werthman-Ehrenreich A. Mucormycosis with orbital compartment syndrome in a patient with COVID-19. *Am J Emerg Med*. 2021;42:264.e5–e8. doi:10.1016/j.ajem.2020.09.032.
- Whoreafc-TW G, Sterne J, Murthy S, Diaz J, Slutsky A, Villar J, et al. Association between administration of systemic corticosteroids and mortality among critically ill patients with COVID-19 a meta-analysis. *JAMA*. 2020;324(13):1330–41.
- Revannavar SM, Supriya P, Samaga L, Vineeth V. COVID-19 triggering mucormycosis in a susceptible patient: a new phenomenon in the developing world? *BMJ Case Rep*. 2021;14(4):e241663. doi:10.1136/bcr-2021-241663.
- Khatib W, Jagtap S, Patel P. Tonsillar actinomycosis – A case report. *Int J Health Sci Res*. 2015;5(9):607–9.
- Song G, Liang G, Liu W. Fungal co-infections associated with global COVID-19 pandemic: a clinical and diagnostic perspective from China. *Mycopathologia*. 2020;185:599–606.
- Patel A, Kaur H, Xess I, Michael JS, Savio J, Rudramurthy S. A multicentre observational study on the epidemiology, risk factors, management and outcomes of mucormycosis in India. *Clin Microbiol Infect*. 2020;26(7):944.e9–e15.
- Jeong W, Keighley C, Wolfe R, Lee WL, Slavin MA, Chen SCA, et al. Contemporary management and clinical outcomes of mucormycosis: A systematic review and meta-analysis of case reports. *International Journal of Antimicrobial Agents*. 2019;53(5):589–597. Available from: <https://dx.doi.org/10.1016/j.ijantimicag.2019.01.002>. doi:10.1016/j.ijantimicag.2019.01.002.
- Maini A, Tomar G, Khanna D, Kini Y, Mehta H, Bhagyasree V, et al. Sino-orbital mucormycosis in a COVID-19 patient: A case report. *Int J Surg Case Rep*. 2004;82:105957.
- Garg D, Muthu V, Sehgal IS. Coronavirus Disease (Covid-19) Associated Mucormycosis (CAM): Case Report and Systematic Review of Literature. *Mycopathologia*. 2021;186(2):289–98.

Author biography

Sunil V Jagtap, Professor (Pathology, KIMSUDU, Karad)

Swati S Jagtap, Associate Professor

Vaidehi Nagar, Assistant Lecturer

Kaushiki Varshney, Assistant Lecturer

Cite this article: Jagtap SV, Jagtap SS, Nagar V, Varshney K. Invasive mucormycosis in post COVID-19 infection: Case report with review. *IP Arch Cytol Histopathology Res* 2021;6(2):135-139.