

Content available at: <https://www.ipinnovative.com/open-access-journals>

IP Archives of Cytology and Histopathology Research

Journal homepage: <https://www.achr.co.in/>

## Case Report

# Isolated prostatic tuberculosis mimicking prostatic carcinoma: a needle biopsy diagnosis

Indranil Chakrabarti<sup>1,\*</sup>, Pranati Bera<sup>1</sup>

<sup>1</sup>Dept. of Pathology, North Bengal Medical College, Siliguri, West Bengal, India



### ARTICLE INFO

#### Article history:

Received 05-07-2021

Accepted 01-09-2021

Available online 16-09-2021

#### Keywords:

prostate  
tuberculosis  
prostatic carcinoma

### ABSTRACT

Genitourinary tuberculosis is uncommon and mostly involves kidneys, seminal vesicles and epididymis. Isolated prostatic tuberculosis is rarely reported and is an under recognized entity. Here, we report such a case which clinically mimicked prostatic carcinoma and was subsequently diagnosed on image guided needle biopsy.

This is an Open Access (OA) journal, and articles are distributed under the terms of the [Creative Commons Attribution-NonCommercial-ShareAlike 4.0 License](https://creativecommons.org/licenses/by-nc-sa/4.0/), which allows others to remix, tweak, and build upon the work non-commercially, as long as appropriate credit is given and the new creations are licensed under the identical terms.

For reprints contact: [reprint@ipinnovative.com](mailto:reprint@ipinnovative.com)

## 1. Introduction

Tuberculosis is a world-wide public health problem with the maximum burden being on the developing countries. Riding high with the Human Immunodeficiency virus (HIV), we are seeing the emergence of the drug resistant strains. Practically no organ of the body seems to be immune to tubercular infection. Extrapulmonary tuberculosis accounts for 20-25% cases and genitourinary tuberculosis (GUTB) forms 27% of extrapulmonary cases.<sup>1</sup> Prostatic tuberculosis comprises of only 2.6% of the GUTB cases<sup>2</sup> thus emphasizing the rarity of the lesion. Since most cases of GUTB involve the kidneys, seminal vesicles and epididymis in males, awareness of its presence in prostate is less among among the urologists and pathologists leading to its under recognition and underreporting.<sup>3,4</sup> Moreover, it may mimic the likes of prostatic nodular hyperplasia and carcinoma and may even co-exist with these lesions. Here, we report the case of a 67-year-old man with isolated prostatic tuberculosis who was suspected clinically as having carcinoma of prostate.

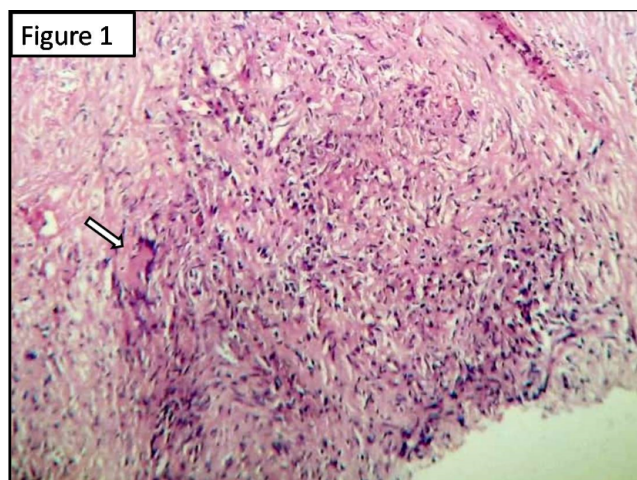
## 2. Case Report

A 67-year-old man visited Urology outpatient department with irritative voiding symptoms like increased frequency, dysuria, urgency and waking up at night. On digital rectal examination (DRE) the prostate was found to be enlarged, hard and nodular. Prostatic ultrasound revealed a heterogenous, enlarged prostate (measuring 68gm) with focal calcification and necrosis. Serum PSA level was 25.0 ng/ml (Normal level <4.0 ng/ml). Based on the clinicoradiological and serological parameters, a clinical diagnosis of carcinoma prostate was rendered and the patient underwent ultrasound guided core needle biopsy. The cores of prostatic tissue were sent to the Department of Pathology and processed accordingly. The 6 cores were embedded in 2 blocks with 3 cores each and 3 slices were taken from each block. The microscopic examination revealed prostatic tissue with decreased number of glands with fibrosis, periductal lymphocytic inflammation, epithelioid cell granulomas and Langhans giant cells. (Figure 1) Areas of caseous as well as neutrophilic necrosis noted. (Figure 2) Acid fast bacilli were identified in the Ziehl- Neelsen stained section. No focus of nodular hyperplasia or carcinoma of prostate was seen. A diagnosis of tuberculous prostatitis was rendered.

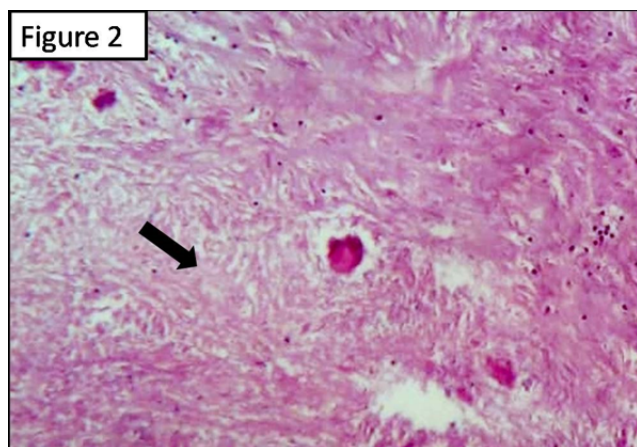
\* Corresponding author.

E-mail address: [drinch@rediffmail.com](mailto:drinch@rediffmail.com) (I. Chakrabarti).

The patient was investigated for HIV but was seronegative. He had no prior history of pulmonary tuberculosis or any history of contact with tuberculosis. The urine was sent for AFB and PCR and the results were non-contributory. The chest X-rays and sputum were within normal limits. Mantoux test was positive. A diagnosis of isolated prostatic tuberculosis was made and the patient was started on 4-drug Antitubercular therapy (ATT) regime for 6 months. The patient was relieved of symptoms at 2-month follow-up with PSA level dropping down to 3.5 ng/ml.



**Fig. 1:** Needle biopsy of prostate showing focus of epithelioid cell granuloma with Langhans giant cell (white arrow) and fibrosis. (Haematoxylin and Eosin stain; X100 magnification)



**Fig. 2:** Focus of caseous necrosis (Black arrow) with a degenerated multinucleated giant cell, surrounding fibrosis and scattered lymphocytes. (Haematoxylin and Eosin stain; X100 magnification)

### 3. Discussion

GUTB is the second most common extrapulmonary tuberculosis, only next to the lymph nodes.<sup>5</sup> As mentioned,

prostate is a still rarer site with most cases arising from descending infection from the urinary organs, direct extension from an adjacent tuberculous focus in the genitourinary tract or by hematogenous spread.<sup>4</sup> Predisposing factors include Acquired Immunodeficiency Virus Syndrome (AIDS), steroid therapy, organ transplants, immunosuppressive therapy, diseases that affect the immune system in particular cell mediated immunity.<sup>6</sup> The use of intravesical BCG for treatment of bladder carcinoma may result in tuberculous granulomas in prostate and hence, proper treatment history needs to be elucidated.

Tubercular prostatitis causes chronic granulomatous inflammation. Case reports suggest that the tuberculous infection of prostate in patients with AIDS usually present with prostatic abscess.<sup>7–9</sup> Though our patient had collections of neutrophils, he was seronegative. The caseous necrosis usually heals by fibrosis or may cause cavitation and sloughing or even autoprostectomy, if the host immunity is very poor.

Other causes of granulomatous prostatitis include non-specific granulomatous prostatitis (NSGnP) which usually forms granulomas in periductal/periglandular location and other infective agents like *Treponema pallidum*, viruses or fungi.<sup>10</sup> Special stains may prove helpful in differential diagnosis. Diagnosis of tuberculosis depends on histopathological examination, special stains, culture and molecular methods like polymerase chain reaction (PCR). Imaging studies like Transrectal ultrasonography (TRUS) or other modalities like computed tomography (CT-scan) or magnetic resonance imaging (MRI) may prove helpful in some cases.<sup>11</sup> Increasing number of such cases and the curative treatment make this a very important entity to diagnose.<sup>12</sup>

### 4. Conclusion

Prostatic tuberculosis is a rare occurrence and usually results from hematogenous spread from other focus in the body. Primary prostatic tuberculosis is still rarer and requires high index of suspicion. They can mimic carcinoma of prostate clinicoradiologically as well as serologically. Treatment protocol may vary from country to country and case to case. Early detection and treatment are important which require awareness among the urologists and pathologists. TRUS guided needle biopsies may be adequate to pick up the diagnosis in most of the cases.

### 5. Conflict of Interest

The authors declare that there are no conflicts of interest in this paper.


### 6. Source of Funding

None.

## References

1. Chan WC, Thomas M. Prostatic abscess: Another manifestation of tuberculosis in HIV-infected patients. *Aust N Z J Med*. 2000;30(1):94–5. doi:10.1111/j.1445-5994.2000.tb01067.x.
2. Kulchavenya E, Brizhatyuk E, Khomyakov V. Diagnosis and therapy for prostate tuberculosis. *Ther Adv Urol*. 2014;6(4):129–34. doi:10.1177/1756287214529005.
3. Mishra KG, Ahmad A, Singh G, Tiwari R. Tuberculosis of the prostate gland masquerading prostate cancer: five cases experience at IGIMS. *Urol Ann*. 2019;11(4):389–92. doi:10.4103/UA.UA\_119\_18.
4. Gupta N, Mandal AK, Singh SK. Tuberculosis of the prostate and urethra: A review. *Indian J Urol*. 2008;24(3):388–91.
5. Pal DK. Tuberculosis of prostate. *Indian J Urol*. 2002;8(2):120–2.
6. Gow JG. Genitourinary tuberculosis. In: Walsh P, Vaughan E, Retik A, editors. *Campbell's Urology*. 7th Edn. Philadelphia: WB Saunders; 1998. p. 817–8.
7. Trauzzi SJ, Kay CJ, Kaufman DG, Lowe FC. Management of prostatic abscess in patients with human immunodeficiency syndrome. *Urology*. 1994;43(5):629–33. doi:10.1016/0090-4295(94)90176-7.
8. Lanjewar DN, Maheshwari MB. Prostatic tuberculosis and AIDS. *Nail Med J India*. 1994;7(4):166–7.
9. Wolf LE. Tuberculosis abscess of the prostate in AIDS. *Ann Intern Med*. 1996;125(2):156. doi:10.7326/0003-4819-125-2-199607150-00029.
10. Gupta N, Mandal AK, Singh SK. Tuberculosis of the prostate and urethra: A review. *Indian J Urol*. 2008;24(3):388–91.
11. Wang JH, Sheu MH, Lee RC. Tuberculosis of the prostate: MR appearance. *J Comput Assist Tomog*. 2007;21(4):639–40. doi:10.1097/00004728-199707000-00023.
12. Gupta S, Khumukcham S, Lodh B, Singh AK. Primary prostatic tuberculosis: A rare entity. *J Med Soc*. 2013;27(1):84–6.

## Author biography

**Indranil Chakrabarti**, Associate Professor  <https://orcid.org/0000-0002-3651-2986>

**Pranati Bera**, Associate Professor

**Cite this article:** Chakrabarti I, Bera P. Isolated prostatic tuberculosis mimicking prostatic carcinoma: a needle biopsy diagnosis. *IP Arch Cytol Histopathology Res* 2021;6(3):214-216.