

Content available at: <https://www.ipinnovative.com/open-access-journals>

IP Archives of Cytology and Histopathology Research

Journal homepage: <https://www.achr.co.in/>

## Case Report

# Fibroepithelial polyp (Acrochordon) of breast nipple– A rare clinical presentation

Vineet Banga<sup>1,\*</sup>, Stuti Jain<sup>1</sup>

<sup>1</sup>Dept. of Pathology, Acharyashree Bhikshu Government Hospital(Govt. of NCT of Delhi), Moti Nagar, New Delhi, India



### ARTICLE INFO

#### Article history:

Received 20-12-2021

Accepted 15-01-2022

Available online 04-03-2022

#### Keywords:

Fibroepithelial polyp

Acrochordon

Breast nipple

### ABSTRACT

Fibroepithelial polyp (FEP) or acrochordon are skin tags frequently arising in skin folds in locations like the neck, axilla, perineum, eyelids and chest wall. Only 7 cases of FEP of the nipple have been reported in the literature so far. Here we report such a rare case diagnosed on FNAC and Biopsy.

This is an Open Access (OA) journal, and articles are distributed under the terms of the [Creative Commons Attribution-NonCommercial-ShareAlike 4.0 License](https://creativecommons.org/licenses/by-nc-sa/4.0/), which allows others to remix, tweak, and build upon the work non-commercially, as long as appropriate credit is given and the new creations are licensed under the identical terms.

For reprints contact: [reprint@ipinnovative.com](mailto:reprint@ipinnovative.com)

## 1. Introduction

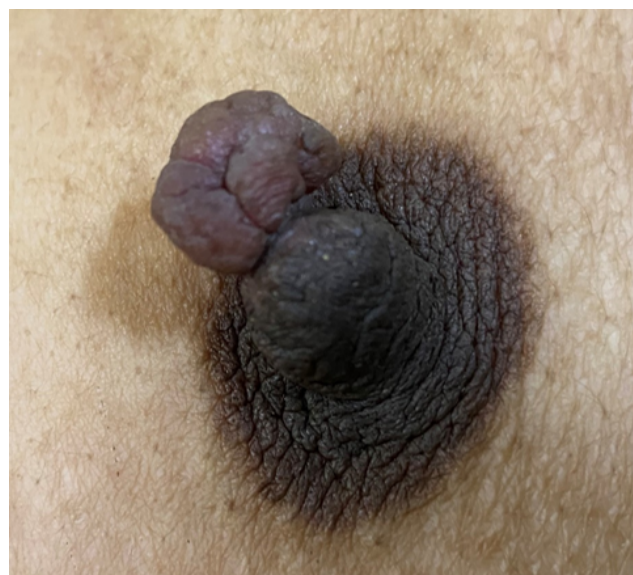Soft fibroma (skin tags) is a slow-growing benign tumor of mesodermal origin most frequently arising in skin folds in locations like the neck, axilla, perineum, eyelids and chest wall; typically occurring in women of reproductive age.<sup>1</sup> Acrochordons are skin tags which are soft, papules with a stalk. A rare form of skin tag is fibroepithelial polyp, which, in contrast, is a bigger lesion with long, narrow stalk, and may appear pedunculated.<sup>2</sup> The known causes may be congenital lesions, chronic irritation, allergies and trauma.

## 2. Case Report

A 35 year old woman visited surgery OPD with a 5 year history of a painless swelling on nipple of right breast. The lesion progressively increased in size. There was no history of breast lump or any nipple discharge. She has two children with the last pregnancy 9 years back and normal menstrual history.

On clinical examination, the mass was 1.5cm X 1 cm polyp attached to the nipple of the right breast. The polyp was bag-like and non-ulcerative with firm in consistency. No acanthosis nigricans or epidermal nevus was found on

the surrounding skin. The bilateral nipple areolar complex and the breast were normal without any lump. There was no axillary lymphadenopathy. Clinically, it was diagnosed as a benign polyp.(Figure 1)



**Fig. 1:** Polypoid mass on Right breast nipple

\* Corresponding author.

E-mail address: [drvineetbanga@rediffmail.com](mailto:drvineetbanga@rediffmail.com) (V. Banga).

The patient was advised FNAC. The FNAC procedure was difficult to perform as the needle could not be moved easily in the lesion due to firm swelling. FNAC smears showed fibrous fragments along with haemorrhagic background. The possibility of Fibroepithelial Polyp was suggested on FNAC based on clinical and cytological features and biopsy was advised to confirm the diagnosis as rare clinical site for acrochordon.

Total surgical excision of the polyp sparing the right nipple was performed and the specimen was sent for histopathological examination. On gross examination, the polypoidal mass was greyish-brown measuring 1.5cm X 1 cm. (Figure 2)



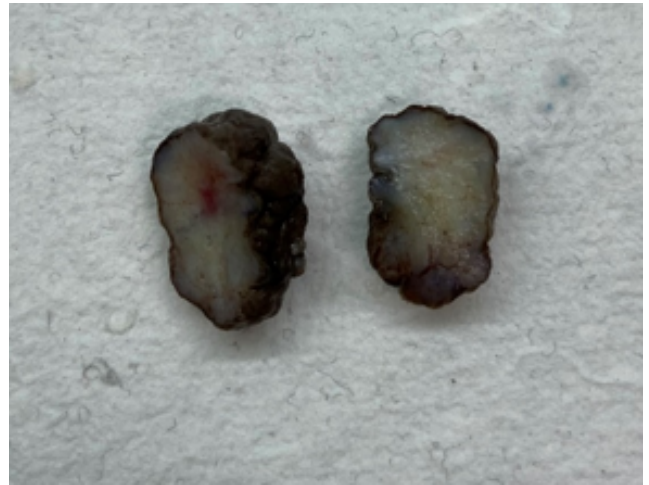
**Fig. 2:** Gross specimen of polypoidal lesion measuring 1.5cm X 1 cm.

On cut section, it showed white homogenous areas (Figure 3).

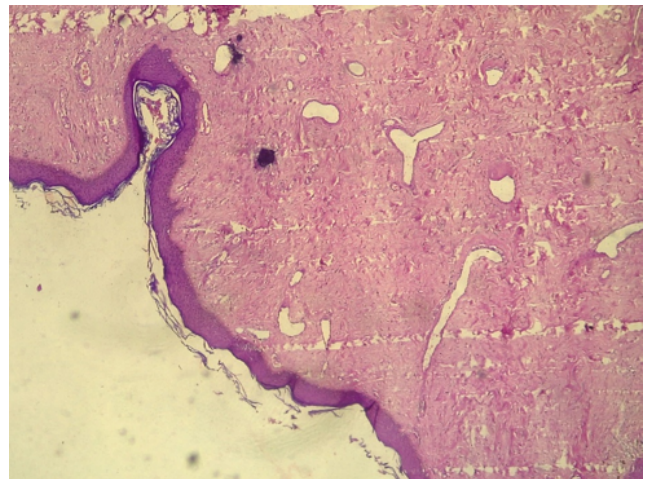
On microscopic examination, section showed polypoidal tissue lined by stratified squamous epithelium exhibiting focal acanthosis, mild hyperkeratosis along with fibro collagenous stroma and dilated capillary sized blood vessels. The final histopathological diagnosis was given as fibroepithelial polyp.(Figures 4, 5 and 6)

### 3. Discussion

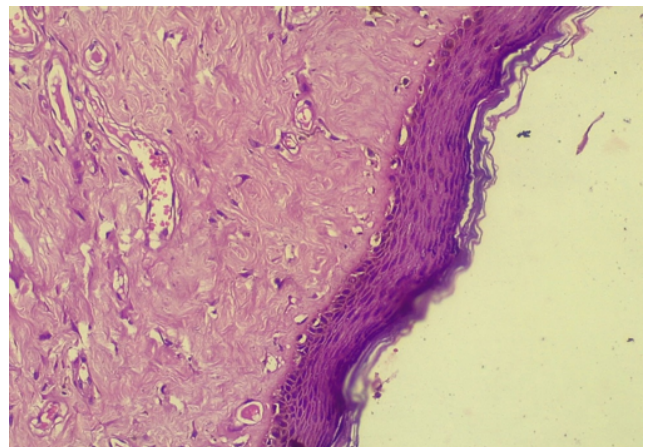
The fibroepithelial polyp is amongst the common benign skin tumors. The fibroepithelial polyps are skin tags which have large sizes and are pedunculated and may be referred as acrochordon.<sup>3</sup> The most common occurrence is on neck, axilla, perineum and thighs. They might also occur on female genitalia like vulva as well as male external genitalia like penis and urethra.<sup>4</sup> These tumors on the nipple present as a diagnostic challenge due to the rarity of the location as only 7 cases of FEP of the nipple have been reported in



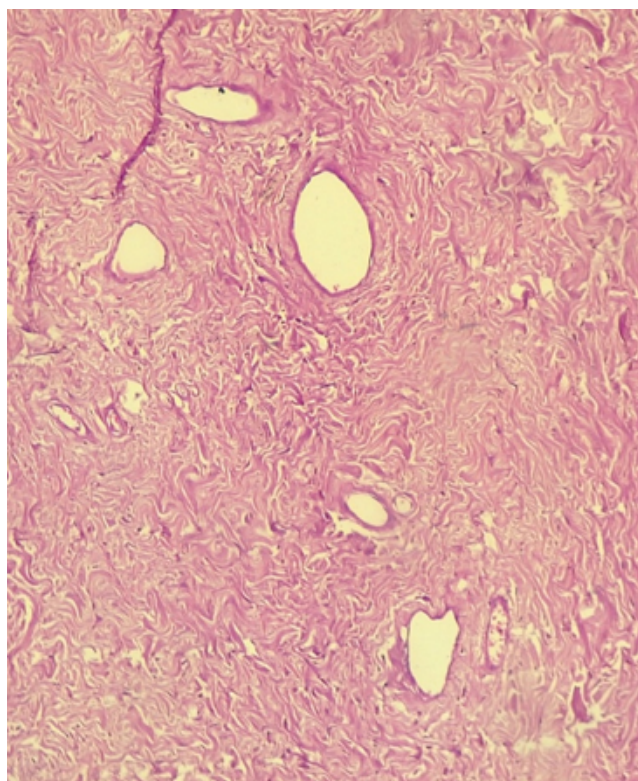
**Fig. 3:** Cut section of polypoidal lesion showing white homogenous areas



**Fig. 4:** Microphotograph showing focal acanthosis and papillomatosis in the epidermis. (Hematoxylin & Eosin stain, X 40 Magnification)



**Fig. 5:** Microphotograph showing mild hyperkeratosis in the epidermis.(Hematoxylin & Eosin stain, X 200 Magnification)



**Fig. 6:** Microphotograph showing fibrocollagenous tissue and abundant dilated blood vessels.

the literature.<sup>5</sup> The differential diagnoses for benign lesions on the nipple includes adnexal polyp, supernumerary nipple, neurofibroma, adenoma, papilloma, wart, leiomyoma and epidermal cyst.<sup>6</sup> All these entities can be grossly similar to each other and therefore require histologic examination for definitive diagnosis. It is important to recognize and diagnose definitively so as to reassure the patient and for appropriate management of the lesion.<sup>7</sup>

#### 4. Conclusion

Fibroepithelial polyp of the nipple is a rare, but benign tumor that is adequately managed with surgical excision. With fibroepithelial polyps seldomly reported in the literature, it is important to differentiate this lesion from

other benign and malignant growths. When a patient presents with a benign-appearing nipple lesion the steps should include a complete patient history, family history; clinical examination of bilateral nipples, breasts, and axillae; FNAC and excisional biopsy for confirming benign nature of the lesion, cosmesis and reassurance of the patient.

#### 5. Conflict of Interest

The authors declare that there is no conflict of interest.

#### 6. Source of Funding

None.

#### References

1. Madueke-Laveaux OS, Gogoi R, Stoner G. Giant fibroepithelial stromal polyp of the vulva: largest case reported. *Ann Surg Innov Res.* 2013;7:8. doi:10.1186/1750-1164-7-8.
2. Arora BK. A clinical case of large fibroepithelial polyp of breast nipple. *Int J Case Rep Images.* 2019;doi:10.5348/100997Z01BA2019CR.
3. You HS, Park SM, Cho HH. A case of Soft Fibroma of the nipple with a cauliflower-like appearance. *Ann Dermatol.* 2015;27(1):102–3.
4. Belli AK, Somuncu E, Aydogan T, Bakkaloglu D, Ilvan S, Aydogan F, et al. Fibroepithelial polyp of the nipple in a woman. *Breast J.* 2013;19(1):111–2.
5. Shaaban AM, Turton EPL, Merchant W. An unusual case of a large fibroepithelial stromal polyp presenting as a nipple mass. *BMC Res Notes.* 2013;6:345. doi:10.1186/1756-0500-6-345.
6. Spyropoulou GA, Pavlidis L, Trakatelli M. Rare benign tumours of the nipple. *J Eur Acad Dermatol Venereol.* 2015;29(1):7–13.
7. Spohn GP, Trotter SC, Tozbikian G, Povoski SP. Nipple adenoma in a female patient presenting with persistent erythema of the right nipple skin: case report, review of the literature, clinical implications, and relevancy to health care providers who evaluate and treat patients with dermatologic conditions of the breast skin. *BMC Dermatol.* 2016;16(1):4. doi:10.1186/s12895-016-0041-6.

#### Author biography

**Vineet Banga**, HOD

**Stuti Jain**, Senior Resident

**Cite this article:** Banga V, Jain S. Fibroepithelial polyp (Acrochordon) of breast nipple– A rare clinical presentation. *IP Arch Cytol Histopathology Res* 2022;7(1):54–56.