

Content available at: <https://www.ipinnovative.com/open-access-journals>

IP Archives of Cytology and Histopathology Research

Journal homepage: <https://www.achr.co.in/>

Case Report

Osseous metaplasia in multiple broad ligament leiomyomas: An extreme rarity

Rajeev Saxena^{1,*}, Nidhi Agarwal¹, Rangwala Tasneem¹, Deeksha Buliwal¹

¹Dept. of Pathology, Government Medical College, Kota, Rajasthan, India



ARTICLE INFO

Article history:

Received 22-01-2022

Accepted 28-01-2022

Available online 04-03-2022

Keywords:

Leiomyoma

Metaplasia

Osseous

ABSTRACT

Osseous metaplasia in a leiomyoma is an uncommon clinical entity with the presence of mature and immature bone in a leiomyoma. Infection, necrosis, hyaline degeneration, calcification and myxoid degeneration are the most common secondary degenerative changes seen in cases of leiomyoma. Calcified and ossified leiomyomas are uncommon and is rarely reported in literature. We report one such case in a 45 year old perimenopausal female who presented clinically with abnormal uterine bleeding. Multiple nodules were seen in bilateral broad ligaments, which on histopathology revealed features of osseous metaplasia in hyalinized degenerated leiomyomas, an extremely rare clinical entity.

This is an Open Access (OA) journal, and articles are distributed under the terms of the [Creative Commons Attribution-NonCommercial-ShareAlike 4.0 License](https://creativecommons.org/licenses/by-nc-sa/4.0/), which allows others to remix, tweak, and build upon the work non-commercially, as long as appropriate credit is given and the new creations are licensed under the identical terms.

For reprints contact: reprint@ipinnovative.com

1. Introduction

Smooth muscle tumors of the female genital tract rarely occur outside the myometrium. Such tumors, when located in the immediate parametrial and para-adnexal connective tissues, have received scant attention, and little is known about their clinical and pathological features.¹ Microscopically parauterine tumors showed interlacing bundles of plump fusiform cells.² Osseous metaplasia of leiomyoma is an uncommon clinical entity with a presence of mature and immature bone in the leiomyoma.³ Infection, necrosis, hyaline degeneration, calcification and myxoid degeneration are the most common secondary degenerative changes seen in cases of leiomyoma. Calcified and ossified leiomyomas are uncommon and rarely reported in literature.⁴ We present a case of osseous metaplasia of leiomyoma occurring in bilateral broad ligaments.

2. Case Report

A 45 year old perimenopausal female was complaining of abnormal uterine bleeding. Obstetric history was notable for two spontaneous deliveries at term. Routine hematological and biochemical investigations were within normal limits. Ultrasound examination revealed a well defined round altered echogenic lesion, noted at fundus of uterus, measuring 10x7x4.5cm, suggestive of subserosal fibroid. She underwent total abdominal hysterectomy with bilateralsalpingo-oophorectomy. Grossly we received a specimen of uterus with cervix and bilateral adenexa, it measured 11x8x5cm, multiple calcified nodules were present in the broad ligaments on both sides, ranging from 0.5 to 1cm which were very hard and cut with difficulty. H and E stained sections from the nodules, revealed similar picture. Tumor was composed of hyalinised bundles of smooth muscles, areas of bony trabeculae with foci of ossification. Attached myometrium also revealed calcification. However there was no significant pleomorphism, nuclear atypia or mitosis. Patient had no metabolic calcium disorder, her serum calcium and phosphate were in the normal range, a histopathological

* Corresponding author.

E-mail address: rajprasax58@gmail.com (R. Saxena).

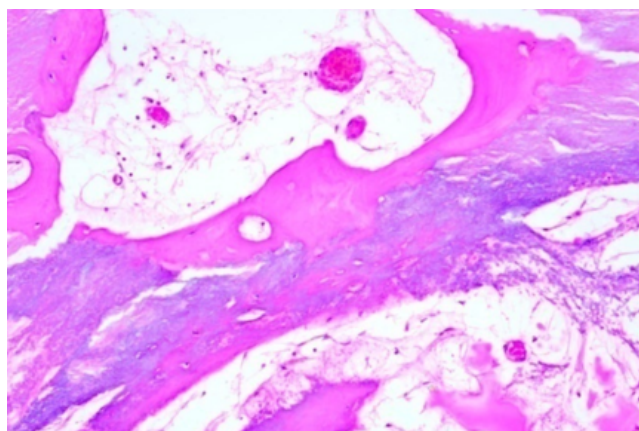


Fig. 3: Bony trabeculae with fatty marrow and few marrow cells. Lacunae are clearly seen.(400x)

diagnosis of osseous metaplasia with areas of calcification in hyalinized degenerated leiomyomas was given. Uterus, cervix with bilateral adenexa with multiple calcified nodules were present in broad ligament on both sides.

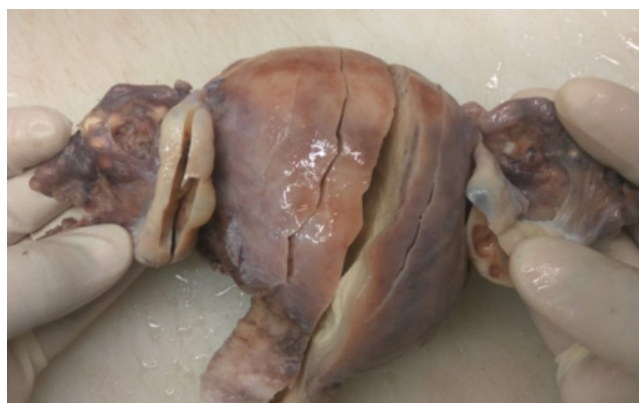

Fig. 1: Uterus, cervix with bilateral adenexa. Multiple calcified nodules were present in broad ligament on both sides.

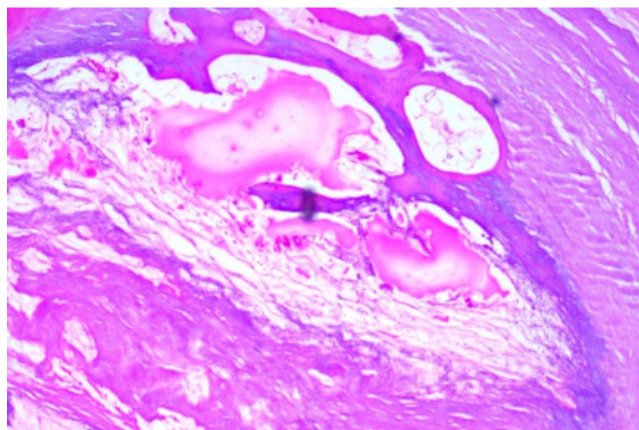


Fig. 2: Hyalinised leiomyoma showing well formed bony trabeculae with lacunae (100x)

3. Discussion

Being one of the commonest tumor of female genital tract, the leiomyoma expectedly demonstrates a wide spectrum of histological variations. However, heterologous tissue differentiation is a rare finding and frank bone formation is even rarer. Leiomyomas are known to display a variety of histopathological variants, the usual type, cellular, mitotically active, atypical or plexiform, epithelioid and myxoid leiomyoma.⁵ Calcification is rare and is seen only in 8% of the cases. Metaplasia occur as a result of reprogramming of stem cells or of undifferentiated mesenchymal cells, which differentiate along a new pathway. This differentiation is brought about by signals generated by cytokines, growth factors and extracellular matrix components in the cell's environment.^{6,7} In most of the reported cases, the osseous changes in the leiomyomas were followed by a previous history of abortion. Majority of the patients are in the reproductive age group. The time interval between the antecedent abortion and discovery of ossification varies from 8 weeks to 14 years in reproductive age group.⁸ The pathogenesis of ossification has been discussed by many hypothesis such as hypercalcemia, hypervitaminosis D, hyperphosphatemia, chronic endometritis, pyometra, persistent stimulation of endometrium by estrogen or osteogenesis in the surrounding endometrium which is promoted by retained fetal bones or dystrophic calcification part of the osteoblastic process.⁹ The indexed case is also rare as patient had no such complaints. Role of estrogen has been found to have osteogenesis promoting effect.¹⁰ Our patient was of perimenopausal age group, had only a history of abnormal uterine bleeding and her family was completed. So she agreed for hysterectomy. Adomsons & Somners reported a case of ossification in leiomyoma in a patient who was taking high dose of calcium and vitamin D for long time. No such history was found in our patient and our case had normal serum calcium and phosphate levels that rules out any such type of metabolic cause for ossification.^{11,12}

4. Conclusion

Present rare case highlights occurrence of multiple nodules in bilateral broad ligaments which revealed features of osseous metaplasia in hyalinized degenerated leiomyomas.

5. Conflict of Interest

The authors declare that there is no conflict of interest.

6. Source of Funding

None.

References

- Chander B, Shekhar S. Osseous metaplasia in leiomyoma: A first in a uterine leiomyoma. *J Can Res Ther.* 2015;11(3):661. doi:10.4103/0973-1482.138104.
- Wells BM. Tumors of myometrium. In: Christopher D, editor. Diagnostic histopathology of tumors, 2nd Edn. London: Chur-chill Livingstone; 2002. p. 676-84.
- Umashankar T, Patted S, Handigund RS. Endometrial osseous metaplasia: Clinicopathological study of a case and literature review. *J Hum Reprod Sci.* 2010;3(2):102-4. doi:10.4103/0974-1208.69329.
- Montague LJ, Fitzpatrick SG, Islam NM, Cohen DM, Bhattacharyya I. Extensively ossifying oral leiomyoma: A rare histologic finding. *Head Neck Pathol.* 2014;8(3):311-6. doi:10.1007/s12105-013-0497-1.
- Kumar V, Abbas AK, Fausto N, Aster JC. Robbins and Cotran Pathologic Basis of Disease. 8th Edn. Philadelphia: Saunders: Elsevier; 2010. p. 11.
- Errarhay S, Mamouni N, Mahmoud S, El-Fatemi H, Saadi H, Mesbahi O, et al. Primary Malignant Melanoma of the Female Genital Tract: Unusual Localization. *J Case Rep.* 2013;3(1):169-75. doi:10.17659/01.2013.0041.
- Umashankar T, Patted S, Handigund R. Endometrial osseous metaplasia: Clinicopathological study of a case and literature review. *J Hum Reprod Sci.* 2010;3(2):102-4. doi:10.4103/0974-1208.69329.
- Shimizu M, Nakayama M. Endometrial ossification in a postmenopausal woman. *J Clin Pathol.* 1997;50(2):171-2. doi:10.1136/jcp.50.2.171.
- Nigar A, Yadav YK, Hakim S. Endometrial osseous metaplasia-a rare presentation of polymenorrhagia: a case report. *J Clin Diagn Res.* 2015;9(4):QD07-8. doi:10.7860/JCDR/2015/12221.5844.
- Bahçeci M, Demirel LC. Osseous metaplasia of the endometrium: A rare cause of infertility and its hysteroscopic management. *Hum Reprod.* 1996;11(11):2537-9.
- Jr NA, Sommers SC. Endometrial ossification. Report of two cases. *Am J Obstet Gynecol.* 1954;67(1):187-90.
- Patil S, Narchal S, Paricharak D, More S. Endometrial osseous metaplasia: case report with literature review. *Ann Med Health Sci Res.* 2013;3(1):10-2. doi:10.4103/2141-9248.121209.

Author biography

Rajeev Saxena, Professor and Head

Nidhi Agarwal, Assistant Professor

Rangwala Tasneem, Senior Resident

Deeksha Buliwal, 3rd Year Resident

Cite this article: Saxena R, Agarwal N, Tasneem R, Buliwal D. Osseous metaplasia in multiple broad ligament leiomyomas: An extreme rarity. *IP Arch Cytol Histopathology Res* 2022;7(1):75-77.