

Content available at: <https://www.ipinnovative.com/open-access-journals>

IP Archives of Cytology and Histopathology Research

Journal homepage: <https://www.achr.co.in/>

## Original Research Article

## Atherosclerosis in coronary arteries and aorta by modified American heart association classification: An autopsy study

Harveen B<sup>1,\*</sup>, Vijaya C<sup>1</sup>, Smita M<sup>1</sup><sup>1</sup>Dept. of Pathology, Sapthagiri Medical College & Research Centre, Bengaluru, Karnataka, India

## ARTICLE INFO

## Article history:

Received 08-04-2022

Accepted 21-04-2022

Available online 29-06-2022

## Keywords:

Atherosclerosis

Autopsy

Ischemic Heart Disease

## ABSTRACT

**Background:** Ischemic heart disease following atherosclerosis is a leading cause of deaths among Indians. The study was formulated to assess the Histomorphological atherosclerotic changes in coronaries and aorta in autopsy by applying Modified American Heart Association Classification (AHA) among the autopsy cases received at SIMS & RC, Bangalore.

**Aims and Objectives:** 1. To evaluate the autopsies for atherosclerosis in coronary arteries and aorta. 2. To classify atherosclerosis in coronary arteries (right coronary, left coronary, left anterior descending) and aorta by Modified American Heart Association classification (Grade 1-8).

**Materials and Methods:** Autopsy was studied for 49 cases from June 2019 to August 2019. It was conducted by conventional method and heart was dissected along the flow of blood. Grossly macro-assessment was done and on histopathology examination microscopic assessment was done using Modified American Heart Association Classification.

**Results:** A total of 49 cases were studied, of which 42 cases were male and 7 were females. Male to female ratio was around 6:1. Coronary showing major occlusion was Left Anterior Descending followed by Right Coronary and then Left Circumflex artery. Major number of cases were belonging to grade 4 (59.1%) followed by in grade 3 (38.7%). Calcification was noted in 6 cases (12.2%) and ruptured plaque in 4 (8.16%).

**Conclusion:** With the cardiovascular diseases attaining pandemic proportions, the study of atherosclerosis and its grading is the need of hour to estimate disease burden. Autopsy studies play a vital role in unraveling the spectrum and occurrence of atherosclerosis.

This is an Open Access (OA) journal, and articles are distributed under the terms of the [Creative Commons Attribution-NonCommercial-ShareAlike 4.0 License](https://creativecommons.org/licenses/by-nc-sa/4.0/), which allows others to remix, tweak, and build upon the work non-commercially, as long as appropriate credit is given and the new creations are licensed under the identical terms.

For reprints contact: [reprint@ipinnovative.com](mailto:reprint@ipinnovative.com)

## 1. Introduction

Cardiovascular disease (CVD) is a major health burden worldwide leading to deaths. Advances in treatment & effective secondary prevention, has improved life expectancy.<sup>1,2</sup> Autopsy study for assessing atherosclerosis is proved as a great method, since this study is invasive, expensive & difficult in living population. Autopsy findings reveal, majority of sudden and unexpected deaths are sequel to coronary artery disease.<sup>3</sup> Disease is frequently concealed

and discovered at postmortem through macroscopic & microscopic examination.<sup>4,5</sup> Hence this study was designed to study macroscopically & microscopically coronary arteries and aorta in the autopsies received at SIMS & RC, Bangalore.

## 2. Materials and Methods

The present study was a cross-sectional study conducted during the period of June 2019 to August 2019. A total of 49 autopsy with heart received in pathology department, SIMS & RC, Bangalore were examined grossly

\* Corresponding author.

E-mail address: [sethi.harveen1995@gmail.com](mailto:sethi.harveen1995@gmail.com) (Harveen B).

and microscopically for the presence and extent of atherosclerosis and evidence of myocardial infarction. Heart was fixed in 10% formalin, weighed, and dissected by Inflow-Outflow method of dissection. Measurements of right ventricular wall, left ventricular wall, and stump of aorta were done. Three main coronaries (right coronary, left coronary and left anterior descending) and aorta were dissected extensively at every 3-4cms to look for yellow streaks, thickening, plaques and calcification macroscopically. Then routine processing and paraffin embedding, 3-5micro meter section cutting and staining with H&E was done. Microscopic examination was done and graded according to Modified American Heart Association criteria.

### 2.1. Modified American Heart Association criteria for grading atherosclerotic lesions.<sup>2</sup>

1. Grade 1: isolated intimal foamy cells (minimal change)
2. Grade 2: numerous intimal foamy cells often in layers (fatty streaks)
3. Grade 3: pools of extracellular lipid without a well defined core (intermediate lesion of pre-atheroma)
4. Grade 4: well defined lipid core with luminal surface covered by normal intima (atheroma or fibro plaque)
5. Grade 5: lipid core with a fibrous cap with or without calcification (fibro atheroma)
6. Grade 6: fibro-atheroma with cap defect such as haemorrhage and thrombosis
7. Grade 7: calcification prominent
8. Grade 8: fibrous tissue change prominent.

## 3. Results

### 3.1. Sex distribution of cases in study

A total of 49 autopsy cases with heart received at SIMS & RC, Bangalore were included in this study. The distribution of the cases according to sex were studied. Out of a total of 49 cases, there were 42(86%) males and 7(14%) females. This is shown in Figure 1 and Table 1.

### 3.2. Severity based on percentage of occlusion in coronaries and aorta

Coronaries and aorta of the autopsy cases were graded on the basis of occlusion. Left Anterior descending Artery was the most common coronary with 50 – 100% occlusion followed by Right Coronary Artery and then Left Circumflex and Aorta. This is shown in Figure 2.

Severity of Occlusion for coronaries and aorta were graded as Percentage of occlusion (Figure 2 and Table 2) and by Modified AHA (Figure 3). Coronaries and aorta were graded in 1-7 grades as per Modified AHA (Figure 3 and Table 3). To our finding, it was seen that in all the autopsy

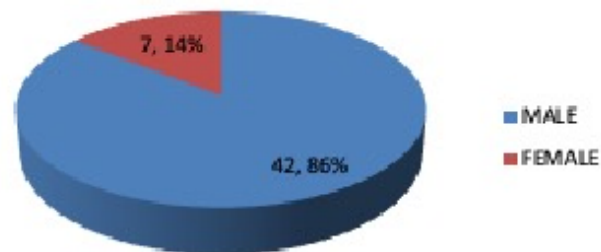


Fig. 1:

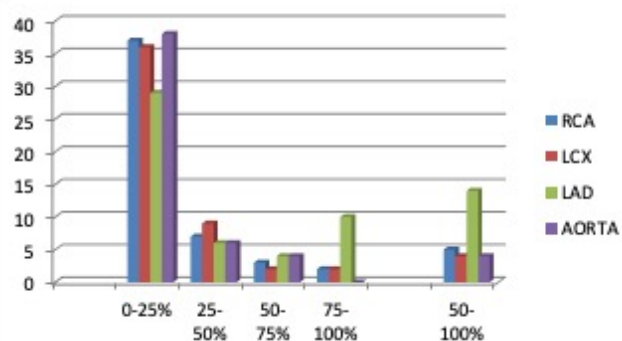


Fig. 2:

cases coronaries and aorta were involved to some extent. But Left Anterior Descending is the most common coronary involved with grade 4-7 followed by Right Coronary Artery and Left Circumflex artery.

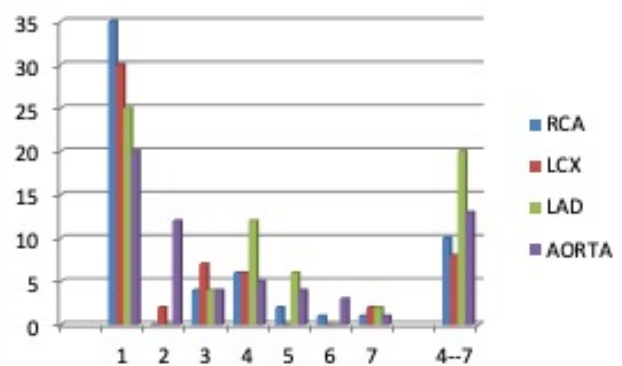


Fig. 3:

## 4. Discussion

The distribution of atherosclerosis in the body at autopsy has been in talks as the subject of morphological studies.<sup>6</sup> There is an alarming increase in the number of deaths

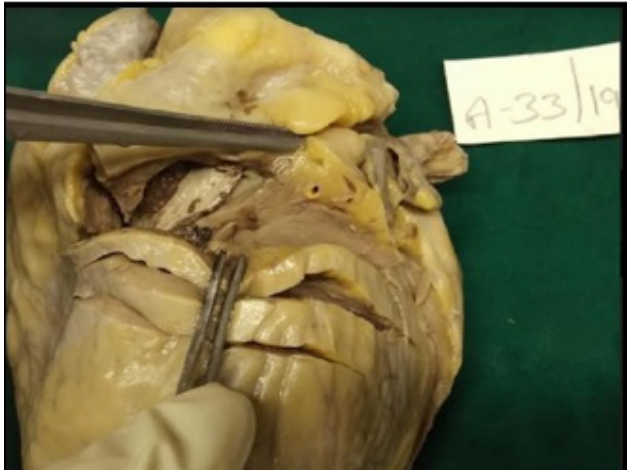


Fig. 4:

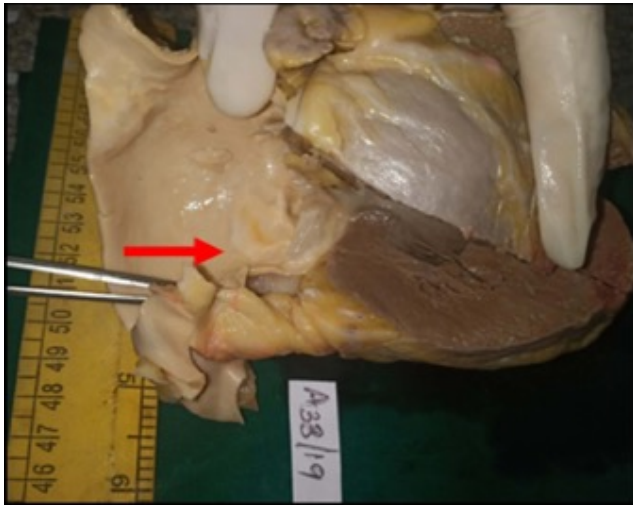


Fig. 5:

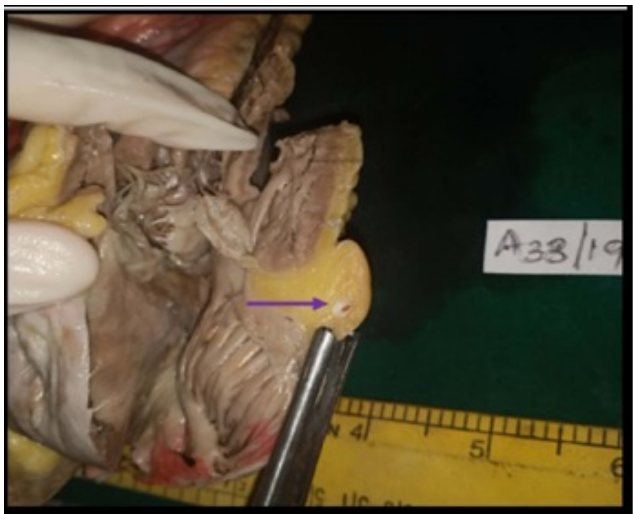

Fig. 6:

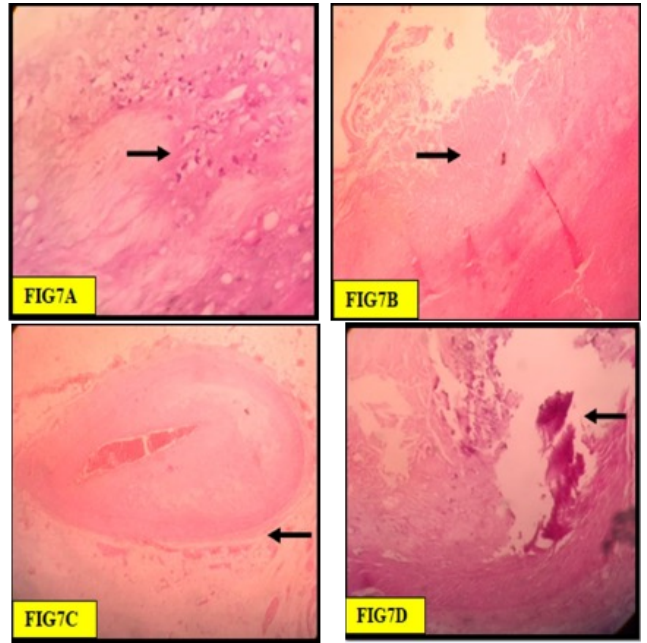


Fig. 7:

Table 1: Distribution of the autopsy cases based on sex

	No of cases	Percentage (%)
Males	42	86
Females	7	14
Total	49	100

Table 2: Severity of autopsy cases based on percentage of occlusion

Occlusion (%)	RCA	LCX	LAD	AORTA
0-25	37	36	29	38
25-50	7	9	6	6
50-75	3	2	4	4
75-100	2	2	10	0
50-100	5	4	14	4

Table 3: Severity of autopsy cases based on modified AHA

Grade	RCA	LCX	LAD	AORTA
1	35	30	25	20
2	0	2	0	12
3	4	7	4	4
4	6	6	12	5
5	2	0	6	4
6	1	0	0	3
7	1	2	2	1

due to coronary atherosclerosis in India and this number is expected to escalate rapidly in the next decade.<sup>2</sup> The term 'athero' means porridge and 'sclerotic' means hardening or fibrosis and is derived from Greek terminology.<sup>7</sup> It is a complex inflammatory disease leading to accumulation of fat and cholesterol within arterial wall.<sup>8</sup> Endothelial dysfunction, vascular inflammation and build up of plaques within intima of the vessel wall are its characteristic features.<sup>9</sup> These plaques are composed of large lipid core, inflammatory cells including macrophages with fibrous cap.<sup>10</sup> Atherosclerosis is a disease of large and medium sized muscular arteries, characterized by inflammation of smooth muscle cells with formation of atherosclerotic plaques.<sup>11</sup> These plaques are made up of necrotic cores, calcium deposits, modified lipids, endothelial cells and foam cells.<sup>12–17</sup> Thus atherosclerosis is the most common pathologic process leading to cardiovascular disease.<sup>18–20</sup>

The Modified AHA Classification of atherosclerosis based on morphological descriptions was used in this study since it offers better categorization of atherosclerotic lesions.<sup>1</sup> Modifiable and nonmodifiable risk factors for atherosclerotic lesions are smoking, alcohol, obesity, hypertension, diabetes mellitus, genetic causes etc.<sup>1</sup>

In our study, a total of 49 cases of autopsy received at SIMS & RC, Bangalore was studied. In the present study out of 49 cases, 42 were males (85.71%) and 7 were females (14.2%) which was more or less similar to studies done in the past. Garg M et al<sup>2</sup> studied 93 cases, out 71 (80.9%) were males and 22 (19.1%) were females. Murthy et al<sup>21</sup> studied 150 cases out of which 123 (28%) were males and 27 (18%) were females.

Macroscopic examination and microscopic Modified AHA grading was done for all the cases in the present study and it was observed that all the cases were affected to some extent. Macroscopically coronaries were observed for thickening, lumen occlusion (Figure 4), calcification (Figure 6), aorta was examined for presence of fatty streaks (Figure 5).

Microscopically these coronaries and aorta were observed and graded according to Modified AHA classification. While some cases happened to just show foamy macrophages as in grade 1 (Figure 7a) and fatty streaks as in grade 2 (Figure 7b), Some cases showed atheroma with haemorrhage as in grade 6 (Figure 7c) to cases showing calcification as in grade 7 (Figure 7d).

In this study, grade 4 (59.1%) was the more common than grade 3 (30.9%). However in the study by Garg M et al<sup>1</sup> grade 3 (30.9%) was more common than grade 4 (27.3%).

Virmani et al<sup>22</sup> and Stary et al<sup>23</sup> found ruptured plaque as the most common type, but in cases of coronary heart disease grade 4 was the most common (38%). In this study, ruptured plaque was found in 4 cases (8.16%) and calcification in 6 cases (12.2%).

In this study, single vessel involvement was 6.12%, two vessels were involved in 16.3% cases and three vessels

involvement were seen in 24.4%. This was correlated with the study done by Yazdi et al.<sup>24</sup>

No information regarding the risk factors contributing to cardiovascular diseases could be obtained in the cases which were autopsied. This became the major limitation of the study. However the strength of this study lies in grading of occlusion of coronaries and aorta according to modified AHA classification. This classification defines intermediate lesions which are the indicators of future burden of disease. The finding of this study is that almost all the cases were affected to some extent and thereby there is increasing incidence of atherosclerosis in Indians and thus this study proves to be helpful.

## 5. Conclusion

With the cardiovascular disease attaining pandemic proportions, the study of atherosclerosis and its grading is the need of the hour to estimate the disease burden. Preventive measures need to be implemented through National Health Programmes at the earliest in order to control the rising rates.

Autopsy studies play a vital role in unraveling the spectrum and occurrence of atherosclerosis.

## 6. Conflict of Interest

The authors declare no relevant conflicts of interest.

## 7. Source of Funding


None.

## References

- Garg M, Aggarwal A, Kataria S. Coronary Atherosclerosis and myocardial infarction An autopsy study. *J Indian Acad Forensic Med.* 2011;33(1):39–42.
- Thej MJ, Kalyani R, Kiran J. Atherosclerosis in coronary artery and aorta in a semi-urban population by applying modified American Heart Association classification of atherosclerosis: An autopsy study. *J Cardiovasc Dis Res.* 2012;3(4):265–71. doi:10.4103/0975-3583.102692.
- Rao D, Sood D, Pathak P, Dongre SD. Cause of Sudden Cardiac Deaths on Autopsy Findings; a Four-Year Report. *Emergency.* 2014;2(1):12–7.
- Sonawane SY, Matkari PP, Pandit GA. Pathology of heart, coronaries and aorta in autopsy cases with history of sudden death: an original article. *Int J Res Med Sci.* 2017;5(8):3287–91.
- Shanthi B, Saravanan S, Elangovan RS, Sudha V. Sudden Death Causes: An Autopsy Study in Adults. *Int J Sci Stud.* 2016;4(4):176–9. doi:10.17354/ijss/2016/401.
- Roberts JC, Wilkins RH, Moses C. Autopsy studies in atherosclerosis. I. The distribution and severity of atherosclerosis in patients dying without morphologic evidence of atherosclerotic catastrophe. *Circulation.* 1959;20:511–9. doi:10.1161/01.CIR.20.4.520.
- Rao D, Sood D, Pathak P, Dongre SD. Cause of sudden cardiac deaths on autopsy findings; a four-year report. *Emergency.* 2014;2(1):12–7.
- Ahmed S, Begum A, Prabhu MH. Atherosclerosis of Coronary Arteries - An Autopsy Study. *Global J Med Res.* 2013;13(3).
- Shanthi B, Saravanan S, Elangovan RS, Sudha V. Sudden Death Causes: An Autopsy Study in Adults. *Int J Sci Stud.* 2016;4(4):176–9.

10. Sudha ML, Sundaram S, Purushothaman KR, Kumar PS, Pratibha D. Coronary atherosclerosis in sudden cardiac death: An autopsy study. *Indian J Pathol Microbiol.* 2009;52(4):486–9.
11. Abedinzadeh N, Pedram B, Sadeghian Y. A histopathological analysis of the epidemiology of coronary atherosclerosis: an autopsy study. *Diagn Pathol.* 2015;10:87. doi:10.1186/s13000-015-0324-y.
12. Bavelaar FJ, Beynen AC. Atherosclerosis in parrots: a review. *Vet Q.* 2004;26(2):50–60. doi:10.1080/01652176.2004.9695168.
13. Brunkwall J, Mattsson E, Bergqvist D. Diet-induced atherosclerosis in rabbits alters vascular prostacyclin release. *Eicosanoids.* 1992;5:197–202.
14. Fricke C, Schmidt V, Cramer K. Characterization of atherosclerosis by histochemical and immunohistochemical methods in African grey parrots and Amazon parrots. *Avian Dis.* 2009;53(3):466–72. doi:10.1637/8521-111908-Case.1.
15. Centres for Disease Control and Prevention CDC, Racial/ethnic and socioeconomic disparities in multiple risk factors for heart disease and stroke. *MMWR Morb Mortal Wkly.* 2005;54(5):113–7.
16. Galkina E, Ley K. Immune and inflammatory mechanisms of atherosclerosis. *Annu Rev Immunol.* 2009;27:165–97. doi:10.1146/annurev.immunol.021908.132620.
17. Hansson GK, Libby P. The immune response in atherosclerosis: a double-edged sword. *Nat Rev Immunol.* 2006;6(7):508–19. doi:10.1038/nri1882.
18. Silverman S. Diagnostic Imaging. In: Mader D, editor. Reptile Medicine and Surgery. St. Louis: saunders Elsevier; 2006. p. 471489.
19. Willecke F, Yuan C, Oka K, Chan L, Hu Y, Barnhart S, et al. Effects of High Fat Feeding and Diabetes on Regression of Atherosclerosis Induced by Low-Density Lipoprotein Receptor Gene Therapy in LDL Receptor-Deficient Mice. *PLoS One.* 2015;10(6):e0128996. doi:10.1371/journal.pone.0128996.
20. Smith SC, Smith EC, Taylor RL. Susceptibility To Spontaneous Atherosclerosis In Pigeons: An Autosomal Recessive Trait. *J Heredity.* 2001;92(5):439–42. doi:10.1093/jhered/92.5.439.
21. Murthy M, Dutta BN, Ramalingaswami V. Coronary atherosclerosis in North India (Delhi area). *J Pathol Bacteriol.* 1963;85:93–101. doi:10.1002/path.1700850109.
22. Virmani R, Kolodgie FD, Burke AP, Farb A, Schwartz SM. Lessons from sudden coronary death - A comprehensive morphological classification scheme for atherosclerotic lesions. *Arterioscler Thromb Vasc Biol.* 2000;20(5):1262–75. doi:10.1161/01.atv.20.5.1262.
23. Stary HC, Chandler AB, Glagov S, Guyton JR, Insull W, Rosenfeld ME, et al. A definition of initial, fatty streak, and intermediate lesions of atherosclerosis. *Arterioscler Thromb.* 1994;14(5):840–56. doi:10.1161/01.atv.14.5.840.
24. Yazdi SAT, Rezaei A, Azari JB, Hejazi A, Shakeri MT, Shahri MK, et al. Prevalence of Atherosclerotic Plaques in Autopsy Cases with Non cardiac Death. *Iranian J Pathol.* 2009;4(3):101–4.

### Author biography

**Harveen B**, Tutor  <https://orcid.org/0000-0002-9434-4159>

**Vijaya C**, HOD

**Smita M**, Associate Professor

**Cite this article:** Harveen B, Vijaya C, Smita M. Atherosclerosis in coronary arteries and aorta by modified American heart association classification: An autopsy study. *IP Arch Cytol Histopathology Res* 2022;7(2):100-104.