

Content available at: <https://www.ipinnovative.com/open-access-journals>

IP Archives of Cytology and Histopathology Research

Journal homepage: <https://www.achr.co.in/>

## Case Report

# Giant phyllodes tumor of breast with diffuse myxoid changes mimicking low-grade fibromyxoid sarcoma (LGFMS) - A case report

Manasa G.C<sup>1,\*</sup>, Shilpa Singh<sup>1</sup>, Vardendra Kulkarni<sup>1</sup>

<sup>1</sup>Dept. of Pathology, JJM Medical College, Davangere, Karnataka, India



### ARTICLE INFO

#### Article history:

Received 10-08-2022

Accepted 29-08-2022

Available online 23-09-2022

#### Keywords:

Fibroepithelial lesion  
Phyllodes tumor breast  
LGFMS  
MUC4

### ABSTRACT

**Objective:** Phyllodes tumors are biphasic tumors consisting of epithelial and stromal components that account for less than 1% of all breast tumors. Phyllodes tumors are rare that behave in an unpredictable manner and can rarely have diffuse myxoid changes without an exaggerated intracanalicular pattern with leaf like fronds and stromal hypercellularity.

**Case Report:** 50-year old lady with left breast lump, morphologically mimicking low grade fibromyxoid sarcoma was finally diagnosed as recurrent phyllodes tumor (intermediate grade) with extensive myxoid change, based on the previous microscopic finding of phyllodes tumor and excluded diagnosis of low grade fibromyxoid sarcoma by MUC4 stain.

**Conclusion:** Recurrent phyllodes tumor which is a common stromal tumor was diagnosed as LGFMS because of its morphology change resembling, LGFMS which was ruled later out with sensitive and specific marker for LGFMS i.e., MUC4.

This is an Open Access (OA) journal, and articles are distributed under the terms of the [Creative Commons Attribution-NonCommercial-ShareAlike 4.0 License](https://creativecommons.org/licenses/by-nc-sa/4.0/), which allows others to remix, tweak, and build upon the work non-commercially, as long as appropriate credit is given and the new creations are licensed under the identical terms.

For reprints contact: [reprint@ipinnovative.com](mailto:reprint@ipinnovative.com)

## 1. Introduction

Phyllodes tumors (PTs) are uncommon fibroepithelial breast neoplasms, accounts 0.3-1.0% of all primary breast tumors.<sup>1</sup> PTs are common in middle-aged women, average size: 4–7cm and rapid growth.<sup>2</sup> They are composed of stromal and epithelial elements. These tumors graded into 3 categories: Benign, Borderline and malignant and is based on stromal cellularity, atypia, mitotic count, nature of tumor margins and presence of malignant heterologous component.<sup>3</sup> The benign phyllodes tumour show overlapping features with cellular fibroadenoma and the malignant phyllodes tumour may be mistaken for primary breast sarcoma or spindled cell metaplastic carcinoma.<sup>1,4</sup> Thus, diagnosis of PT based on the integration of morphology remains challenging and correlates with prognosis; however, histologic features

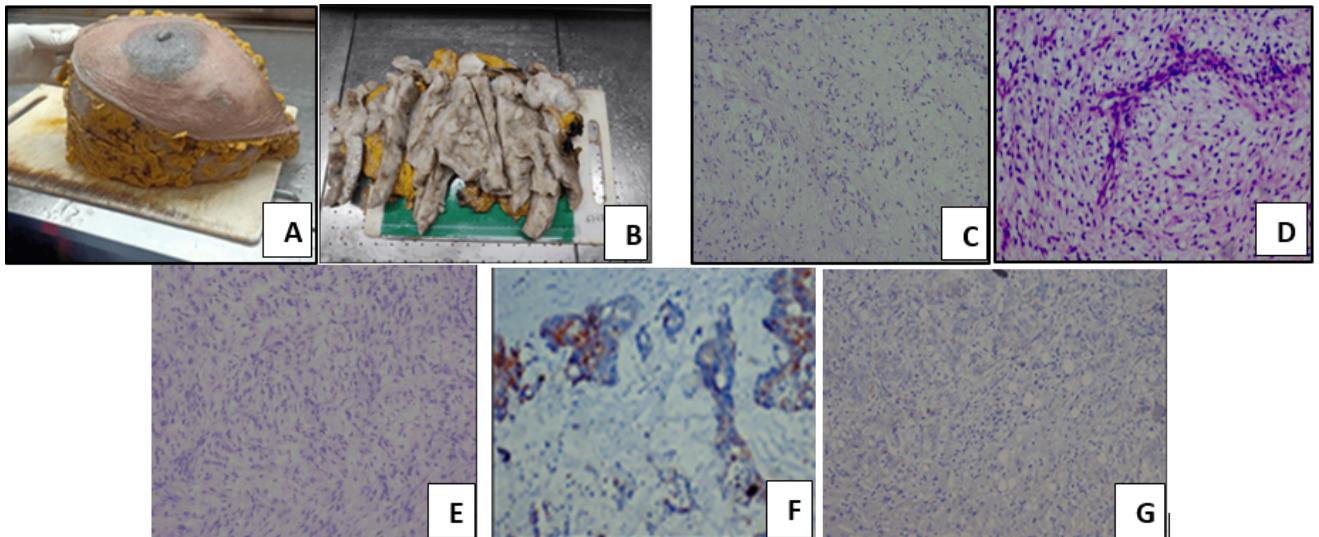
have not always been found to be predictive of clinical behaviour.<sup>1</sup> In this review, we provide a collective stance that can serve as practical guide for pathological reporting and understanding of PTs and emphasizing use of special stain MUC4 for ruling out other differential diagnosis of PTs.

## 2. Case Report

A 50-year woman presented with painful enlargement of left breast since 15 months. Insidious in onset, gradually progressed and associated with pain. On examination: Firm, enlarged and tender. The overlying skin stretched; engorged veins seen. On palpation: Local rise of temperature and tenderness present, size: 25 cm. No palpable axillary lymphadenopathy; laboratory results were normal. Patient had similar complaints diagnosed as phyllodes 1<sup>1/2</sup> year back and operated.

\* Corresponding author.

E-mail address: [manasachandru@gmail.com](mailto:manasachandru@gmail.com) (Manasa G.C).



**Fig. 1:** **A:** On gross Skin and NAC: Unremarkable; **B:** On serial cut-sections: Single grey-white firm lesion with slit like spaces and mucinous area noted; **C:** On (H&E stain x40) sections show tumor composed of spindle cells arranged in hypocellular and hypercellular areas; **D:** On (H&E stain x 40) showing curvilinear blood vessel; **E:** On (H&E stain x40) findings of previous breast lesion shows phyllodes tumor; **F:** On (immunohistochemistry stain x40) MUC 4: control; **G:** On (immunohistochemistry stain x40) MUC4 –Negative.

### 3. CT Chest Report

A large lobulated hypodense lesion measuring 123 x 168 x 157mm in left breast with preserved fat planes, suggestive of benign pathology.

#### 3.1. Gross

Left mastectomy specimen measuring 35x27x15 cm, with overlying skin measuring 25x14 cm. The skin and Nipple areolar complex (NAC): Unremarkable. On serial section single grey -white firm lesion and mucinous area noted measuring 35x21x15cm occupying all four quadrants and all margins appears to be grossly involved. On cut section firm area shows slit like spaces. It is located 0.1cm from the skin and the base.

#### 3.2. Microscopy

Multiple section studied from grey-white areas show tumor composed of spindle cells. The hypercellular areas show swirling whorled pattern of spindle cells with scant cytoplasm and bland nuclei. Hypocellular areas are myxoid with arcades of blood vessels. No atypia or mitotic figures seen. Section studied from grey brown areas shows congested and thrombotic blood vessels and dense inflammatory cells. Morphology in recurrent case mimicking low grade fibromyxoid sarcoma, which was ruled out with sensitive and specific marker MUC4. Previous H& E slides were re-evaluated, showed a biphasic neoplasm composed of epithelial and stromal components.

### 4. Discussion

PT is a biphasic tumor consisting of mesenchymal and epithelial elements, constituting <1% of all breast tumors with incidence of 2.1/1000000.<sup>5</sup>

In the present study radiological features showed large lobulated hypodense lesion measuring approx.123 x 168 x 157 mm seen in left breast, preserved fat planes with underlying pectoralis muscle and similar observation were seen in other studies radiological images.<sup>6</sup>

The natural behaviour of PT is an interesting phenomenon; recurrence rates are high, especially if subjected to incomplete excision, having positive margins/less aggressive surgical treatment. Recurrence may show higher histologic grade with increase mitosis and potential for distant metastasis.<sup>7,8</sup>

Studies have shown 28%-44% of recurrence in benign PT present with higher grades than primary tumour, borderline phyllodes can recur in 14%-25% cases and transformed to malignant in 12%-54%.<sup>7</sup> The atypical changes within stromal component can transform into sarcomatous features.<sup>9</sup> PTs have leaf-like cellular lobulations and biphasic fibro-epithelial constitution, with predominance of stromal elements over epithelial cells.<sup>2</sup> Myxoid change in the stroma tends to be patchy and undergo degenerative changes; focal stromal myxoid change is not uncommon, but tumor composed diffusely of this tissue is very unusual.<sup>10</sup>

In present case, an uncommon histologic variant of giant PT of breast with diffuse myxoid changes has been observed on recurrence of a recurrent PT, mimicking LGFMS, a very rare pattern of sarcomatous transformation. Fibrosarcoma is

the most common pattern of sarcomatous transformation, second being myxoliposarcoma.<sup>9</sup> LGFMS is a rare breast tumour, can arise denovo or as transformation of PTs. LGFMS has bland histological appearance but malignant biological behaviour.<sup>6</sup> The tumour consists of spindle cell resembling fibroblast and includes 2 morphological changes, alternating collagenised hypocellular zones and cell rich myxoid area and arched curvilinear blood vessels.<sup>6</sup> The spindled cells are not heteromorphic and mitotic figures are sparse.<sup>1</sup> Similar morphology was seen in our case.

Differentiation between LGFMS and PT with diffuse myxoid changes was difficult, as both borderline and malignant PTs should be discriminated from rare LGFMS because of collagenized hypocellular zones and myxoid areas.<sup>8</sup> Immunohistochemistry for MUC4, marker for LGFMS was carried out. The LGFMS then ruled out by IHC as MUC4 was negative.

The final diagnosis of recurrent PT (intermediate grade) with extensive myxoid change was given, based on previous and current microscopic findings.

## 5. Conclusion

In summary, PT are rare fibroepithelial neoplasm with potential for local recurrence and distant metastasis. PT show intratumoral morphologic and genetic heterogeneity, which may contribute to unpredictable clinical behaviour and difficulty in classifying them histologically.<sup>1</sup> Recurrent PT which is a common stromal tumor was diagnosed as LGFMS because of its morphology change resembling, LGFMS which was ruled out with sensitive and specific marker i.e., MUC4.

## 6. Acknowledgement

The authors are grateful to acknowledge the immense help of histopathology technician of our department for the high quality histopathological preparations.

## 7. Conflict of Interest

The authors declare no relevant conflicts of interest.


## 8. Source of Funding

None.


## References

- Zhang Y, Kleer CG. Phyllodes Tumor of the Breast: Histologic Features, Differential Diagnosis, and Molecular/Genetic Updates. *Arch Pathol Lab Med.* 2016;140(7):665–71.
- Garlet BB, Zogbi L, Lima D, Favalli JP, Krahefd PPS, Krahe FD, et al. Recurrent borderline phyllodes tumor of the breast submitted to Mastectomy and immediate reconstruction: Case report. *Int J Surg Case Rep.* 2019;60:25–9. doi:10.1016/j.ijscr.2019.05.032.
- Efared B, Ebang GA, Tahiri L, Sidibé IS, Erregad F, Hammas N, et al. Phyllodes tumours of the breast: clinicopathological analysis of 106 cases from a single institution. *Breast Dis.* 2018;37(3):139–45.
- Fajdic J, Gotovac N, Hrgovic Z, Kristek J, Horvat V, Kaufman M, et al. Phyllodes Tumors of the Breast - Diagnostic and Therapeutic Dilemmas. *Onkologie.* 2007;30(3):113–8. doi:10.1159/000099580.
- Hasdemir S, Tolunay Ş, Özşen M, Gökgöz MŞ. Phyllodes Tumor of the Breast: A Evaluation of 55 Cases. *Eur J Breast Health.* 2019;16(1):32–8.
- Zhang Y, Wan D, Gao F. Primary low-grade fibromyxoid sarcoma of the breast: a rare case report with immunohistochemical and fluorescence in situ hybridization detection. *Hum Pathol.* 2018;79:208–11. doi:10.1016/j.humpath.2018.02.013.
- Jabeen D, Vohra LM, Siddiqui T, Raza AUN. Recurrent Phyllodes Tumour of the Breast Transforming to a Fibrosarcoma. *Cureus.* 2020;12(3):1–6. doi:10.7759/cureus.7457.
- Tan PH, Jayabaskar T, Chuah KL, Lee HY, Tan Y, Hilmy M, et al. Phyllodes tumors of the breast: the role of pathologic parameters. *Am J Clin Pathol.* 2005;123(4):529–40.
- Bachleitner-Hoffmann T, Schoppman SF, Rudas M, Birner P, Wiener H, Dubsy P, et al. A case of phyllodes tumor with focal transition into low-grade lymphangiosarcoma. *Breast Care.* 2006;1:391–4. doi:10.1159/000097536.
- Rosen PP. Fibroepithelial neoplasms. In: Rosen's Breast Pathology, 2nd edn. Philadelphia: Lippincott Williams & Wilkins; 2001. p. 163–200.

## Author biography

**Manasa G.C**, Professor  <https://orcid.org/0000-0003-3031-8696>

**Shilpa Singh**, Post Graduate  <https://orcid.org/0000-0003-4080-8293>

**Vardendra Kulkarni**, Professor and HOD  <https://orcid.org/0000-0003-2904-1423>

**Cite this article:** Manasa G.C, Singh S, Kulkarni V. Giant phyllodes tumor of breast with diffuse myxoid changes mimicking low- grade fibromyxoid sarcoma (LGFMS) - A case report. *IP Arch Cytol Histopathology Res* 2022;7(3):192-194.