

Content available at: <https://www.ipinnovative.com/open-access-journals>

IP Archives of Cytology and Histopathology Research

Journal homepage: <https://www.achr.co.in/>

Original Research Article

Use of formalin-alcohol method of cell block preparation in examination of body fluids - An original study

Amrita Neelakantan^{1,*}, Rakesh Patkar¹, Shilpa Mishra¹, Sunil Bhojane¹,
Deeptesh Salvi¹, Sarthak Goriwale¹¹Plus Care Internationals Private Limited, Mumbai, Maharashtra, India

ARTICLE INFO

Article history:

Received 27-08-2022

Accepted 21-10-2022

Available online 30-11-2022

Keywords:

FormalAlcohol method

Cost effectiveness

Cellular Morphology

ABSTRACT

Background: Cell block preparation (paraffin embedding of fluid sediments), is a widely practiced technique. It maintains intact architecture of the tissue and reduces diagnostic errors. Numerous techniques have been followed over the years, but the need for an optimal technique for routine use in laboratory still persists. We propose an alternate, comparatively rapid technique which will not only enable clear visualization of the architectural patterns with maximum preservation of cell morphology, but is also cost effective and easy to perform.

Materials and Methods: We prepared the cell blocks of 20 body fluid samples received in our laboratory. Only fluids with adequate cellularity were included in the study. Each fluid was subjected to two methods, Plasma-Thrombin Method and Formalin-Alcohol Method. The pellets were processed, stained with routine hematoxylin-eosin stain, and additional stains when required, and microscopy was carried out.

Results: Slides prepared from cell blocks were examined for types of pathology- inflammatory, benign, or malignant, cellular architecture, nucleocytoplasmic details, and artifacts. We observed that these features were comparable in both methods. However, the formalin-alcohol method proved superior in terms of cost effectiveness, ease of performance and simplicity of method, as reagents needed were readily available in the laboratory.

Conclusion: Formalin-Alcohol technique of cell block preparation has proven to be a useful and resourceful method on a routine basis, due to its optimal cellular morphological appearance, cost effectiveness and ease of preparation in the laboratory.

This is an Open Access (OA) journal, and articles are distributed under the terms of the [Creative Commons Attribution-NonCommercial-ShareAlike 4.0 License](https://creativecommons.org/licenses/by-nc-sa/4.0/), which allows others to remix, tweak, and build upon the work non-commercially, as long as appropriate credit is given and the new creations are licensed under the identical terms.

For reprints contact: reprint@ipinnovative.com

1. Introduction

Cytology, or Cytopathology, involves examining cells from bodily tissues or fluids to reach a probable or definitive diagnosis. The benefits of this method are that it is less invasive, economical, easy to perform and can yield quicker results, to name a few.

Diagnostic cytopathology incorporates various types of techniques, like aspiration cytology (FNAC), fluid cytology, imprint cytology etc. for determination of diagnosis.

* Corresponding author.

E-mail address: amritaneel@yahoo.co.in (A. Neelakantan).

However, FNAC and other types of cytology have their own drawbacks.

Problems like poor preservation of cellular morphology, poor preservation of architecture, hemorrhagic aspirates, clumping of cells can be a hindrance in diagnosing various lesions, especially malignant ones.

This is where cell block technique comes in handy.

Cell block preparation is a well-known technique in cytological diagnosis, which acts as a bridge between cytology and histopathology. It helps to maintain architectural integrity of the tissue under study, thus aiding visualization of various patterns and morphology. It

also helps in maximum preservation of cellular and nuclear morphology, thus helping in identifying nuclear features optimally.

There is no standardized method currently for preparation of cell blocks, and various methods include plasma-thrombin, Carnoy's method, etc.

Through this study, we aim to propose the Formalin-Alcohol technique which is cost effective, consumes less time and can be performed with reagents which are easily available at the histopathology laboratory.

2. Materials and Methods

We conducted a study intended to compare two techniques of cell block preparation, and shed light on the utility of formalin-alcohol method of cell block preparation.

Our study was conducted over a period of two months, and included 20 samples.

The samples included in our study comprised pleural fluid, pericardial fluid, ascitic fluid and urine.

All samples were subjected to cell block preparation by two methods:

Formalin Alcohol Method and Plasma Thrombin Method.

The methodology has been described in brief below:

2.1. Formalin alcohol method

3-4 ml fluid was centrifuged; supernatant discarded and the sediment mixed with

10% formal-alcohol (90 ml absolute ethanol + 10 ml concentrated formaldehyde).

After standing for 1 hour, a clot was formed which was submitted for processing.

2.2. Plasma thrombin method

3-4 ml fluid was centrifuged; supernatant discarded and the sediment mixed with citrate plasma & thromboplastin in equal amounts.

After shaking well, the clot formed was fixed in neutral buffered formalin for 6 hours and then submitted for processing.

Following automated processing, the slides were stained with H&E stain, and microscopic examination was carried out.

Special stains were performed wherever necessary.

3. Results

The 20 fluids which we processed in our study, spanned over following types and categories Table 1.

The following morphological parameters were studied, and graded as mentioned Table 2.

We observed in our study that of the parameters analyzed, cell blocks prepared by formalin alcohol method

Table 1: Type and category of fluid

Type of fluid Pathological process	Pleural fluid (n=09)	Ascitic fluid (n=06)	Urine (n=03)	Pericardial fluid (n=02)
Inflammatory	03	04	00	02
Benign	02	00	00	00
Malignant	04	02	03	00

n: number of samples

showed superior quality in cellular morphology and nuclear morphology. (Figure 1)

Routine HE staining of the cell block demonstrated a clear distinction between inflammatory, benign, and malignant cells. Staining intensity was also better in cell blocks prepared by the above method. (Figure 1)

Urine cytology in particular showed a distinct improvement.

Pericardial and ascitic fluid examination also revealed similar results. (Figures 2 and 3)

We received pleural fluid cytology of a patient with history of carcinoma breast. Immunohistochemistry was performed on cell block tissue prepared by the formalin-alcohol method, which showed positive staining for ER & PR.(Figure 4)

4. Discussion

Fluid cytology, and cytology in general, is one the oldest, albeit most reliable techniques in the diagnosis of various entities.^{1,2} However, failure rate in this technique is marked, due to reduced cellularity.

Cell block preparation allows for the reduction of this failure rate, by controlling the processing-related artifacts and reducing errors like pressure-induced crush artifacts, clumping due to improper spreading, etc.³ This is because the basic principle behind the cell block is transforming the fluid is transformed into an easily recognizable tissue-like pattern.⁴

Various methods of cell block preparation are available, like The Sodium Alginate Method, The Pregelatinized Starch Method, The Cell-Gel Method and the Histogel Tube Method etc.⁵⁻⁹

Desai et al¹ in their study used the modified alcohol-formalin technique to preserve FNAC samples and to make cell blocks from various cases of head and neck pathologies. Their findings and conclusion were comparable to our study.

Nathan et al.^{4,10} in their study, suggested that formalin, despite being a good tissue fixative, does not preserve the cellular details in a cell block preparation. They used Nathan alcohol formalin substitute and observed a better maintenance of cellular features. Their technique, however, led to a longer processing time than our technique.

In our study, we used the modified formalin-alcohol technique to preserve and process fluid samples. This

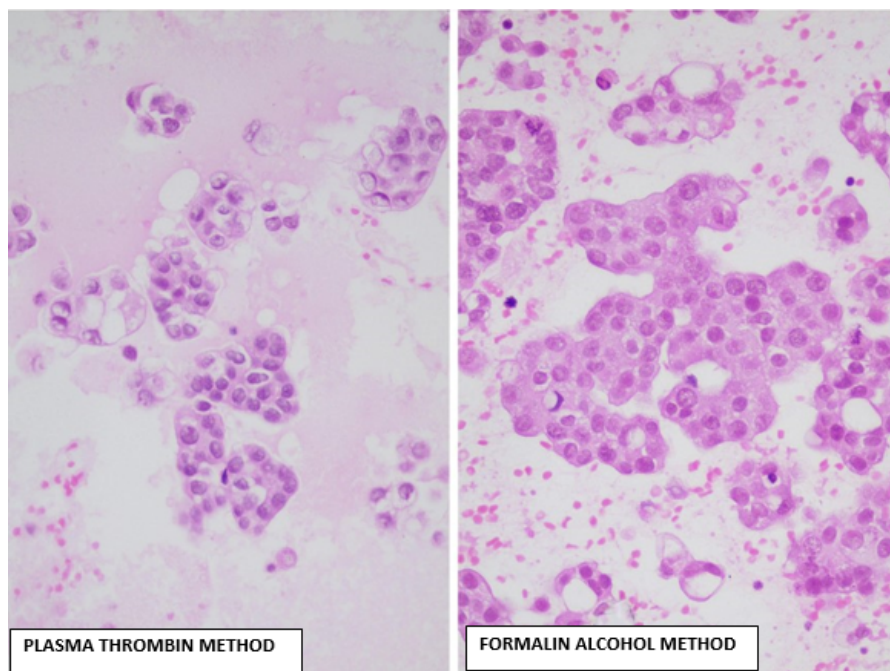


Fig. 1: Comparison of morphology between formalin alcohol v/s plasma thrombinmethod.

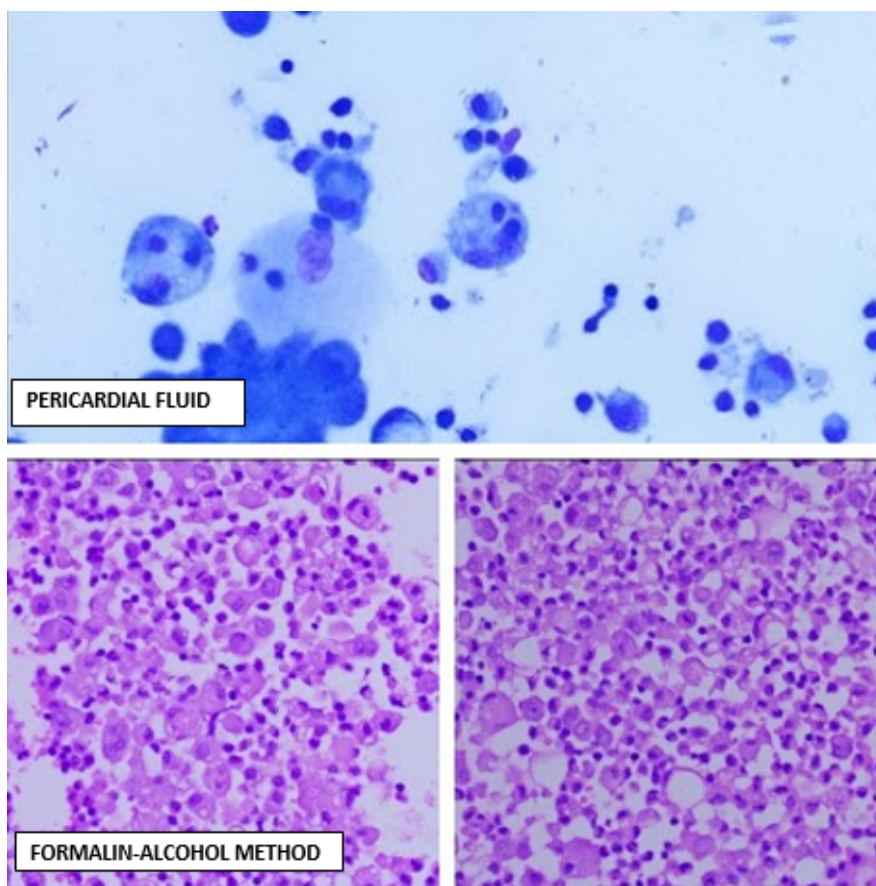


Fig. 2: Pericardial fluid: cytology, FA method, PT method

Table 2: Morphological parameters

Type of fluid	Cellular morphology		Nuclear details		Stain intensity		Artifacts		Special stains/IHC	
	FA method	PT method	FA method	PT method	FA method	PT method	FA method	PT method	FA method	PT method
Pleural fluid (9)	++	++	+++	++	+++	++	+	+	++	++
Ascitic fluid (6)	++	++	+++	++	+++	++	+	+	++	++
Urine (3)	++	+	++	+	+	+	+	+	+	+
Pericardial fluid (2)	++	++	+++	++	+++	++	+	+	++	++

n: number of samples
 FA: Formalin-alcohol method; PT: Plasma Thrombin method; IHC: Immunohistochemistry

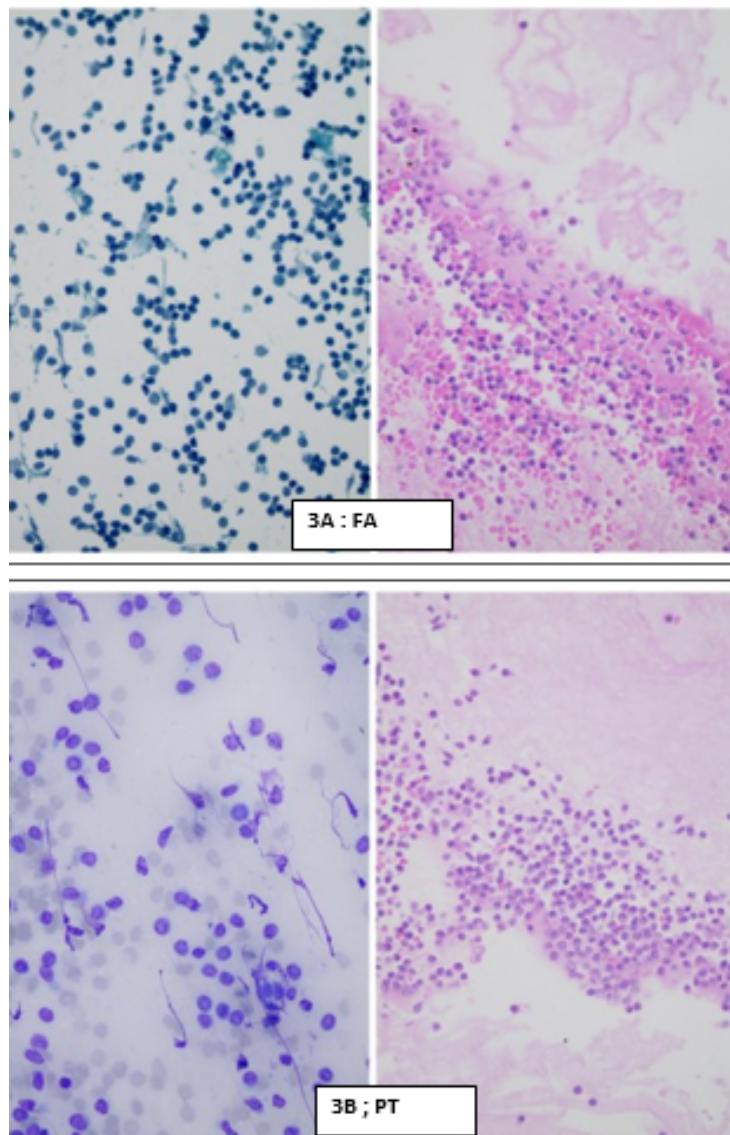


Fig. 3: A&B:Ascitic fluid: cytology, FA method, PT method.

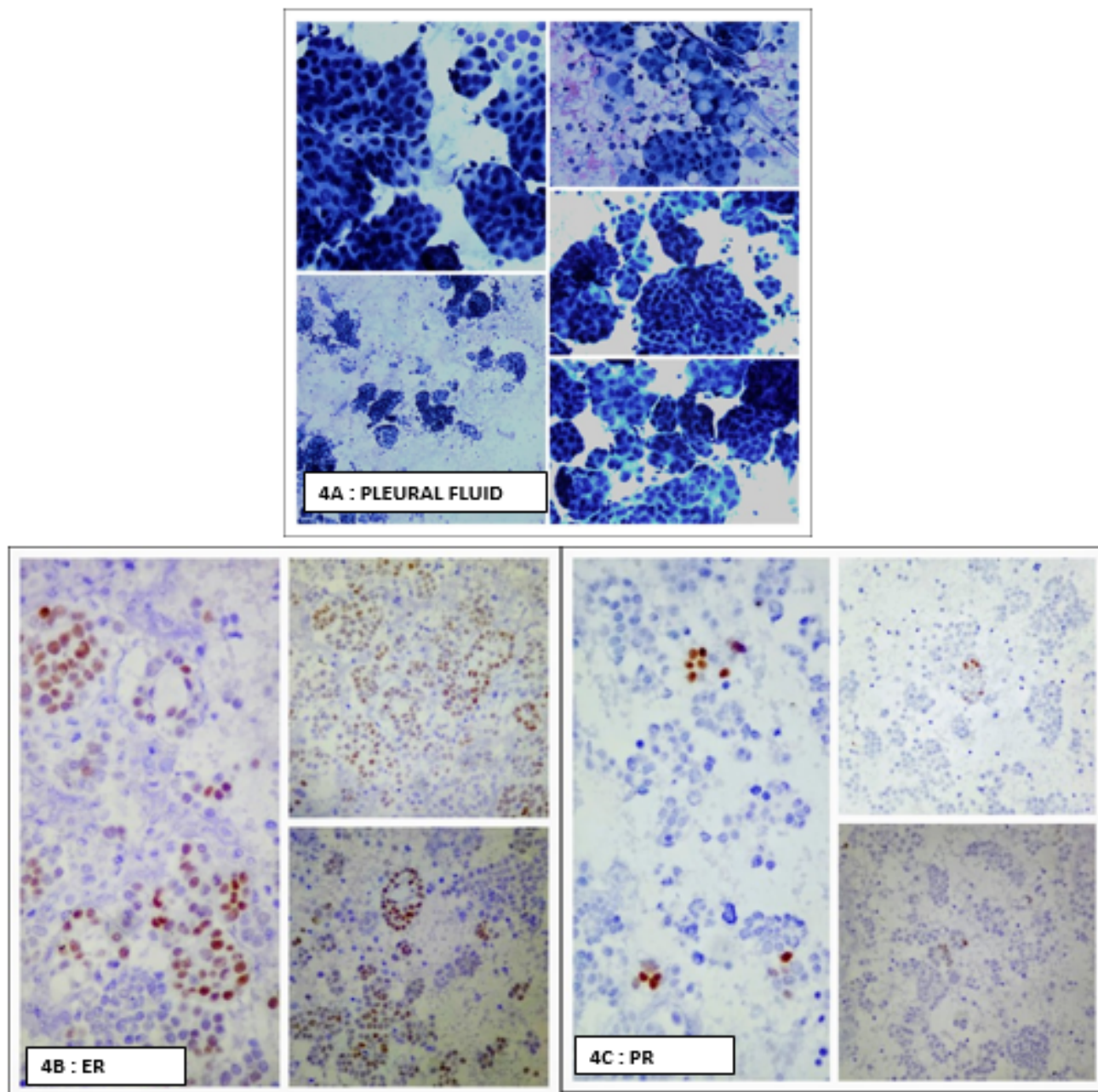


Fig. 4: A,B,C : Pleural fluid: cytology, FA method, PT method

technique is a modification of the 10% alcohol-formalin technique employed by Udasimath et al.⁶ However, our methodology differed from theirs in the way that we limited the use of alcohol and prolonged the fixation time with formalin.

All the samples of ascitic fluid, pericardial fluid and pleural fluid yielded results in favor of Formalin-alcohol method.^{11–14}

In our comparison between the two methods, i.e. formalin-alcohol method and plasma thrombin method, the

observations we made were as follows:

We also observed that for the purpose of immunohistochemistry, formalin alcohol method proved to be a better method, due to superior fixation of tissue.^{15,16}

Thus, the modified formalin-alcohol technique has numerous advantages with a few limitations.

5. Conclusion

Formalin-Alcohol technique of cell block preparation has proven to be a useful and resourceful method on a routine

Table 3: Comparative analysis of both methods

Parameters studied Method used	Cost effectiveness	Time of preparation	Ease of preparation
Formalin - alcohol method	cost per cell block preparation = approx. Rs 6 much more cost effective	time taken for each cell block preparation: approx. 1 hour additional fixation time eliminated	reagents easily available in histopathology lab all around the year
Plasma thrombin method	cost per cell block preparation = approx. Rs 30 less cost effective	time taken for each cell block preparation: approx. 7 hours with fixation	reagents need to be purchased additionally plasma to be sourced or obtained from healthy individual

basis, due to its optimal cellular morphological appearance, cost effectiveness and ease of preparation in the laboratory.

We encourage that cell block preparation be made a routine practice whenever FNAC is indicated, and the formalin-alcohol method is a recommended method for routine use in a histopathology laboratory.

6. Acknowledgements

Mr. Deeptesh Salvi – Laboratory Manager, Plus Care Internationals Private Limited.

Mr. Sunil Bhojane – Senior Technician, Plus Care Internationals Private Limited.

Mr. Sarthak Goriwale – Junior Technician, Plus Care Internationals Private Limited.

7. Source of Funding

None.

8. Conflicts of Interest

There is no conflict of interest.

References

- Desai KM, Angadi PV, Kale AD, Hallikerimath S. Modified alcohol-formalin cell block technique in head and neck pathology diagnosis. *Acta Cytologica*. 2018;62(1):39–43.
- Koss LG. Scope and sampling techniques in diagnostic cytology. In: *Diagnostic Cytology and Its Histopathologic Bases*. vol. 1. Philadelphia: J.B. Lippincott; p. 1–9.
- Orell SR. Pitfalls in fine needle aspiration cytology. *Cytopathology*. 2003;14(4):173–82. doi:10.1046/j.1365-2303.2003.00078.x.
- Nathan N, Narayan E, Smith M, Horn M. Improved preparation and its efficacy in diagnostic cytology. *Am J Clin Pathol*. 2000;114(4):599–606. doi:10.1309/G035-P2MM-D1TM-T5QE.
- Krogerus L, Kholová I. Cell block in cytological diagnostics: review of preparatory techniques. *Acta Cytol*. 2018;62(4):237–43. doi:10.1159/000489769.
- Udasimath S, Arakeril S, Karigowdar M, Telikar B. The role of the cell block method in the diagnosis of malignant ascitic fluid effusions. *J Clin Diagn Res*. 2012;6(7):1280–3.
- Velios F, Griffin J. Examination of body fluids for tumors cells. *Am J Clin Pathol*. 1954;24(6):676–81. doi:10.1093/ajcp/24.6.676.
- Musso C, Silva-Santos M, Pereira FEL. Cotton block method: one-step method of cell block preparation after fine needle aspiration. *Acta*

Cytol. 2005;49(1):22–6. doi:10.1159/000326090.

- Zanoni D, Grandi F, Cagnini D, Bosco S, Rocha N. Agarose cell block technique as a complementary method in the diagnosis of fungal osteomyelitis in a dog. *Open Vet J*. 2012;2(1):19–22. doi:10.5455/OVJ.2012.v2.i0.p19.
- Shobha SN, Kodandaswamy CR. Utility of modified cell block technique in cases of pleural effusion suspected for malignancy. *Int J Health Sci Res*. 2013;3(1):32–8.
- Bahrenburg L. On the diagnostic results of the microscopical examination of the ascitic fluid in two cases of carcinoma involving the peritoneum. *Cleveland Med Gaz*. 1986;11:274–8.
- Chapman CB, Whalen EJ. The examination of serous fluids by the cell-block technic. *N Engl J Med*. 1947;237(7):215–20. doi:10.1056/NEJM194708142370702.
- Zhao J, Lin DL, Zhai LH, Wang JG. Evaluation of ultrasound-processed rapid cell blocks in the cytopathologic diagnosis of cavity fluids. *Acta Cytol*. 2014;58(2):182–91. doi:10.1159/000357658.
- Lindsey KG, Houser PM, Shotsberger-Gray W, Chajewski OS, Yang J. Young investigator challenge: a novel, simple method for cell block preparation, implementation, and use over 2 years. *Cancer Cytopathol*. 2016;124(12):885–92. doi:10.1002/cncy.21795.
- Martins D, Beca F, Schmitt F. Metastatic breast cancer: mechanisms and opportunities for cytology. *Cytopathology*. 2014;25(4):225–230. doi:10.1111/cyt.12158.
- Domagala WM, Markiewski M, Tuziak T, Kram A, Weber K, Osborn M, et al. Immunocytochemistry on fine needle aspirates in paraffin miniblocks. *Acta Cytol*. 1990;34(3):291–6.

Author biography

Amrita Neelakantan, Pathologist

Rakesh Patkar, HOD and Laboratory Director

Shilpa Mishra, Consultant Pathologist

Sunil Bhojane, Senior Technician

Deeptesh Salvi, Laboratory Manager and Senior Technician

Sarthak Goriwale, Junior Technician

Cite this article: Neelakantan A, Patkar R, Mishra S, Bhojane S, Salvi D, Goriwale S. Use of formalin-alcohol method of cell block preparation in examination of body fluids - An original study. *IP Arch Cytol Histopathology Res* 2022;7(4):214–219.