

Content available at: <https://www.ipinnovative.com/open-access-journals>

IP Archives of Cytology and Histopathology Research

Journal homepage: <https://www.achr.co.in/>

## Original Research Article

## Importance of P16ink4a marker in oral neoplasms

Uma Rani Pallivilla<sup>1</sup>, Gudeli Vahini<sup>1,\*</sup>, Anjana Priyanka Aluri<sup>1</sup>,  
Rajendra Prasad Jalagam<sup>1</sup><sup>1</sup>Dept. of Pathology, Alluri Sitaramaraju Academy of Medical Sciences, Malkapuram, Andhra Pradesh, India

## ARTICLE INFO

## Article history:

Received 30-11-2022

Accepted 06-12-2022

Available online 11-03-2023

## Keywords:

Oral

Squamous

Neoplasm

## ABSTRACT

**Context:** We have increase in number of oral lesions at ASRAMS, as it is a referral centre and there by we have determined to study the prevalence of these lesions and its association with P16ink4a marker.**Aims and Objectives:** The purpose of this study is to evaluate the role of P16ink4a in oral epithelial dysplasias and oral squamous cell carcinoma by immunohistochemistry.**Settings:** In clinically significant patients, correlation between histopathology findings and its association with P16ink4a marker has been studied in Department of Pathology, ASRAMS.**Study design:** A retrospective study done from July 2017 to July 2019.**Materials and Methods:** The study was carried out after approval of the Institutional Ethics Committee. The biological material received was resection specimen and punch biopsies of the lesion which was fixed in 10% formalin for 6hrs later processed, followed by paraffin embedding and hematoxylin & eosin staining of the sections. Histopathological classification of lesions was done according to the criteria proposed by WHO for oral cavity lesions.

Immunohistochemical analysis with P16ink4a was performed on the serial sections. Development of reactions was performed with DAB (Diamino benzidine). The panel used was clone E6H4, requiring no dilution followed by epitope retrieval solution.

**Statistical analysis:** All data were tabulated in a Windows Excel spreadsheet (Microsoft Excel 2011) and statistically analyzed using software version. The expression of P16ink4a in various lesions was tabulated.**Results:** The study included 29 cases of oral lesions, most of them belonged to age group of 40 to 60 yrs. Male preponderance is noted. Most of the cases in our study were located on tongue. Histopathologically well differentiated squamous cell carcinomas were more in number. The immunoeexpression of p16 stain was present at nuclear and cytoplasmic level mainly found at the basal dysplastic epithelium. P16 had a weak intensity at level of tumor proper and also at invasion front.**Conclusion:** P16ink4a immunohistochemical marker can be used as a surrogate biomarker for HPV detection of oral epithelial dysplasias and oral squamous cell carcinomas. P16 is useful marker in identifying dysplastic lesions and decrease of its immunoeexpression is a predictive factor notified for neoplastic transformation.This is an Open Access (OA) journal, and articles are distributed under the terms of the [Creative Commons Attribution-NonCommercial-ShareAlike 4.0 License](https://creativecommons.org/licenses/by-nc-sa/4.0/), which allows others to remix, tweak, and build upon the work non-commercially, as long as appropriate credit is given and the new creations are licensed under the identical terms.For reprints contact: [reprint@ipinnovative.com](mailto:reprint@ipinnovative.com)

## 1. Introduction

P16ink4a IHC marker is a surrogate marker for HPV infection and the expression of P16ink4a in association

with HPV-High risk infection has been observed.<sup>1-3</sup> HPV associated tumors have been credited with a better clinical outcome and favorable prognosis.<sup>1,2</sup> Hence, HPV detection in Oral squamous cell carcinoma gains importance.

It has been observed that the cases of oropharyngeal carcinoma associated with active HPV-DNA may need

\* Corresponding author.

E-mail address: [gudelivahini@gmail.com](mailto:gudelivahini@gmail.com) (G. Vahini).

deintensified regimens, which reduces the long term negative impact of treatment. Such cases may be singled out by IHC detection of P16ink4a.<sup>3</sup>

The early oncogenes of HPV mainly E6 and E7 play a key role in carcinogenesis through inactivation of p53 and retinoblastoma(pRb).<sup>1,4-6</sup> E7-E2F complex effectively stops the negative feedback action of pRb on p16, there by resulting in over-expression of p16.<sup>1,4,7</sup> This causes deregulation of cell cycle, thus facilitating DNA damage leading to cellular transformation.

Further, it has been observed that P16ink4a is a strong independent prognostic indicator.<sup>3,7</sup> It also shows high sensitivity and specificity towards HPV detection. Oral cancers have multiple etiological factors and the major contributing factors include tobacco and alcohol intake.<sup>7</sup>

**2. Aims and Objectives**

1. The present study was aimed to assess the immunohistochemical expression of p16 in oral lesions such as high grade dysplasia, squamous papilloma and oral squamous cell carcinoma, epitheliomatous hyperplasia and irritable fibroma.
2. To correlate the patterns of P16 expression with respect to different grades of oral squamous cell carcinomas.

**3. Materials and Methods**

Formalin fixed paraffin embedded (FFPE) tissue blocks of 29 histologically proven cases of oral lesions, including normal mucosa as a control. The cases were retrieved from the archives of Department of pathology. Clinicopathological data of all cases were taken from the patient records and tabulated. The study was carried out after approval of the Institutional Ethics Committee.

Tissue sections of 4 μm were obtained on silane coated slides and subjected to IHC staining. Immunohistochemical analysis with anti-human P16ink4a was performed on the serial sections. The panel used was clone MX007. The procedure provided by the manufacturer was followed for staining. Brown precipitate in the nucleus/cytoplasm/both were considered to be a positive p16 expression.

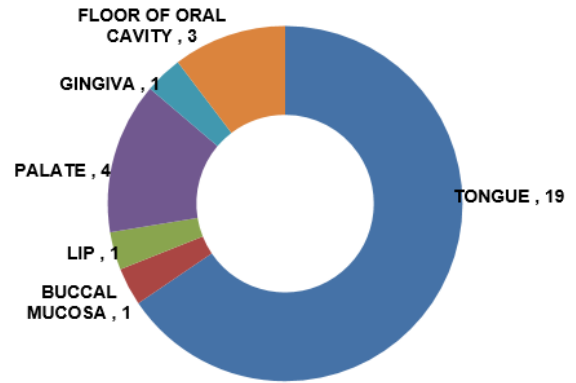
Parameters such as percentage positivity, pattern of expression, intensity and layers of epithelium showing positive staining were assessed. Number of positive cells (x) in an evenly stained area under 40x magnification was counted in each slide. The intensity was scored as absent, mild or intense.

**4. Results**

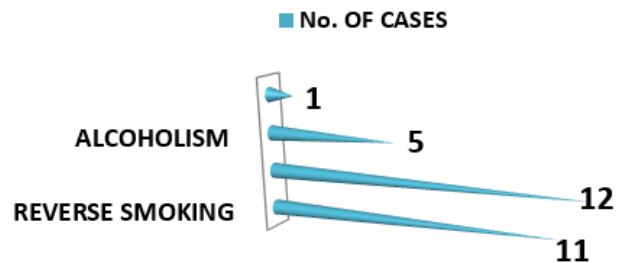
The result was found mainly at the basal, parabasal cells and sometimes entire epithelium. The reaction was also identified in normal fibroblasts, glandular acini and endothelial cells.

**Table 1:** Distribution of cases

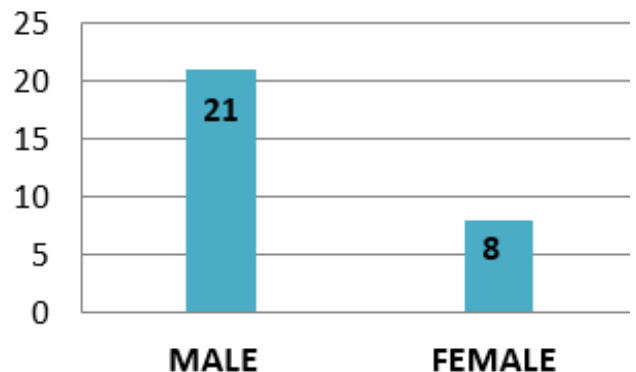
D istribution of cases	N umber of cases
Squamous cell carcinoma	19
Severe dysplasia	1
Squamous papilloma	3
Irritable fibroma	1
Epithelial hyperplasia	1
Leukoplakia	1
Gingival hyperplasia	1
Nonspecific ulcer	2



**Fig. 1:** Distribution basing on location of the lesion.



**Fig. 2:** Risk factors



**Fig. 3:** Male: female ratio

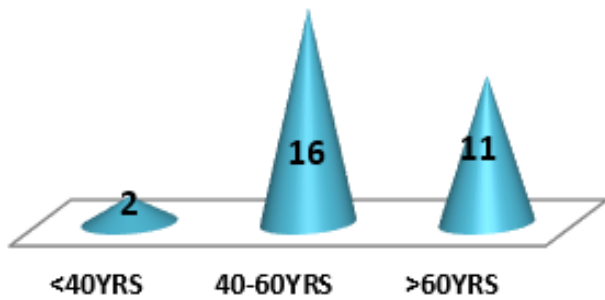


Fig. 4: Age distribution

Table 2: Comparison of IHC expression of p16 among groups

Parameters	No. o f cases
<b>% Positivity</b>	
0-30%	15
31-60%	5
61-90%	8
>90%	1
<b>Pattern</b>	
Nuclear	3
Cytoplasm	5
Both	10
Negative	11
<b>Intensity</b>	
Mild	17
Dense	1

No correlation was seen between the expression of P16 and localization of the lesion, age, gender or grading.

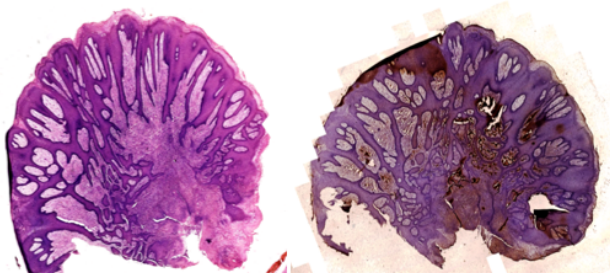


Fig. 5: 10959/18,scanner view, squamous papilloma

5. Discussion

The etiology of oral cancers is multifactorial and a sequential process. Highest incidence of oral squamous cell cancers is also associated with the habit of reverse smoking, and chewing tobacco. Several factors involving oral carcinogenesis are age, gender, lifestyle, genetic background and status of health.<sup>2</sup>

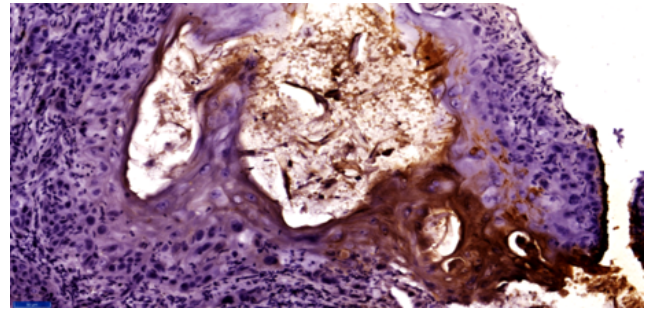


Fig. 6: 2150/17, 10x view Focal strong positivity in severe dysplasia, Buccal mucosa

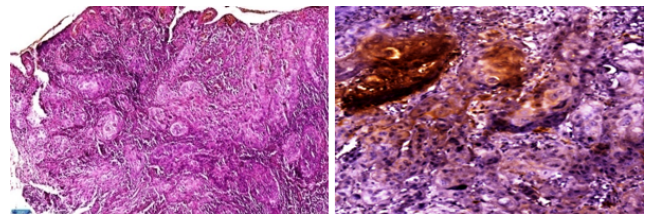


Fig. 7: 435/19, scanner view focal strong positivity of P16 in well differentiated squamous cell carcinoma, Tongue

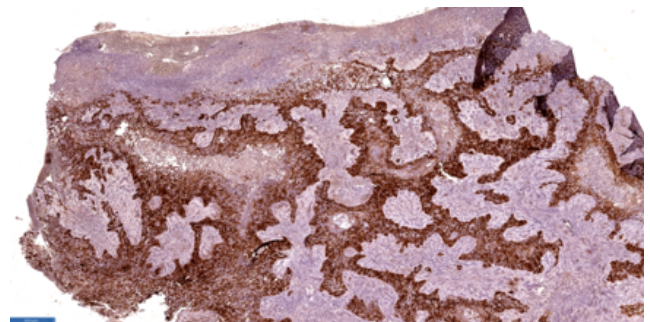


Fig. 8: 1300/17, SCANNER VIEW Diffuse strong positive P16 ink4a marker in squamous cell carcinoma grade 2, tongue

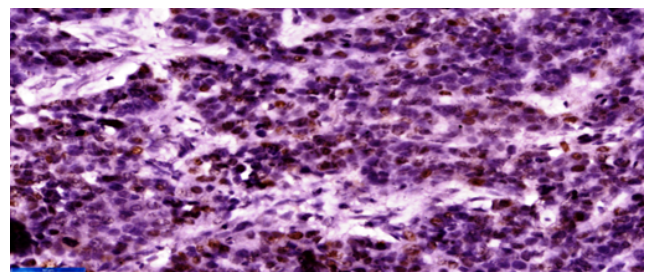
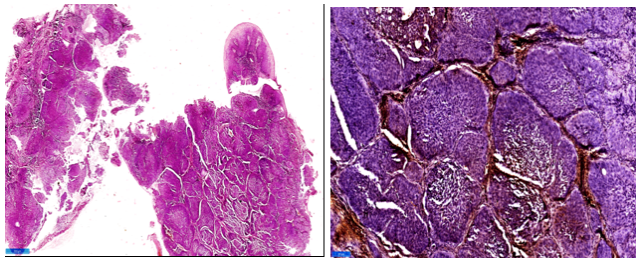


Fig. 9: 9918/18, 10xview, Nuclear positivity of P16INKa in poorly differentiated Squamous cell carcinoma



**Fig. 10:** 6737/8, Scanner view, basaloid variant of squamous cell carcinoma – negative for P16INK4A

The prognosis of P16ink4a marker has been reported to be better, irrespective of histologic grade. However, it was observed that no single pattern of expression was strongly associated with the marker. As we have not linked with HPV DNA analysis in the oral lesions, it is not possible for us to comment on the association of HPV in Oral SCC.

**Table 3:** Correlation with other studies

Clinico-morphological parameters	Parameter	Prensent study	Pradyot prakash et al study	LP Dragomir etal study
Age	<40	2	24	4
	40-60	16	48	21
	>60	11	18	9
Sex	Male	21	75	29
	Female	8	15	5
Risk factors	Smoking	23	-	11
	Alcohol	5	-	4
	Family H/O	1	-	1
	Other associations	-	-	18
	Localization	Tongue	19	31
	Palate	4	5	2
	Others	6	54	21
Degree of differentiation (malignant lesions)	Well differentiated	11	53	18
	Moderately differentiated	5	14	12
	Poorly differentiated	3	2	4
P16 marker positivity	Positive	18	61	22
	Negative	11	29	12

## 6. Conclusion

1. The present study demonstrates the importance of over-expression of P16ink4a marker in oral squamous lesions.
2. P16ink4a immunohistochemical marker can be used as a surrogate biomarker for HPV detection of

oral epithelial dysplasia's and oral squamous cell carcinomas.

3. However, HPV DNA detection is required to validate the utility of IHC detection of P16ink4a as a surrogate marker for HPV association.

## 7. Conflict of Interest

None.

## 8. Source of Funding

None.

## References

1. Mork J, Lie AK, Glatre E, Hallmans G, Jellum E, Koskela P, et al. Human papillomavirus infection as a risk factor for squamous-cell carcinoma of the head and neck. *N Engl J Med.* 2001;344(15):1125–31. doi:10.1056/NEJM200104123441503.
2. Syrjänen K, Syrjänen S, Lamberg M, Pyrhönen S, Nuutinen J. Morphological and immunohistochemical evidence suggesting human papillomavirus (HPV) involvement in oral squamous cell carcinogenesis. *Int J Oral Surg.* 1983;12(6):418–24. doi:10.1016/s0300-9785(83)80033-7.
3. Rischin D, Young RJ, Fisher R, Fox SB, Le QT, Peters LJ, et al. Prognostic significance of p16INK4A and human papillomavirus in patients with oropharyngeal cancer treated on TROG 02.02 phase III trial. *J Clin Oncol.* 2010;28(27):4142–8. doi:10.1200/JCO.2010.29.2904.
4. Ndiaye C, Mena M, Alemany L, Arbyn M, Castellsagué X, Laporte L, et al. HPV DNA, E6/E7 mRNA, and p16INK4a detection in head and neck cancers: A systematic review and meta-analysis. *Lancet Oncol.* 2014;15(12):1319–31. doi:10.1016/S1470-2045(14)70471-1.
5. Bouda M, Gorgoulis VG, Kastrinakis NG, Giannoudis A, Tsoli E, Danassi-Afentaki D, et al. High risk HPV types are frequently detected in potentially malignant and malignant oral lesions, but not in normal oral mucosa. *Mod Pathol.* 2000;13(6):644–53. doi:10.1038/modpathol.3880113.
6. Ang KK, Harris J, Wheeler R, Weber R, Rosenthal DI, Nguyen-Tân PF, et al. Human papillomavirus and survival of patients with oropharyngeal cancer. *N Engl J Med.* 2010;363(1):24–35. doi:10.1056/NEJMoa0912217.
7. Ang KK, Harris J, Wheeler R, Weber R, Rosenthal DI, Nguyen-Tân PF, et al. Human papillomavirus and survival of patients with oropharyngeal cancer. *N Engl J Med.* 2010;363(1):24–35. doi:10.1056/NEJMoa0912217.

## Author biography

**Uma Rani Pallivilla**, Professor

**Gudeli Vahini**, Professor  <https://orcid.org/0000-0002-2112-3515>

**Anjana Priyanka Aluri**, Associate Professor

**Rajendra Prasad Jalagam**, Professor and HOD

**Cite this article:** Pallivilla UR, Vahini G, Aluri AP, Jalagam RP. Importance of P16ink4a marker in oral neoplasms. *IP Arch Cytol Histopathology Res* 2023;8(1):10-13.