

Content available at: <https://www.ipinnovative.com/open-access-journals>

IP Archives of Cytology and Histopathology Research

Journal homepage: <https://www.achr.co.in/>

Original Research Article

Role of fine needle aspiration cytology in the diagnosis of cutaneous and subcutaneous swellings

Chhavi Gupta^{1,*}, Rajat Gupta¹, Subhash Bhardwaj¹¹Dept. of Pathology, Government Medical College, Jammu, Jammu & Kashmir, India

ARTICLE INFO

Article history:

Received 27-07-2022

Accepted 09-08-2022

Available online 11-03-2023

Keywords:

Cytology

Cutaneous

Subcutaneous

ABSTRACT

Background: A wide range of inflammatory as well as neoplastic lesions can present as cutaneous and subcutaneous swellings all over the body. FNAC (Fine Needle Aspiration Cytology) is considered to be the first reliable technique for diagnosing them.

Aims and Objectives: To assess the cytological spectrum of lesions presenting as skin and subcutaneous swellings.

Materials and Methods: It was an observational study conducted in the Department of Pathology, Govt. Medical College, Jammu. FNAC was performed on patients presenting with palpable skin and subcutaneous swellings. May-Grunwald-Giemsa (MGG) and Papanicolaou (PAP) stained smears were examined under light microscope. The cytological features were studied and diagnosis was made.

Results: The present study had 290 patients which included 169 (58%) males and 121 (42%) females. On FNA examination, 111 (38.3%) were non-neoplastic and 179 (61.7%) were neoplastic. Epidermal inclusion cyst was the most common non- neoplastic lesion. Among neoplastic lesions, 166 cases (57.2%) were benign and 13 cases (4.5%) were malignant. Lipoma was the most common benign neoplastic lesion and was also overall the commonest lesion in our study. Metastatic carcinoma cases were maximum among malignant lesions.

Conclusion: Fine Needle Aspiration Cytology is a rapid, reliable technique for initial assessment of cutaneous and subcutaneous swellings and thereby guiding further management.

This is an Open Access (OA) journal, and articles are distributed under the terms of the [Creative Commons Attribution-NonCommercial-ShareAlike 4.0 License](https://creativecommons.org/licenses/by-nc-sa/4.0/), which allows others to remix, tweak, and build upon the work non-commercially, as long as appropriate credit is given and the new creations are licensed under the identical terms.

For reprints contact: reprint@ipinnovative.com

1. Introduction

A wide range of inflammatory as well as neoplastic lesions can present as cutaneous and subcutaneous swellings all over the body.^{1,2} Fine needle aspiration (FNA) is a simple, fast, and inexpensive technique with high sensitivity and specificity in the evaluation of these masses.³ It can be effectively employed to diagnose nature of lesion, helps to distinguish between neoplastic and reactive process likely to resolve spontaneously or with conservative treatment.⁴⁻⁶ It helps to diagnose infections presenting as skin nodules.⁷ FNAC is of great value in the investigation of suspected

skin and subcutaneous metastatic malignancy.⁶ The present study was carried out with the aim to assess the cytological spectrum of lesions presenting as skin and subcutaneous swellings.

2. Materials and Methods

It was an observational study conducted in the Department of Pathology, Govt. Medical College, Jammu w.e.f. 1st January 2022 to 30th June 2022. It included patients presenting with palpable skin and subcutaneous swellings referred from various clinical departments. Detailed history, clinical examination and relevant investigations of all patients were recorded. FNAC was performed using 22

* Corresponding author.

E-mail address: guptachhavi919@gmail.com (C. Gupta).

G needle and 20cc syringe after taking written informed consent. Smears were prepared; air dried smears were stained with May-Grunwald-Giemsa (MGG) stain and alcohol fixed smears were stained with Papanicolaou (PAP) stain. Stained smears were examined under light microscope. The cytological features were studied and diagnosis was made. Aspirates showing only peripheral blood or with low cellularity were considered unsatisfactory for evaluation and were excluded from the study.

3. Results

The present study had 290 patients which included 169 (58%) males and 121 (42%) females with male to female ratio of 1.4:1. The mean age of patients was 36.17 years with age ranging from 6 months to 85 years. The age wise distribution of cases is as shown in Table 1. Maximum cases were in the age group 31-40 years followed by 21-30 years.

Table 1: Age wise distribution of cases

Age (years)	Non-neoplastic	Neoplastic (Benign)	Neoplastic (Malignant)	Total
0-10	11	7	-	18
11-20	23	13	-	36
21-30	24	38	-	62
31-40	21	49	3	73
41-50	17	31	2	50
51-60	10	12	1	23
61-70	5	13	4	22
71-80	-	2	3	5
81-90	-	1	-	1
Total	111	166	13	290

Out of 290 cases, 111 (38.3%) were diagnosed as non-neoplastic and 179 (61.7%) as neoplastic on FNA examination (Table 2). The inflammatory lesions were acute suppurative inflammation (21 cases), tubercular abscess (6 cases) and granulomatous inflammation (1 case). Epidermal inclusion cyst was the most common non-neoplastic lesion (Figure 1). Among neoplastic lesions, 166 cases (57.2%) were benign and 13 cases (4.5%) were malignant. Lipoma was the most common benign neoplastic lesion and was also overall the commonest lesion in our study (137, 47.2%) (Figure 2). Benign appendageal tumors seen were pilomatricoma, chondroid syringioma. Metastatic carcinoma were adenocarcinoma (2 cases) (Figure 3), squamous cell carcinoma (2cases) (Figure 4) and poorly differentiated carcinoma (1case). Of these, adenocarcinoma deposits were seen in abdominal wall, squamous cell carcinoma in chest wall and head, neck region; and poorly differentiated carcinoma deposits were seen in chest wall.

Trunk was involved in 132 cases (45.5%) followed by head and neck (96 cases, 33.1%), upper extremity (42 cases, 14.5%) and lower extremity (20 cases, 6.9%). Trunk was the most common site for benign neoplastic lesions and non-neoplastic inflammatory lesions. Head and neck region was

the most common site for epidermal inclusion cysts, benign cystic lesions, vascular tumors and benign appendageal tumors.

Table 2: Various lesions diagnosed on FNA

Cytological diagnosis	Number of cases	Percentage (%)
Non-neoplastic		
Inflammatory	28	9.6
Benign cystic lesion	11	3.8
Ganglion cyst	05	1.7
Epidermal inclusion cyst	63	21.7
Endometriosis	01	0.3
Hematoma	02	0.7
Gouty tophus	01	0.3
Neoplastic		
Benign		
Lipoma	137	47.2
Neurofibroma	02	0.7
Benign spindle cell lesion	03	1.0
Benign appendageal tumor	14	4.8
Hemangioma	06	2.1
Giant cell tumor of tendon sheath	04	1.4
Malignant		
Metastatic carcinoma	05	1.7
Squamous cell carcinoma	01	0.3
Poorly differentiated carcinoma	01	0.3
Basal cell carcinoma	01	0.3
Malignant melanoma	02	0.7
Malignant spindle cell lesion	02	0.7
Malignant appendageal tumor	01	0.3
Total	290	100.0

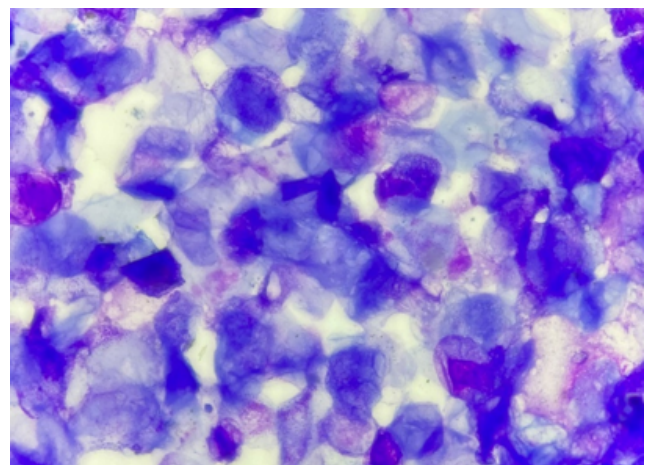


Fig. 1: Photomicrograph from a case of epidermal inclusion cyst showing numerous anucleated squamous epithelial cells (MGG, 400X)

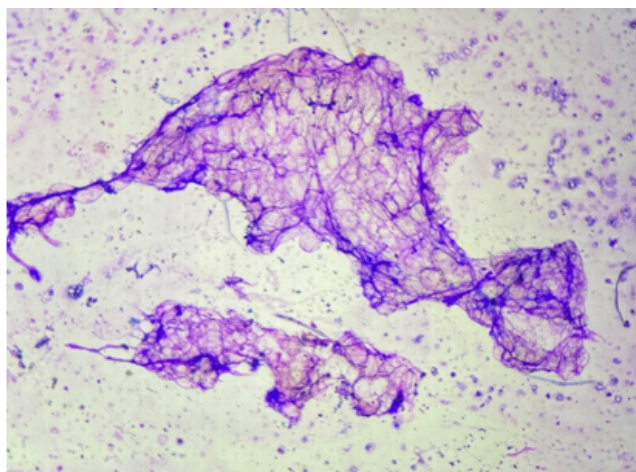


Fig. 2: Photomicrograph from a case of lipoma showing fragments of mature adipose tissue (MGG, 100X)

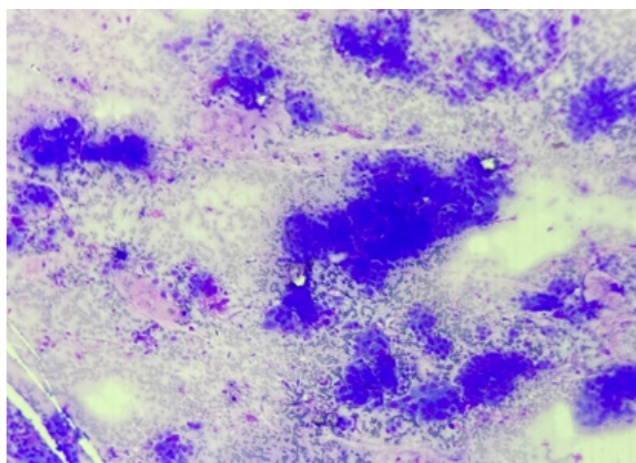


Fig. 3: Photomicrograph showing metastatic deposits of adenocarcinoma (MGG 100X)

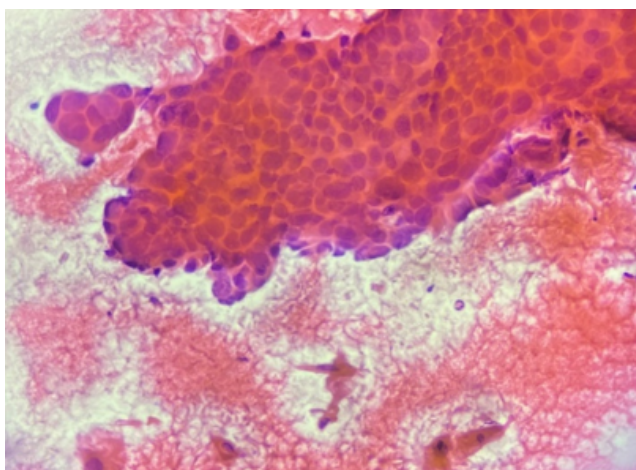


Fig. 4: Photomicrograph showing metastatic deposits of squamous cell carcinoma (PAP 400X)

4. Discussion

A total of 290 cases were cytologically assessed in the present study. There were 169 (58%) males and 121 (42%) females with male to female ratio of 1.4:1. This male preponderance in our study is similar to other studies.^{5,7-9} Maximum cases in our study were in the age group of 21-40 years which is comparable to other studies.^{1,5}

Epidermal inclusion cyst was the most common non neoplastic lesion as seen in many studies.^{1,5,7-11} Inflammatory lesions were the next commonest among non neoplastic lesions, also seen in other studies.^{7,10,11} Lipoma accounted for maximum cases in our study and is also the commonest benign neoplastic lesion diagnosed in our study. This was also observed in studies by other authors.^{1,5,7-12} In our study, next common among benign neoplastic lesions were benign appendageal tumors; similar to few studies.^{8,12} However, in some studies, benign spindle cell lesions were the second common benign neoplastic lesion.^{1,10}

Metastatic carcinoma cases were highest among the malignant lesions, comparable to study by Gupta et al.⁵ Squamous cell carcinoma cases were overall highest among the malignant lesions. Squamous cell carcinoma was the most common malignant tumor in studies by Dash et al and Bode et al.^{8,9} Skin primary malignancy and metastasis both can present as a nodule. Though most of the cutaneous metastases occur in patients with known primary, they may rarely be the first manifestation of an unknown primary.^{13,14} There were 5 cases of metastatic carcinoma in our study. Primary site of origin was known in 3 cases i.e. two from lung and one from gastrointestinal tract.

Trunk was the commonest site of metastasis (chest wall – 2 cases and abdominal wall - 2 cases) followed by head and neck region (1 case). Both chest wall metastasis were from lung. One abdominal wall metastatic deposit was from gastrointestinal tract. Lung and breast cancer commonly metastasize to the chest wall. The abdominal wall is a favored site for the primary from the gastrointestinal tract.¹⁵ This was also observed in our study.

A wide spectrum of skin and subcutaneous lesions have been diagnosed on FNA in our study. Though lesions like spindle cell lesions, appendageal tumors and some malignant lesions further require biopsy for confirmation and categorization, FNA is an effective tool in the initial evaluation of skin and subcutaneous swellings as highlighted by other studies available in the literature.

5. Conclusion

Fine Needle Aspiration Cytology is a rapid, reliable technique for initial assessment of cutaneous and subcutaneous swellings and thereby guiding further management.

6. Source of Funding

None.


7. Conflict of Interest

None.

References

- Nayak GD, Raman S. Cytological spectrum of subcutaneous nodules, a 3 year study. *Indian J Pathol Oncol.* 2020;7(3):452–7.
- Soni S, Mardi K. Diagnostic utility of fine needle aspiration cytology in the evaluation of neoplastic cutaneous nodular lesions: experience from tertiary care institute. *Int J Res Med Sci.* 2020;8(11):3928–33. doi:10.18203/2320-6012.ijrms20204880.
- Spitz DJ, Reddy V, Selvaggi SM, Kluskens L, Green L, Gattuso P, et al. Fine needle aspiration of scalp lesions. *Diagn Cytopathol.* 2000;23(1):35–8.
- Marwah N, Rana S, Jain P, Gupta S, Marwah S, Sen R, et al. A Fine Needle Aspiration Study of the Abdominal Cutaneous and Subcutaneous Nodules. *Iranian J Pathol.* 2013;8(2):97–103.
- Gupta R, Gupta R, Dewan D, Mahajan S, Singh P. Fine needle aspiration cytology as a diagnostic tool in nodular skin lesions. *Int J Med Sci Public Health.* 2016;5(6):1229–32.
- Orell S, Sterrett GF. Skin and Subcutis. In: Orell S, Sterrett G, editors. *Orell & Sterrett's Fine Needle Aspiration Cytology.* RELX India Private Limited; 2012. p. 370–86.
- Chhadi T, Chhadi S. Study of cytodiagnosis of cutaneous and subcutaneous lesions. *Global J Res Anal.* 2018;7(10):13–5.
- Dash AK, Mohanty S, Tripathy M, Silal S. Role of FNAC in the Diagnosis of Skin and Subcutaneous Lesions: A 3 Years Prospective Study. *Int J Med Res Prof.* 2019;5(3):272–9.
- Bode A, Gadkari R. Study of cytodiagnosis of cutaneous and subcutaneous lesions: Experience in a Tertiary Care Hospital. *J Med Sci Clin Res.* 2017;5(4):20377–82.
- Bhowmik A, Sinha MM, Barman DC. Role of Fine Needle Aspiration Cytology in the Diagnosis of Skin and Superficial Soft Tissue Lesions: A Study of 510 Cases. *Turk J Pathol.* 2015;31(3):200–5.
- Jain M, Kasliwal N, Pachori G, Jethani N. FNAC as reliable preoperative diagnostic test in nodular skin lesions. *Int J Med Res Prof.* 2015;1(3):15–9.
- Gupta R, Sharma N, Raman S. Cytohistological and immunohistochemical correlation of cutaneous neoplastic lesions: Three year retrospective study. *IP Arch Cytol Histopathology Res.* 2022;7(1):32–41.
- Karki S, Pathak R, Manandhar U, Koirala S. Metastatic cutaneous and subcutaneous lesions: Analysis of cases diagnosed on fine needle aspiration cytology. *J Pathol Nepal.* 2011;1(1):37–40. doi:10.3126/jpn.v1i1.4449.
- Nair N, Chikkannaiah P, Venkataramanappa S, Shivanna R. Utility of fineÑneedle aspiration cytology in diagnosis of cutaneous and subcutaneous metastasis. *Acta Med Int.* 2021;8(1):57–61. doi:10.4103/amit.amit_8_21.
- Handa U, Kundu R, Dimri K. Cutaneous Metastasis: A Study of 138 Cases Diagnosed by Fine-Needle Aspiration Cytology. *Acta Cytol.* 2017;61(1):47–54. doi:10.1159/000453252.

Author biography

Chhavi Gupta, Senior Resident  <https://orcid.org/0000-0001-6556-7903>

Rajat Gupta, Associate Professor

Subhash Bhardwaj, Professor

Cite this article: Gupta C, Gupta R, Bhardwaj S. Role of fine needle aspiration cytology in the diagnosis of cutaneous and subcutaneous swellings. *IP Arch Cytol Histopathology Res* 2023;8(1):40–43.