

Content available at: <https://www.ipinnovative.com/open-access-journals>

IP Archives of Cytology and Histopathology Research

Journal homepage: <https://www.achr.co.in/>

Short Communication

Urethral rhinosporidiosis – A case report

Maruti A Dhakane¹, Vandana Gite¹, Ankita Majumder^{1,*}

¹Dept. of Pathology, Apollo Hospital, Bilaspur, Chhattisgarh, India



ARTICLE INFO

Article history:

Received 18-01-2023

Accepted 28-02-2023

Available online 11-03-2023

Keywords:

Urethra

Rhinosporidiosis

Sporangia

ABSTRACT

Rhinosporidiosis is an infectious disease caused by *Rhinosporidium seeberi*, an aquatic protistan parasite. It usually affects the nasal mucosa. Extranasal locations are reported limitedly in medical literatures. Here, we present a case report of an isolated urethral rhinosporidiosis, quite a rare entity, with mode of presentation and management in brief.

This is an Open Access (OA) journal, and articles are distributed under the terms of the [Creative Commons Attribution-NonCommercial-ShareAlike 4.0 License](https://creativecommons.org/licenses/by-nc-sa/4.0/), which allows others to remix, tweak, and build upon the work non-commercially, as long as appropriate credit is given and the new creations are licensed under the identical terms.

For reprints contact: reprint@ipinnovative.com

1. Introduction

Rhinosporidiosis caused by *Rhinosporidium seeberi*, first reported by Guillermo Seeberi in 1900 and the lifecycle described by Ashworth in 1923.¹ It is a chronic disease prevalent in tropical areas, especially southern Indian states, Sri Lanka and Pakistan usually in farmers or agricultural labourers. It frequently involves the nasal passages, and infection at other sites, like ocular tissues, lip, urethra, larynx, rectum, and skin, although rare, has been reported.

2. Case Report

32-year-old young male farmer from rural central India presented with a three months history of a painless urethral growth and hematuria in the surgical out-patient department. On clinical examination, a fleshy reddish polypoidal growth is seen protruding through external urethral meatus near navicular fossa; measuring 4.0 x 2.5 cm. Routine hematological and biochemical investigations were within normal limits. Urine analysis revealed increased pus cells and urine culture showed no growth. The urethral growth was resected under spinal anesthesia and received for histopathological examination. Routine

H&E stain revealed polypoidal mass lined by urothelium with foci of squamous metaplasia and subepithelial stroma with numerous thick walled cysts containing mature and immature sporangia with plenty endospores of *Rhinosporidiosis*. Dense inflammation comprising of neutrophils, lymphocytes and plasma cells were observed within the stroma. Special stains (PAS & GMS) confirmed final diagnosis of urethral rhinosporidiosis. Subsequently, a cystourethroscopy was performed that revealed a normal lower urinary tract. Patient is on Dapsone post-operatively to prevent recurrence.

3. Discussion

Urethral rhinosporidiosis is a rare entity and may be misdiagnosed as mucocele, hemangioma, condylomata or penile cancer.² Men in second to fourth decades are most susceptible. The infection spreads mostly by the local inoculation due to traumatic breach in the epithelial lining. Contaminated stagnant water bodies bath and soil work are the prime sources for infection. Bathing and cleaning in stagnant waterbodies leads to abrasions and contamination by the organisms. Hematuria, polypoidal growth from external urethral meatus, discharge and intermittent bleeding are the usual presenting signs and

* Corresponding author.

E-mail address: drankitapath@gmail.com (A. Majumder).

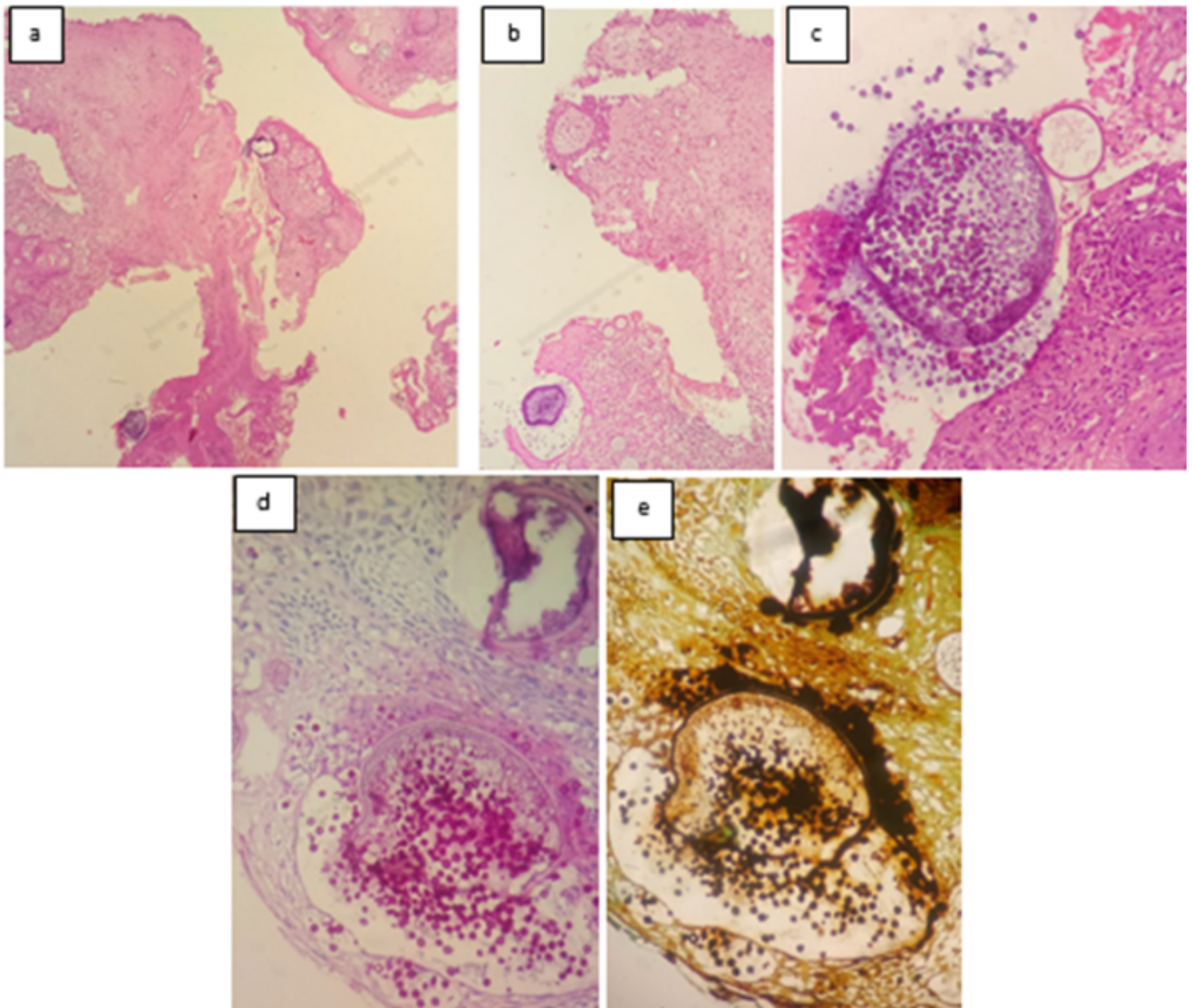


Fig. 1: Sporangia at different stages containing endospores of *Rhinosporidium seeberi* and chitinous wall within urothelium; **a & b:** H&E stain; **c & d:** PAS stain; **e:** GMS stain.

symptoms. The definitive diagnosis of Rhinosporidiosis is to be made by histopathology with the identification of multiple sporangia in various stages of maturity, enclosed in a thin chitinous wall, rather than the stromal and cellular responses of the host.³ The sporangia and endospores stain positively with various special stains like PAS, mucicarmine, Gomori's methenamine-silver, Grocott's stain etc and aid in the final diagnosis as used in present case report. Treatment of rhinosporidial lesions is mainly surgical. Brisk bleeding occurs often following surgical removal, and care must be taken so that all the polypoid masses are removed to ensure no recurrence. Recurrence may occur due to spillage of endospores in the surrounding mucosa during removal.⁴ The only drug to have anti-rhinosporidial effect is dapsone, but it can only be used as

an adjuvant to surgery. Dapsone has also been reported to reduce the recurrence rate in 70% of cases. Multiple lesions extending along the penile urethra often pose a problem, as transurethral excision and electrocoagulation may lead to urethral stricture formation. Electrocoagulation at the time of excision along with local infiltration of the site with amphotericin B also reduces the risk of recurrence.⁵ Rhinosporidiosis is neither contagious nor transmissible through sexual contacts.⁶

Rhinosporidiosis is a potentially curable infectious condition, which can behave in an aggressive manner if left untreated. Although rare, Correct diagnosis and necessary treatment needs to be ensured to prevent recurrence in cases of urethral rhinosporidiosis.

4. Conflict of Interest

None.

5. Source of Funding

None.

References

1. Karunaratne WA. Rhinosporidiosis in man. London: Athlone Press; 1964. p. 14–8.
2. Ravi R, Mallikarjuna VS, Chaturvedi HK. Rhinosporidiosis mimicking penile malignancy. *Urol Int.* 1992;49(4):224–6. doi:10.1159/000282433.
3. De Silva N, Huegel H, Atapattu DN. Cell-mediated immune responses in human Rhinosporidiosis. *Mycopathologia.* 2001;152(2):59–8.
4. Sasidharan K, Subramonian P, Moni VN, Aravindan KP, Chally R. Urethral rhinosporidiosis. Analysis of 27 cases. *Br J.* 1987;59(1):66–9. doi:10.1111/j.1464-410x.1987.tb04582.x.
5. Job A, Venkateswaran S, Mathan M, Krishnaswami H, Raman R. Medical therapy of rhinosporidiosis with dapsone. *J Laryngol Otol.*


1993;107(9):809–12. doi:10.1017/s002221510012448x.

6. Arseculeratne SN, Sumathipala S, Eriyagama NB. Patterns of rhinosporidiosis in Sri Lanka: Comparison with international data. *Southeast Asian J Trop Med Public Health.* 2010;41(1):175–91.

Author biography

Maruti A Dhakane, Consultant and HOD

Vandana Gite, Consultant  <https://orcid.org/0000-0002-5590-1506>

Ankita Majumder, Consultant Pathologist  <https://orcid.org/0000-0002-9707-174X>

Cite this article: Dhakane MA, Gite V, Majumder A. Urethral rhinosporidiosis – A case report. *IP Arch Cytol Histopathology Res* 2023;8(1):70-72.