

Content available at: <https://www.ipinnovative.com/open-access-journals>

IP Archives of Cytology and Histopathology Research

Journal homepage: <https://www.achr.co.in/>

## Original Research Article

## Revisitation of thyroid lesions in natives from hilly region: A four years perspective

Brijesh Thakur<sup>1,\*</sup>, Jyotsna Bhateja<sup>1</sup>, Sanjay Kaushik<sup>1</sup>, Seema Acharya<sup>1</sup><sup>1</sup>Dept. of Pathology, Shri Guru Ram Rai Institute Of Medical & Health Science, Dehradun, Uttarakhand, India

## ARTICLE INFO

## Article history:

Received 25-07-2023

Accepted 27-09-2023

Available online 30-10-2023

## Keywords:

FNAC

goitre

imaging

papillary carcinoma

thyroid

## ABSTRACT

**Background:** Clinically palpable thyroid nodules pose a challenge in diagnosis and management for surgeons and pathologists as thyroid malignancies may show overlapping characteristics with their benign counterparts in terms of physical characteristics, hormonal levels and imaging details. This study was aimed to revisit the spectrum of thyroid lesions in surgically resected specimens, their clinicopathological characteristics and to compare the cytological and imaging findings in discrepant cases.

**Material and Methods:** The present retrospective study retrieved a total of 69 cases of thyroid resection specimens with available relevant demographic, clinicoradiological and cytological findings. The histopathological diagnosis was considered gold standard.

**Results:** Colloid goitre (37.7%) and papillary carcinoma (17.4%) were found to be the commonest non-neoplastic and neoplastic lesions respectively. Peak incidence in 20–40 years of age group and M:F ratio of 1:3.6 in overall thyroid disorders was noted. 08 discrepant cases were observed while comparing histological diagnosis with radiological and/or cytological findings.

**Conclusion:** Histopathological diagnoses were in agreement with imaging findings and/or FNAC results in most of the cases, however, patients with indeterminate or suspicious FNAC results, need to be followed-up for early surgical intervention if required.

This is an Open Access (OA) journal, and articles are distributed under the terms of the [Creative Commons Attribution-NonCommercial-ShareAlike 4.0 License](https://creativecommons.org/licenses/by-nc-sa/4.0/), which allows others to remix, tweak, and build upon the work non-commercially, as long as appropriate credit is given and the new creations are licensed under the identical terms.

For reprints contact: [reprint@ipinnovative.com](mailto:reprint@ipinnovative.com)

## 1. Introduction

Thyroid gland enlargement is fairly encountered in clinical practice and comprises a spectrum of disorders varying from developmental to inflammatory to hyperplastic to neoplastic conditions. Clinically palpable thyroid nodules pose a challenge in diagnosis and management for surgeons and pathologists as thyroid malignancies may show overlapping characteristics with their benign counterparts in terms of physical characteristics, hormonal levels and imaging details. Fine needle aspiration cytology (FNAC) is considered a first line standard diagnostic test for the evaluation of thyroid swellings.<sup>1,2</sup> However, in patients with indeterminate FNAC results, histological examination of

surgically excised specimens is the only way to differentiate between benign and malignant thyroid lesions.

The present analysis is aimed to evaluate the spectrum of thyroid lesions in surgically resected specimens, their clinicopathological characteristics and to compare the cytological and imaging findings in discrepant cases.

## 2. Materials and Methods

The present retrospective study retrieved a total of 69 cases of thyroid resection specimens from departmental archives after taking approval from Institutional Ethical Committee. Types of specimen include lobectomy, hemithyroidectomy, subtotal and near as well as total thyroidectomy which were submitted to the histopathology section for last 04 years. Relevant demographic, clinical details, radiological and

\* Corresponding author.

E-mail address: [drbrijeshthakur03@gmail.com](mailto:drbrijeshthakur03@gmail.com) (B. Thakur).

cytological findings were retrieved from the departmental archive records wherever possible.

The specimens were received in 10% neutral buffered formalin and grossed as per standard laboratory protocol. Sections of 3-5 microns were prepared from paraffin-embedded blocks using embedding station (Leica EG1150 H+C) and stained with Haematoxylin & Eosin. The final histopathological diagnosis was considered gold standard for comparative analysis.

### 3. Results

Out of included 69 cases, 54 were female patients and 15 were male patients with a male to female (M:F) ratio of 1:3.6. The age of included patients ranged from 07 years to 78 years with a mean age of 41 years. Only 03 cases (02 males and 01 female) were of less than 20 years of age at the time of presentation and none of them revealed a neoplastic lesion on histopathological examination. A maximum number (35/69, 50.7%) of patients (neoplastic as well as non-neoplastic lesions) was noted in the 20-40 years of age group. The most frequent presenting symptom in our study was neck swelling (65/69, 94.2%) followed by pressure symptoms (9/69, 13%) and neck pain (2/69, 2.9%). Most common sites include left lobe alone (29% cases) and diffuse thyroid involvement (27.5%). [Table 1]

Total thyroidectomy (32/69, 46.4%) was the commonest type of specimen followed by hemithyroidectomy (17/69, 24.6%), lobectomy (8/69, 11.6%) and near-total thyroidectomy (3/69, 4.4%). Lymph node dissection was done in 13 cases of total thyroidectomy specimens. On histopathology, majority of the cases were diagnosed as non-neoplastic (48/69, 69.6%). Various non-neoplastic disorders and their frequencies were tabulated according to age and sex in Table 2. Rest of the 21 cases (30.4%) was reported as neoplastic and out of these, 15 cases were diagnosed as malignant. Papillary thyroid carcinoma was the most common malignant lesion among these cases (12/69, 17.4%). [Table 2]

08 cases where discrepancy was noted between histological diagnosis and radiological and / or cytological examination. [Table 3]

### 4. Discussion

The incidence of thyroid solitary nodules is more common among adults in the general population.<sup>3</sup> Similar to our experience, previous studies also reported that thyroid swellings were 3 to 4 times more common in women as compared to men.<sup>4,5</sup> The most common presenting complaint was neck swelling similar to observations found by Chetan et al.<sup>5</sup> Commonest age group of thyroid disorders (non-neoplastic as well as neoplastic) was 20-40 years of age group in our study, similar to other authors as well.<sup>2,5,6</sup> In contrast, Joseph et al. observed maximum

number of thyroid lesions in 40-50 years of age group.<sup>7</sup> We did not observe specific predilection of any thyroid lobe involvement; almost equal number of cases were noticed involving left (20,29%), right (18,26.1%) and both lobes (19,27.5%). However, few investigators noticed right lobe preponderance in their study.<sup>2,6</sup>

In the present study, radiological findings were available for total 59 cases (suggestive of non-neoplastic / multinodular goiter in 43 patients and of neoplastic origin in 16 cases) and histological diagnoses were in agreement with imaging findings in most of the cases (concordance rate 91.5%), more or less similar to some previous studies.<sup>2,6</sup>

Cytology is of utmost importance in thyroid lesions as it can exclude the unnecessary surgeries in non-neoplastic lesion. In our study, FNAC was done in 66 cases, while in 03 cases surgical intervention without any known precedent aspiration cytology was done. Out of those 66 cases, 49 cases (74.2%) were diagnosed as non-neoplastic and 17 cases (25.8%) as neoplastic; out of which 14 (82.4%) were reported as malignant on cytology. Surgical intervention is required for thyroid swellings if there is suspicion or evidence of malignancy on aspiration smears. So all those cases where cytological or clinical suspicion was present were subjected to surgery and the most common surgery performed was total thyroidectomy (27.5%) followed by hemithyroidectomy (24.6%). Previous studies also support our data suggesting that the most common surgery performed for thyroid swellings is total thyroidectomy.<sup>8</sup>

Histopathological results displayed that colloid goitre (Figure 1a) was the most frequent disorder in our experience (26/69, 37.7%), similar to a few previous studies.<sup>5,9-11</sup> Sailaja et al. and Gurbani et al. also observed colloid goiter being most frequent disorder followed by thyroiditis (Figure 1 b&c) and hyperplastic nodule similar to our results.<sup>11,12</sup> The most common neoplastic lesion diagnosed in our study was papillary thyroid carcinoma (12/69, 17.4%) followed by Hurthle cell neoplasm including single case of Hurthle cell carcinoma (3/69, 4.3%), two cases each of non-invasive follicular thyroid neoplasm with papillary like nuclear features (NIFTP) and follicular adenoma, single case each of follicular carcinoma and medullary carcinoma. (Figure 2) In contrast, some authors observed follicular adenoma as the commonest neoplastic lesion diagnosed,<sup>2,5</sup> however, in some studies papillary carcinoma was reported as most frequent thyroid neoplasm even predominating over benign adenomas similar to our results.<sup>12-14</sup> 06 cases revealed lymph node metastasis, all of them were cases of papillary thyroid carcinoma.

In the present study, all those cases reported definitive malignant (Bethesda TBSRTC category VI) on FNAC were finally diagnosed the same on histopathology (100% concordance rate); similar to a study done by Waseer MH et al.<sup>15</sup> The cytology reports correlated with the

**Table 1:** Comparative analysis of various clinicoradiological & pathological findings in thyroid disorders according to sex

characteristics		Non-neoplastic		Neoplastic	
		M	F	M	F
Age (years)	<20	02	01	00	00
	20-40	03	20	03	09
	41-60	05	14	00	04
	>60	01	02	01	04
Clinical features	Neck swelling	09	36	03	17
	Neck pain	00	01	00	01
	Pressure symptoms	00	05	01	03
	Right lobe	03	07	03	05
Site	Left lobe	01	12	00	07
	Isthmus	01	01	00	01
	Diffuse	01	13	01	04
	NOS	05	02	00	00
Radiology		12	31	02	14
FNAC		12	37	04	13
	Lobectomy	01	05	00	02
	Hemithyroidectomy	01	15	00	01
	TT	02	09	01	07
Specimen type	Near TT	00	03	00	00
	TT & LND	01	03	03	06
	Isthmectomy	01	00	00	01
	Excision	05	02	00	00
HPE Diagnosis		11	37	04	17

Abbreviations- TT- Total thyroidectomy, LNM-Lymph node metastasis

**Table 2:** Tabulated results of final histological diagnoses in various thyroid disorders according to sex & age groups

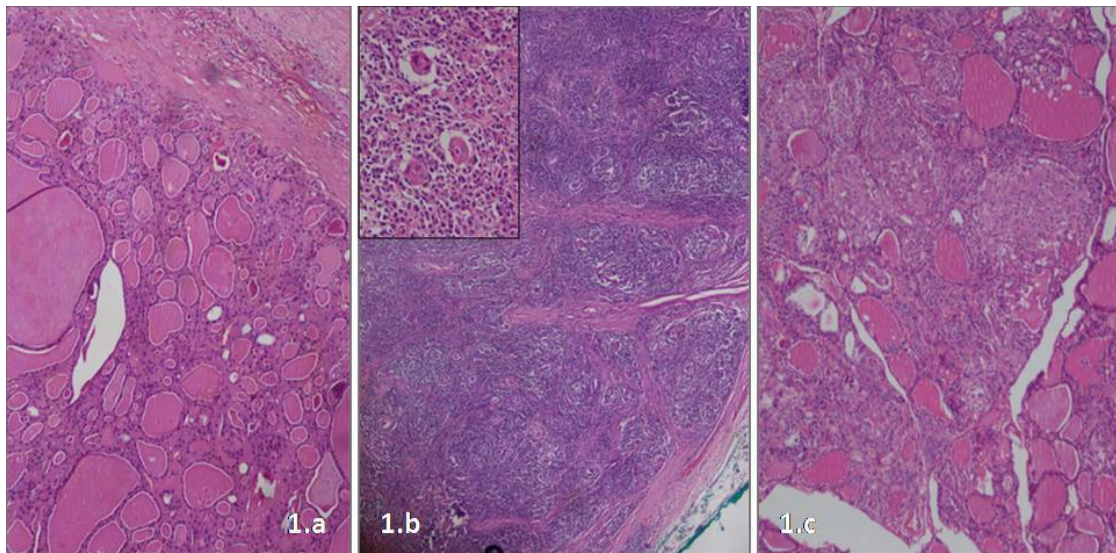
HPE Diagnoses	M	F	<20 yr	20-40 yr	41-60 yr	>60 yr
Colloid Goitre	05	20	00	18	06	01
Adenomatous nodule	00	06	00	04	02	00
Thyroiditis	01	03	00	00	03	01
Goitre + Thyroiditis	00	07	00	02	05	00
Thyroglossal cyst	05	01	03	01	01	01
Follicular adenoma	00	02	00	02	00	00
NIFTP	00	02	00	00	02	00
Follicular carcinoma	00	01	00	01	00	00
Papillary carcinoma	02	10	00	08	01	03
HCA	01	01	00	01	01	00
Hurthle cell carcinoma	00	01	00	00	00	01
Medullary carcinoma	01	00	00	00	00	01
LN Metastasis	02	04	00	05	00	01

Abbreviations- yr- years; Non-invasive follicular thyroid neoplasm with papillary like nuclear features (NIFTP); HCA- Hurthle cell adenoma; LNM-Lymph node metastasis

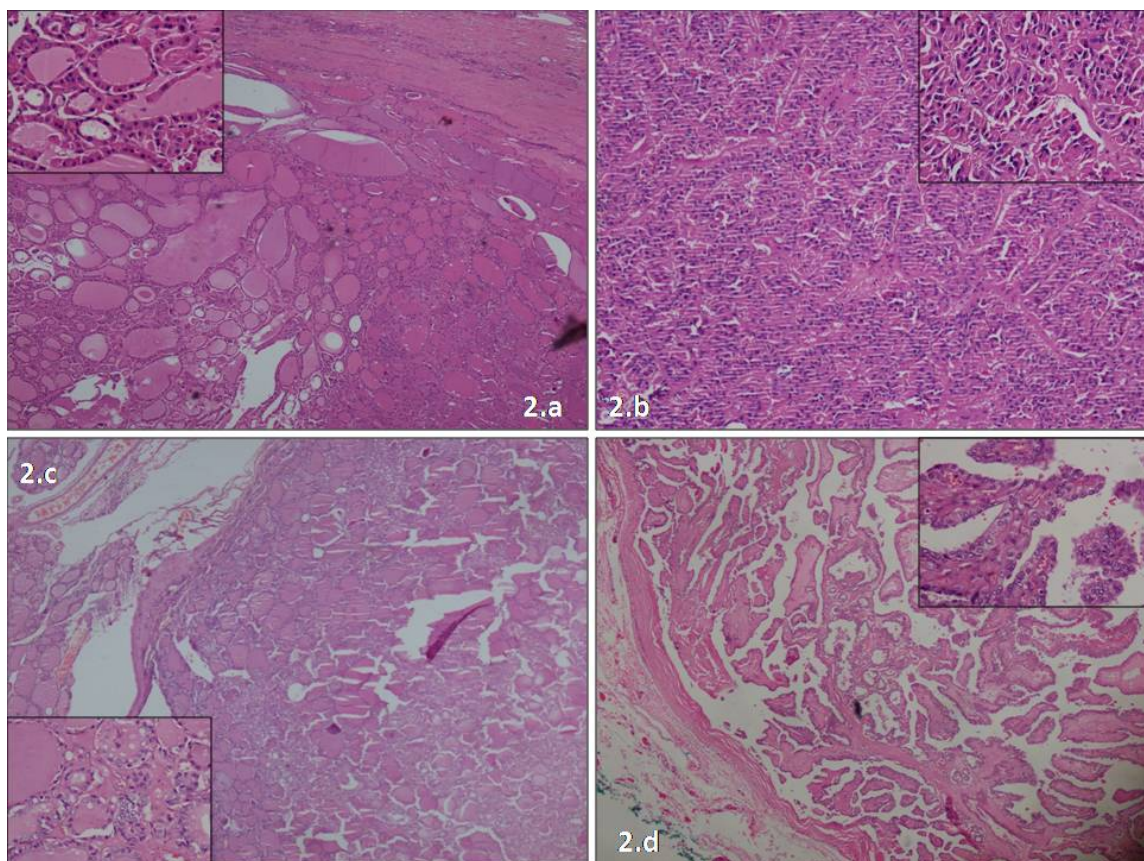
**Table 3:** Comparative analysis of discrepant cases (imaging versus cytology versus histology)

S.No.	Radiodiagnosis	Cytodiagnosis	HPE diagnosis
1.	S/O Parathyroid adenoma	S/O Adenomatous nodule	NIFTP, Right lobe
2.	Not available	S/O colloid goiter	Follicular variant of Papillary carcinoma, Left lobe
3.	Retrosternal goitre	Medullary carcinoma	Medullary carcinoma, Both lobes
4.	TIRADS III	S/O Follicular lesion of undetermined significance	Papillary carcinoma, Right lobe
5.	Not available	Suspicious of Papillary carcinoma	Nodular colloid goiter
6.	Multinodular goitre	AUS-PTC can not be ruled out	Nodular colloid goiter
7.	TIRADS III	S/O Nodular colloid goiter	Encapsulated Papillary carcinoma, Right lobe
8.	TIRADS II	S/O Adenomatous goiter	Minimally invasive follicular carcinoma





**Fig. 1:** **a:** Photomicrograph showing a case of Nodular colloid goitre (H&E,100X); **b:** Photomicrograph showing a case of Autoimmune thyroiditis (H&E,40X); Inset showing destruction of follicles by dense inflammatory infiltrate (high power view); **c:** Photomicrograph showing a case of Granulomatous thyroiditis (H&E,40X).



**Fig. 2:** **a:** Photomicrograph showing a case of Follicular Adenoma (H&E,40X); Inset showing oncocytic change (400X); **b:** Photomicrograph showing a case of Hurthle cell neoplasm predominantly composed of Hurthle cells (H&E,100X); Inset (high power view); **c:** Photomicrograph showing a case of NIFTP (H&E,40X); Inset showing high power view of papillary like nuclear features; **d:** Photomicrograph showing a case of Papillary carcinoma H&E,40X); Inset showing high power view of papillary nuclear features.

histopathology in maximum cases. We observed 08 discrepant cases (imaging versus cytology versus histology) including 03 cases diagnosed as non-neoplastic on cytology (two cases as TIRADS II/III on radiology) but reported as malignant on histopathology. Other 03 cases with cytological impression of Bethesda TBSRTC category III were finally diagnosed as nodular colloid goiter (2/3) and papillary carcinoma (1/3) histologically. Two cases (one case each considered benign on imaging or cytology) were reported malignant after histopathological examination. One case suggestive of adenomatous nodule was diagnosed as NIFTP later on excision specimen. Two pathologists also blindly reviewed aspirate smears of these discrepant cases, however, we did not find no definite population of cells to revise the cytological impression. These discrepancies may be attributed to sampling error (representative focus or multiple sites not sampled / inability to do multiple attempts for aspiration cytology via blind procedure), background blood/clot, cellular yield, overlapping cytological features / cellular degeneration / trauma. The incidence of false negative results by FNAC is as low as 1% to as high as 30%.<sup>1</sup>

## 5. Conclusion

In summary, colloid goitre and papillary carcinoma were found to be commonest non-neoplastic and neoplastic lesions respectively with a peak incidence in 20-40 years of age group. Histopathological diagnoses were in agreement with imaging findings and /or FNAC results in most of the cases. In case indeterminate or suspicious results, there is a need of monitoring or follow-up of these patients for early surgical intervention if required. Improved imaging techniques and Guided representative FNACs with intra-operative frozen section may be helpful for early diagnosis of thyroid pathology especially in grey zone cases.

## 6. Source of Funding

None.

## 7. Conflict of Interest

None.

## References

1. Gupta M, Gupta S, Gupta VB. Correlation of fine needle aspiration cytology with histopathology in the diagnosis of solitary thyroid

2. Gupta A, Jaipal D, Kulhari S, Gupta N. Histopathological study of thyroid lesions and correlation with ultrasonography and thyroid profile in western zone of Rajasthan, India. *Int J Res Med Sci.* 2016;4(4):1204–8.
3. Neki NS, Kazal HL. Solitary thyroid nodule-An insight. *J Ind Acad Clin Med.* 2006;7(4):328–33.
4. Raza S, Raza H, Saeed Z, Ahmed M. FNAC in the management of solitary thyroid nodule. *Prof Med J.* 2006;13(4):596–603.
5. Chetan VR, Veeresalingam B, Kumar MK, Durbesula PT, Rao PS. A study on the clinical manifestations and the incidence of benign and malignant tumors in a solitary thyroid nodule. *Int J Res Med Sci.* 2013;1(4):429–34.
6. Dhanaram B, Arunachalam J, Muthukumaraswamy B. A clinicopathological study of solitary nodule of thyroid. *Int Surg J.* 2017;4(7):2288–90.
7. Joseph E, Varghese A, Celine TM, Matthai A, Poothiade U. A study on the histopathological pattern of thyroid lesions in a tertiary care hospital. *Int J Res Med Sci.* 2016;4(12):5252–5.
8. Jena A, Patnayak R, Prakash J, Sachan A, Suresh V, Lakshmi AY, et al. Malignancy in solitary thyroid nodule: A clinicoradiopathological evaluation. *Indian J Endocrinol Metab.* 2015;19(4):498–503.
9. Chandanwale S, Singh N, Kumar H, Pradhan P, Gore C, Rajpal M, et al. Clinicopathological correlation of thyroid nodules. *Int J Pharm Biomed Sci.* 2012;3(3):97–102.
10. Fahim A, Quershi A, Alvi H, Azmi MA. Clinical presentation and evaluation of histopathological patterns of hospital-based frequency of thyroidectomized biopsies. *Med Forum.* 2012;23(9):28–31.
11. Sailaja D, Turlapati SPV, Mohapatra M, Devi PG, Prasanna MR, Srikanth O, et al. Histopathological evaluation of solitary nodules of thyroid. *Int J Contemp Med Re.* 2020;7(2):17–20.
12. Gurbani N, Lokwani P, Berdia R. To Study the Histopathological Forms of Thyroid Lesions Observed in Tertiary Care Hospital. *Int J Cur Res Rev.* 2020;12(14):109–12.
13. Beigh A, Amin J, Junaid S, Wani LA, Farooq S, Farooq S, et al. Histopathological study of thyroid neoplastic lesions in a tertiary care hospital-a 5 year study. *Int J Contemp Med Res.* 2018;5(4):4–7.
14. Chukudebelu O, Dias A, Timon C. Changing trends in thyroidectomy. *Ir Med J.* 2012;105(6):167–9.
15. Waseer MH, Hussain R, Malik MA. Solitary thyroid nodule: Role of FNAC. *Professional.* 2001;8(2):1–6.

## Author biography

**Brijesh Thakur**, Professor  <https://orcid.org/0000-0002-4600-5267>

**Jyotsna Bhateja**, Assistant Professor

**Sanjay Kaushik**, Professor

**Seema Acharya**, Professor

**Cite this article:** Thakur B, Bhateja J, Kaushik S, Acharya S. Revisitation of thyroid lesions in natives from hilly region: A four years perspective. *IP Arch Cytol Histopathology Res* 2023;8(3):195-199.