

Content available at: <https://www.ipinnovative.com/open-access-journals>

IP Archives of Cytology and Histopathology Research

Journal homepage: <https://www.achr.co.in/>

Original Research Article

Androgen receptor study in children with hypospadias in comparison with children with normal genitalia

Shreyas Rai¹, Adarsh Sanikop², Shridhar Ghagane³, RB Nerli^{1,*}¹Dept. of Urology, K.L.E. Academy of Higher Education & Research, Belagavi, Karnataka, India²Dept. of Pathology, JN Medical College, KLE Academy of Higher Education and Research, Belagavi, Karnataka, India³Dept. of Biotechnology, Dr. Prabhakar Kore Basic Science Research Centre, KLE Academy of Higher Education and Research, Belagavi, Karnataka, India

ARTICLE INFO

Article history:

Received 31-05-2023

Accepted 24-06-2023

Available online 30-10-2023

Keywords:

Hypospadias

Androgen receptor

Immunohistochemistry

ABSTRACT

Introduction: Androgen receptors (ARs) have been localized to the penile skin, inner prepuce and urethra. Androgens play an important and vital role in the development of male urethra. Androgen signalling through the AR is critical for normal penile development. The objective of our study was to prospectively assess the AR staining score in children with hypospadias in comparison with children with normal genitalia.

Materials and Methods: All children with hypospadias presenting to the Paediatric urological services for repair formed the study group. Children with normal genitalia and undergoing circumcision either for phimosis or for religious indications formed the controls. A piece of the foreskin was collected during surgery and were stained for immunohistochemistry. AR staining was expressed as an m-quick score.

Results: A total of 32 children (group I) underwent primary hypospadias repair and 24 children (group II) underwent circumcision during the study period. The mean m-quick score in patients with hypospadias was 219.96 ± 1.66 and that of children undergoing circumcision was 90.04 ± 3.71 ($p < 0.050$).

Conclusions: AR is overexpressed in patients with hypospadias when compared with patients with normal genitalia. Similarly, AR is significantly overexpressed in patients with proximal hypospadias when compared with distal hypospadias.

This is an Open Access (OA) journal, and articles are distributed under the terms of the [Creative Commons Attribution-NonCommercial-ShareAlike 4.0 License](https://creativecommons.org/licenses/by-nc-sa/4.0/), which allows others to remix, tweak, and build upon the work non-commercially, as long as appropriate credit is given and the new creations are licensed under the identical terms.

For reprints contact: reprint@ipinnovative.com

1. Introduction

Hypospadias is a most common congenital anomaly seen in boys, occurring in 1 in 150 to 300 live births.^{1,2} Recent evidence suggests that the urethra is entirely of endodermal origin,³ and that, the urethral plate formation is a contiguous process extending from the penile urethra into the glans and undergoes differentiation to form the stratified squamous layer.³ This hypothesis was further refined by experts describing the two-zipper hypothesis of urethral development.^{4,5} The “closing zipper” step is

androgen dependent and is unique to the development of the male urethra. As opposed to a simple fusion of the urethral folds, the fusion process occurs in an interlacing fashion at varying rates and levels, forming the contiguous urethra.^{4,5} Disruption of this process results in the large spectrum of variants of hypospadias.

Androgen receptors (ARs) have been localized to the penile skin, inner prepuce, urethra, and stromal cells of the corpus spongiosum during the early gestation period, suggesting a vital role for androgens in the development of the urethra.⁶ In patients with a lack of androgen receptor stimulation, there is a lack of fusion of the scrotal and/or urethral folds in the midline similar to that in the females.

* Corresponding author.

E-mail address: rbnerli@gmail.com (R. B. Nerli).

Androgen signalling through the AR is critical for normal penile development. AR plays a crucial role in male sex differentiation by mediating the biological effects of androgens. The AR gene resides on chromosome Xq11-12.⁷⁻⁹

Originally Alfred Jost, put forth the theory that the female genitalia phenotype is the “default” pathway that occurs in the absence of androgen signalling. However recent studies have refined the Jost hypothesis and suggested that penile development occurs as a result of a balance of androgenic and estrogenic activity.¹⁰ Qiao et al¹¹ examined the interaction between ZEB1 (zinc finger E-box gene) and the androgen receptor in vitro and the expression of AR in boys with hypospadias. They reported that the AR expression was higher in subjects with severe hypospadias than those with mild hypospadias and control subjects ($P < 0.05$). ZEB1 physically interacted with AR in human foreskin cells. The authors concluded that it was oestrogen that upregulated AR in vitro and that AR was overexpressed in patients with severe hypospadias. This suggested that oestrogen-induced abnormal AR expression was mediated by ZEB1 and this may be the mechanism through which oestrogen contributed to the development of hypospadias.

Balaji et al¹² analyzed AR expression in 16 hypospadias. This prospective study included 27 children with normal genitalia (who underwent circumcision for phimosis Group 1), and 16 hypospadias patients, with bilateral descended testis, and who had not received any preoperative testosterone (Group 2). Preoperative hormonal assay included luteinizing hormone (LH), follicle-stimulating hormone (FSH), and free testosterone (fTST) levels in all the patients. The foreskin collected during surgery was analysed for AR expression using immunohistochemistry. AR staining was expressed as H score. The mean H score was significantly higher ($P = 0.001$) in hypospadias patients (189.5) compared to controls (97.5). There was no significant difference in the hormone levels between the groups. In this study of ours we have prospectively assessed the AR staining score in children with hypospadias in comparison with children with normal genitalia.

2. Materials and Methods

This prospective study was initiated following permission obtained from the Institutional/University ethics committee. Informed consent was obtained from the children and their guardians, and complete confidentiality was maintained with regard to the clinical details. All children with hypospadias (with bilateral fully descended testis and who had not received any preoperative testosterone) presenting to the Paediatric urological services formed the study group. Children with normal genitalia and undergoing circumcision either for phimosis or for religious indications formed the controls. Preoperative hormonal assay including luteinizing hormone (LH), follicle-stimulating hormone

(FSH), and free testosterone (fTST) levels were assessed in all patients with hypospadias.

2.1. Immunohistochemistry

A piece of the foreskin was collected during surgery (either during hypospadias repair or circumcision) was fixed in formalin, paraffin embedded, and sectioned. The specimens were stained for immunohistochemistry assessment (anti-AR antibody PathnSitu, clone R441, 1/100 dilution). AR staining was expressed as H score¹² which was calculated by multiplying the intensity of staining and the percentage of stained cells showing cytoplasmic positivity at high power ($\times 40$). A total of 100 cells were counted at high power, and the intensity of AR expression was scored 0, 1, 2, and 3 based on the intensity of staining (brown) (Figure 1a-d). The total H score was calculated by multiplying the cell score and the number of cells, with a maximum score 300 if all 100 cells scored 3.

2.2. Statistical analysis

The mean H score was compared between both the groups using Student’s t-test. A similar comparison was made between patients with distal and proximal hypospadias patients. The difference was considered statistically significant if $P < 0.05$.

3. Results

During the study period Jan 2017 till Dec 2021, a total of 32 children (Group I) with a mean age of 34.03 ± 1.35 months underwent primary hypospadias repair at our center. During the same period 24 children (Group II) with a mean age of 27.08 ± 4.33 months underwent circumcision for reasons of phimosis, recurrent balanoposthitis or religious practices (Table 1).

The mean H score in patients with hypospadias was 219.96 ± 1.66 and that of children under going circumcision was 90.04 ± 3.71 ($p < 0.050$). Similarly, the H score was significantly higher ($P = 0.01$) in proximal (230.12 ± 2.1) compared to distal (190 ± 1.90) hypospadias.

Table 1: H score in children with hypospadias.

S.No.	Parameters	n	Age	H score p value
1	Circumcision	24	27.08 ± 4.33	90.04 ± 3.71 <0.001
2	Hypospadias Repair	32	34.03 ± 1.35	219.96 ± 1.66
3	Proximal hypospadias repair	09		230.12 ± 2.1 <0.001
4	Distal Hypospadias repair	23		190 ± 1.90

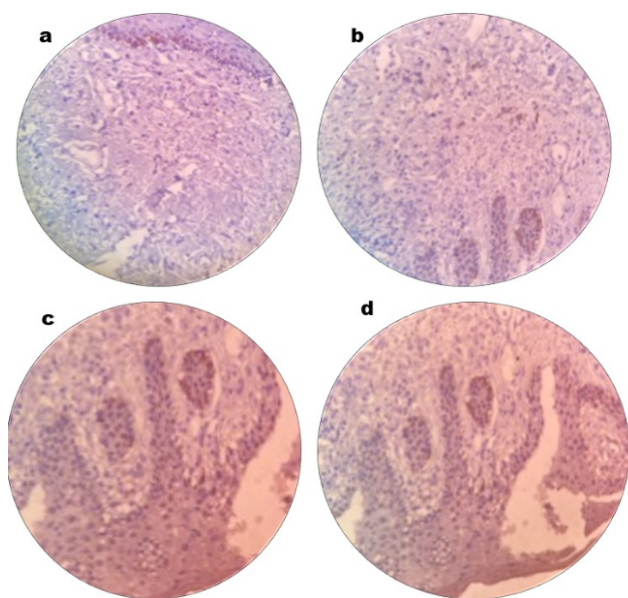


Fig. 1: a. Absent staining; b. Mild staining pattern; c. Moderate staining pattern; d. Strong staining pattern.

4. Discussion

Androgen signalling is critical for the normal development of the penis. Decrease in androgen signalling could result in a spectrum of incompletely virilized external genitalia. Complete androgen insensitivity usually results in external genitalia with a female phenotype and partial insensitivity could result in ambiguous genitalia of varying degrees.¹¹ Normal penile urethral development is regulated by testosterone (T) which is produced by the foetal testis and peripherally transformed into dihydrotestosterone (DHT). This DHT binds to the AR for further action.¹³ Any event leading to an insufficient androgen action in the male foetus may result in under-virilization in the newborn.¹⁴ The exact cause of hypospadias is unknown in most cases. The disruption of normal androgen signalling is thought to have a significant role in its occurrence. Epidemiologic studies have shown that oestrogen is a potential disruptor of androgen signalling as evidenced in boys who were exposed to elevated levels of oestrogen in utero have increased risk of hypospadias.⁹

Our study has clearly shown that AR is overexpressed in patients with hypospadias when compared to controls and similarly significantly more in patients with proximal compared to distal hypospadias. Similarly, Qiao et al¹¹ concluded that AR was overexpressed in patients with severe hypospadias. They also stated that in their study, AR expression levels increased in Hs68 cells as oestrogen concentration increased and AR expression was higher in preputial skin of boys with severe hypospadias compared to control subjects and those with mild hypospadias. Balaji et al¹² too concluded that AR expression was significantly elevated in hypospadias patients. It was higher in proximal

compared to distal hypospadias.

The AR gene has eight exons and exon 1 is known to encode the transactivation domain. Hemizygous mutations (as AR is X-linked) have been reported in patients with hypospadias in several studies, 15 predominantly in proximal hypospadias and often associated with other features of under-masculinisation, such as micropenis or bifid scrotum.^{15,16} The contribution of several polymorphisms in AR are yet to be confirmed. However, some authors have reported that an expanded CAG repeat could be relevant in isolated hypospadias.^{17,18} These polymorphisms may change the ability of AR to bind testosterone rather than the levels of AR, as mouse studies have reported no direct association between changes in AR mRNA expression and the presence or absence of hypospadias.¹⁹ Additional genes that work in conjunction with AR or downstream of it have also been implicated in the aetiology of hypospadias.

Pichler et al²⁰ reported their study on quantification and comparison of the androgen receptor (AR) levels in prepuces of 40 boys with and without hypospadias. AR mRNA was significantly elevated in the prepuces of boys with hypospadias compared with boys without hypospadias, at a mean (SD) of 28.33 (5.39) vs 15.31 (1.85) ($P = 0.013$). Furthermore, the amount of AR protein was higher in boys with, compared with boys without hypospadias, at a mean (SD) of 133.25 (6.17) vs 100 (4.45) ($P = 0.014$).

5. Conclusion

In conclusion AR is overexpressed in patients with hypospadias when compared with patients with normal genitalia. Similarly, AR is significantly overexpressed in patients with proximal hypospadias when compared with distal hypospadias.

6. Conflicts of Interest

There are no conflicts of interest.

7. Source of Funding

None.

References


1. Elliott CS, Halpern MS, Paik J, Maldonado Y, Shortliffe LD. Epidemiologic trends in penile anomalies and hypospadias in the state of California. *J Pediatr Urol.* 1985;7(3):294–8.
2. Springer A, Van Den Heijkant M, Baumann S. Worldwide prevalence of hypospadias. *J Pediatr Urol.* 2015;12(3):125.e1–7.
3. Kurzrock EA, Baskin LS, Cunha GR. Ontogeny of the male urethra: theory of endodermal differentiation. *Differentiation.* 1999;64(2):115–22. doi:10.1046/j.1432-0436.1999.6420115.x.
4. Li Y, Sinclair A, Cao M, Shen J, Choudhry S, Botta S, et al. Canalization of the urethral plate precedes fusion of the urethral folds during male penile urethral development: the double zipper hypothesis. *J Urol.* 2015;193(4):1353–9.

5. Shen J, Overland M, Sinclair A, Cao M, Yue X, Cunha G, et al. Complex epithelial remodeling underlie the fusion event in early fetal development of the human penile urethra. *Differentiation*. 2016;92(4):169–82.
6. Kim KS, Liu W, Cunha GR, Russell DW, Huang H, Shapiro E, et al. Expression of the androgen receptor and 5 alpha-reductase type 2 in the developing human fetal penis and urethra. *Cell Tissue Res*. 2002;307(2):145–53.
7. Kalfa N, Philibert P, Sultan C. Is hypospadias a genetic, endocrine or environmental disease, or still an unexplained malformation? *Int J Androl*. 2009;32(3):187–97.
8. Vilela ML, Willingham E, Buckley J, Liu BC, Agras K, Shiroyanagi Y, et al. Endocrine disruptors and hypospadias: role of genistein and the fungicide vinclozolin. *Urology*. 2007;70(3):618–21.
9. Klip H, Verloop J, Van Gool J, Koster ME, Burger CW, Van Leeuwen F, et al. Hypospadias in sons of women exposed to diethylstilbestrol in utero: A cohort study. *Lancet*. 2002;359(9312):1102–7.
10. Yang JH, Menshenina J, Cunha GR, Place N, Baskin LS. Morphology of mouse external genitalia: implications for a role of estrogen in sexual dimorphism of the mouse genital tubercle. *J Urol*. 2010;184(4):1604–9.
11. Qiao L, Tasian G, Zhang H, Cao M, Ferretti M, Baskin LS, et al. Androgen receptor is overexpressed in boys with severe hypospadias, and ZEB1 regulates androgen receptor expression in human foreskin cells. *Pediatric Res*. 2012;71(4 Pt 1):393–8.
12. Balaji DR, Reddy G, Babu R, Paramaswamy B, Ramasundaram M, Agarwal P, et al. Androgen receptor expression in hypospadias. *J Indian Assoc Pediatr Surg*. 2020;25(1):6–9.
13. Miller W. Steroid hormone biosynthesis and actions in the materno-feto-placental unit. *Clin Perinatol*. 1998;25(4):799–817.
14. Wohlfahrt-Veje C, Main KM, Skakkebaek NE. Skakkebaek NE Testicular dysgenesis syndrome: foetal origin of adult reproductive problems. *Clin Endocrinol (Oxf)*. 2009;71(4):459–65.
15. Wang Y, Li Q, Xu J, Liu Q, Wang W. Mutation analysis of five candidate genes in Chinese patients with hypospadias. *Eur J Hum Genet*. 2004;12(9):706–12. doi:10.1038/sj.ejhg.5201232.
16. Thai HTT, Kalbasi M, Lagerstedt K, Frisén L, Kockum I, Nordenskjöld A, et al. The valine allele of the V89L polymorphism in the 5-alpha-reductase gene confers a reduced risk for hypospadias. *J Clin Endocrinol Metab*. 2005;90(12):6695–8.
17. van der Zanden L, van der Zanden L, van Rooij I, Feitz WFJ, Franke B, Knoers N, et al. Aetiology of hypospadias: a systematic review of genes and environment. *Hum Rep Update*. 2012;18(3):260–83.
18. Lim HN, Nixon RM, Chen H, Hughes IA, Hawkins JR. Evidence that longer androgen receptor polyglutamine repeats are a causal factor for genital abnormalities. *J Clin Endocrinol Metab*. 2001;86(7):3207–10.
19. Agras K, Willingham E, Liu B, Baskin LS. Ontogeny of androgen receptor and disruption of its mRNA expression by exogenous estrogens during morphogenesis of the genital tubercle. *J Urol*. 2006;176(4 Pt 2):1883–8.
20. Pichler R, Djedovic G, Klocker H, Heidegger I, Strasak A, Loidl W, et al. Pichler R, Djedovic G, Klocker H, Heidegger I, Strasak A, Loidl W, Bektic J, Skradski V, Horninger W, Oswald J. Quantitative measurement of the androgen receptor in prepuces of boys with and without hypospadias. *BJU international*. 2013 Jul;112(2):265–70. *BJU Int*. 2013;112(2):265–70.

Author biography

Shreyas Rai, Resident

Adarsh Sanikop, Assistant Professor

Shridhar Ghagane, Scientist  <https://orcid.org/0000-0001-8959-3209>

RB Nerli, Professor

Cite this article: Rai S, Sanikop A, Ghagane S, Nerli RB. Androgen receptor study in children with hypospadias in comparison with children with normal genitalia. *IP Arch Cytol Histopathology Res* 2023;8(3):206-209.