

Content available at: <https://www.ipinnovative.com/open-access-journals>

IP Archives of Cytology and Histopathology Research

Journal homepage: <https://www.achr.co.in/>

## Case Report

# Metastatic ovarian high grade serous carcinoma with intestinal and omental deposits and marked clinicopathological treatment response in right ovary: A rare case report

Kafil Akhtar<sup>1\*</sup>, Zohra N Hashmi<sup>1</sup>, Sara Fatima Aslam<sup>1</sup>, Adiba Khan<sup>1</sup>

<sup>1</sup>Dept. of Pathology, Jawaharlal Nehru Medical College, Aligarh Muslim University, Aligarh, Uttar Pradesh, India



### ARTICLE INFO

#### Article history:

Received 03-12-2023

Accepted 21-12-2023

Available online 08-01-2024

#### Keywords:

High grade

Serous ovarian cancer

Intestine

Omental deposits

### ABSTRACT

High grade serous ovarian cancer is the most common form of ovarian cancer which is frequently fatal, as it is commonly diagnosed after substantial metastasis has already occurred. The present study reports a 65 years old woman with postmenopausal bleeding for 3 months. CE-MRI revealed malignant right ovarian lesion with broad ligament fibroid with malignant degeneration. Histopathological examination was consistent with high grade serous carcinoma of right ovary. Patient then received 6 cycles of chemotherapy. After 4 months, she developed abdominal discomfort and backache for which a repeat CE-MRI was performed which showed a heterogeneity in the right adnexa with no markedly appreciable abnormal foci in the right ovary. Subsequently the patient underwent transabdominal hysterectomy with bilateral salpingo-oophorectomy with right hemicolectomy and omentectomy. Microscopic examination of intestine and omentum showed infiltration by tumor cells. A final diagnosis of metastatic high grade carcinoma of ovary with intestinal and omental deposits was given.

This is an Open Access (OA) journal, and articles are distributed under the terms of the [Creative Commons Attribution-NonCommercial-ShareAlike 4.0 License](https://creativecommons.org/licenses/by-nc-sa/4.0/), which allows others to remix, tweak, and build upon the work non-commercially, as long as appropriate credit is given and the new creations are licensed under the identical terms.

For reprints contact: [reprint@ipinnovative.com](mailto:reprint@ipinnovative.com)

## 1. Introduction

Epithelial ovarian cancer has a high metastatic potential and is the leading cause of death from gynaecologic malignancy.<sup>1,2</sup> Most patients with ovarian cancer presents after the tumor has metastasized to the peritoneum outside the pelvis such as the omentum, small intestine, mesentery, retroperitoneal lymph nodes or to distant organs such as liver, bone, spleen, lung and lymph nodes outside the abdominal cavity.<sup>3</sup> Due to this, a complete resection in debulking surgery is difficult for patients with advanced ovarian cancer to undergo.<sup>4</sup> Furthermore, many of the patients initially respond to the chemotherapy, however chemoresistant residual tumors can survive in metastatic sites.<sup>5,6</sup>

With regard to the metastatic pathway, it has been found that ovarian cancer cells preferentially metastasize to the omentum via direct dissemination instead of via hematogenous routes because of lack of anatomical barriers around the primary lesion of ovarian cancer in the abdominal cavity.<sup>4</sup>

Although omentum is primarily an adipose tissue, it also contain clusters of leukocytes called ‘milky spots’ consisting of T and B lymphocytes, macrophages and dendritic cells that contribute to peritoneal immunity by collecting antigens and pathogens and promoting immune response.<sup>7</sup> Crucially, the omentum collects metastasising tumor cells and supports tumor growth by immunological and metabolic mechanisms.<sup>8,9</sup>

\* Corresponding author.

E-mail address: [drkafilakhtar@gmail.com](mailto:drkafilakhtar@gmail.com) (K. Akhtar).

## 2. Case Report

A 65 years old female, Parity 4 with 3 spontaneous abortions presented to Gynaecologic outpatient department with complaints of postmenopausal bleeding for 3months. There was no history of fever, cough and weight loss. There was no history of hypertension, tuberculosis and diabetes mellitus. There was no history of endometrial carcinoma. No other significant past medical or surgical history was known. None of the family members had similar complaints. Consent was obtained from the patient and a general physical examination was performed.

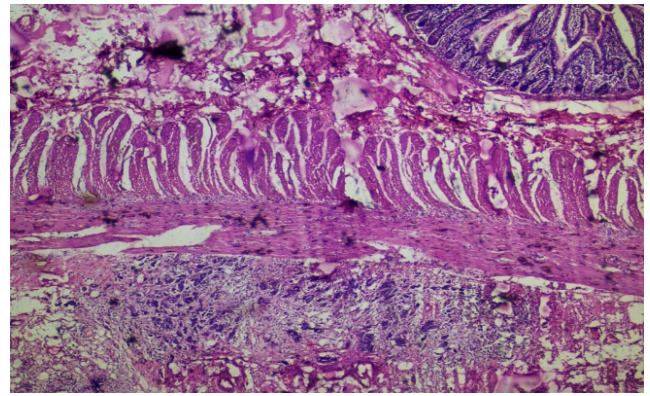
On physical examination, patient was pale. She was found to have mild distension of the abdomen. Her abdomen was non tender to palpation with normal bowel sounds. There was no hepatomegaly and splenomegaly. Pelvic examination revealed a painless non mobile right adnexal mass.

Investigations showed microcytic hypochromic anemia with haemoglobin of 7.0 g% with leucocyte count of 14500cells/mm<sup>3</sup>. Liver function test was normal. Contrast Enhanced Magnetic Resonance Imaging (CE-MRI) showed a heterogenous lobulated lesion enhancing lesion in right adnexa with non-visualization of right ovary, separately appearing hypointense on T1 and heterogeneously on T2, of size 4.2×6.0×4.2cm. Anterosuperiorly the lesion was abutting small bowel loops and sigmoid colon with focally indistinct fat planes. Also few small hypointense lesions appearing T1/T2 hypointense relative to myometrium (?Intramural fibroid of size 5×6mm) were seen.

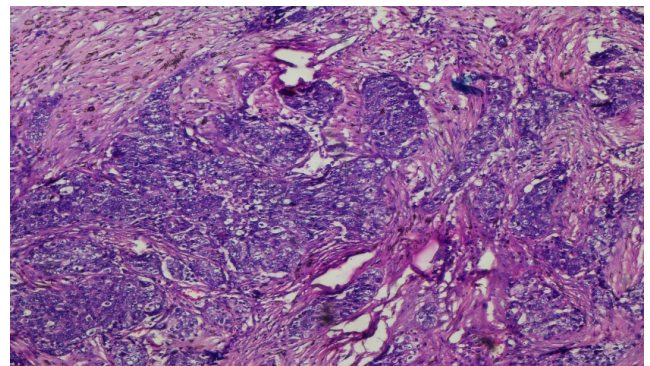
Biopsy showed solid sheets and few papillary structure having markedly pleomorphic cells with high nucleocytoplasmic ratio, hyperchromatic nuclei with scant to moderate eosinophilic cytoplasm. Frequent mitosis were seen. The patient was diagnosed as a case of high grade serous carcinoma of right ovary. She then received 6 cycles of chemotherapy at an interval of 21 days comprising of combination of Paclitaxel in a dose of 165mg/m<sup>2</sup> and Cisplatin in a dose of 50mg/m<sup>2</sup>.

After 4 months of the presenting complaints she developed gradual onset of abdominal discomfort and backache. She also complained of yellowish discharge per vaginum. A repeat CE-MRI showed heterogeneity in the right adnexa with no markedly appreciable abnormal foci in the right ovary and ascending colon. Left ovary appeared atrophied. No significant pelvic lymphadenopathy was seen.

Following which, a transabdominal hysterectomy with bilateral salpingo-oophorectomy, Right hemicolectomy with omentectomy was performed. On gross examination, uterus and cervix measured 5.5×4.5×1.5cm. Right ovary – 2×1.5cm, right fallopian tube – 4cm, left ovary – 1×0.5cm, left fallopian tube - 4.5cm. There was also a fatty tissue piece (?omentum) measuring 10×5×4cm which on serial sectioning, showed multiple, firm white areas (?tumor areas).

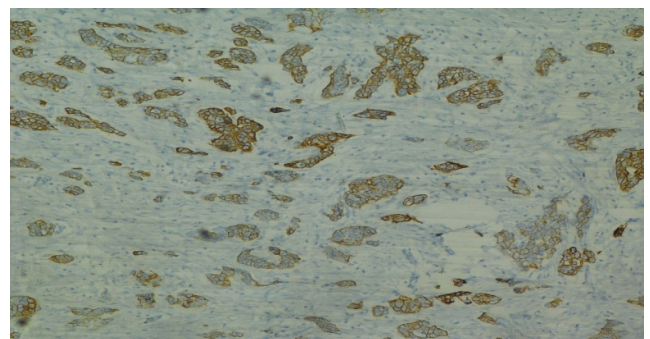


**Figure 1:** Biopsy showed few clusters of pleomorphic cells in acinar configuration. Hematoxylin and Eosin x10X



**Figure 2:** Tissue section from the intestine showed sheets of atypical cells with marked anisonucleosis with congested blood vessels and lymphocytic infiltration with areas of haemorrhage and necrosis. Hematoxylin and Eosin x10X

On immunohistochemistry, CK 7 was found to be positive in the tumor cells in the intestine and omentum (Figure 3)



**Figure 3:** On immunohistochemistry, CK 7 was found to be positive in the and tumor cells. IHC CK 7x10X.

Microscopic examination of right ovary revealed complete collagenization without any evidence of atypical epithelial cells. Blood vessels were thickened

and congested. Stroma was thickly collagenized with widespread areas of hyaline degeneration and focal collection of theca cells and corpus luteum. No evidence of any atypical cells were seen. However, section from the intestine and omentum shows sheets of atypical cells along with mononucleated, binucleated and multinucleated tumor cells scattered in omentum admixed with omental fat, congested blood vessels and lymphocytic infiltration with areas of haemorrhage and necrosis (Figures 1 and 2).

On the basis of history, clinical examination and investigations, the patient was diagnosed as a case of metastatic High Grade Serous Carcinoma with marked treatment response in right ovary (yPT<sub>3a</sub>N<sub>x</sub>) Stage IV with intestinal and omental metastasis. Post operatively patient was given 3 cycles of chemotherapy consisting of paclitaxel in a dose of 50mg/m<sup>2</sup>. Our patient was followed up for 6 months with no evidence of recurrence.

### 3. Discussion

High grade serous ovarian cancer is the most prevalent as well as the most fatal type of ovarian cancer accounting for approximately 30.0-60.0% of the cases and causing 70.0-80.0% of the mortalities.<sup>10</sup> Due to lack of screening methods and the nonspecific symptoms associated with HGSC, the majority of the women are diagnosed only after extensive metastasis has occurred.<sup>11</sup> Treatment includes combination of surgical debulking and platinum-based chemotherapy, however many patients suffer from recurrences and the overall survival is 46.0%.<sup>12</sup>

HGSC is a heterogenous disease because cases have a diversity of clinical features, therapeutic responses and prognosis.<sup>13</sup> Analysis of gene expression microarray from the cancer genome atlas project revealed that HGSC could be classified as one of the four gene expression subtypes: immunoreactive, differentiated, proliferative or mesenchymal. These subclassifications display distinct prognosis and sensitivities to chemotherapy.<sup>14,15</sup> Of these histopathological classification the mesenchymal type which is defined by a remarkable desmoplastic reaction has the worst prognosis and the immunoreactive, which is defined by lymphocytes surrounding and infiltrating the malignant tissue has the most favourable prognosis.<sup>13</sup> Previous studies suggested that metastatic ovarian cancer cells acquire chemoresistance by a reciprocal interaction with stromal cells in the omentum, which subsequently leads to unfavourable outcome.<sup>4</sup>

During ovarian cancer metastatic spread, the omentum is one of the most preferred sites of metastasis and frequently forms a large mass known as 'omental cake'.<sup>4</sup> The immunomodulatory functions and adipose rich composition of the omentum are thought to create a tumor promoting niche that encourages an inflammatory and proangiogenic microenvironment.<sup>8</sup> Omental adipocytes express high levels of IL-6, TIMP1 and adiponectin which can recruit tumor

cells.<sup>16</sup>

Omental metastasis is an independent prognostic factor and is associated with increased chemoresistance in stage III-IV ovarian cancer patients.<sup>4</sup> In a study, patients with a poor response to chemotherapy for omental metastatic tumors had significantly worse survival outcomes than patients with good response to chemotherapy in advanced stage ovarian cancer.<sup>4</sup>

In the current clinical guidelines, omentectomy is included in the standard surgical procedure for all cases of ovarian cancer for assessing adequate surgical staging.<sup>17-20</sup> However, it has been not clear whether excising the omentum has therapeutic significance, despite the recommendation for undergoing omentectomy.<sup>21</sup>

Our patient was diagnosed as a case of high grade serous carcinoma of right ovary which metastasized to the omentum. The patient had received 6 cycles of chemotherapy prior to surgery. Patient then underwent transabdominal hysterectomy with bilateral salpingo-oophorectomy with omentectomy. Right ovary showed marked treatment response, however metastatic deposits were seen in the omentum.

### 4. Source of Funding

None.

### 5. Conflict of Interest

None.

### References

1. Torre LA, Trabert B, Desantis CE, Miller KD, Samimi G, Runowicz C, et al. Ovarian cancer statistics. *CA Cancer J Clin.* 2018;68(4):284–96.
2. Bast RC, Hennessey B, Mills GB. The biology of ovarian cancer: new opportunities for translation. *Nat Rev Cancer.* 2009;9(6):415–28.
3. Buys SS, Patridge E, Black A, Johnson CC, Lamerato L, Isaacs C, et al. Effect of screening on ovarian cancer mortality: the prostate, lung, colorectal and ovarian (PLCO) cancer screening randomized control trial. *JAMA.* 2011;305(22):2295–303.
4. Iwagoi Y, Motohara T, Hwang S, Fujimoto K, Ikeda T, Katabuchi H, et al. Omental metastasis as a predictive risk factor for unfavorable prognosis in patients with stage III-IV epithelial ovarian cancer. *Int J Clin Oncol.* 2021;26(5):995–1004.
5. Motohara T, Katabuchi H. Ovarian cancer stemness: biological and clinical implications for metastasis and chemotherapy resistance. *Cancer.* 2019;11(7):907–8.
6. Bowtell DD, Bohm S, Ahmed AA, Aspuria PJ, Jr RB, Beral V, et al. Rethinking ovarian cancer II: reducing mortality from high grade serous ovarian cancer. *Nat Rev Cancer.* 2015;15(11):668–79.
7. Xiojing M. The omentum, a niche for premetastatic ovarian cancer. *J Exp Med.* 2020;217(4):e20192312. doi:10.1084/jem.20192312.
8. Gerber SA, Rybalko VY, Bigelow CE, Foster TH, Ferlinger JG. Preferential attachment of peritoneal tumor metastasis to omental immune aggregates and possible role of a unique vascular microenvironment in metastatic survival and growth. *Am J Pathol.* 2006;169(5):1739–52.
9. Moreno JR, Moyron-Quiroz JE, Carragher DM, Hartson L, Moquin A, Randall TD, et al. Omental milky spots develop in the absence of lymphoid tissue inducer cells and support B and T cell responses to

- peritoneal antigens. *Immunity*. 2009;30(5):731–43.
10. Coburn SB, Bray F, Sherman ME, Trabert B. International patterns and trends in ovarian cancer incidence, overall and by histologic subtype. *Int J*. 2017;140(11):2451–60.
  11. Gubbels JA, Claussen N, Kapur AK, Connor JP, Patankar MS. The detection, treatment and biology of epithelial ovarian cancer. *J Ovarian Res*. 2010;3:8. doi:10.1186/1757-2215-3-8.
  12. ACS 2016 Cancer Facts and Figures 2016 American Cancer Society and Journal; 2016. Available from: <http://cancerstatisticscenter.cancer.org>.
  13. Ohsuga T, Yamaguchi K, Kido A, Murakami R, Abiko K, Hamanishi J, et al. Distinctive preoperative clinical features predict four histopathological subtypes of high grade serous carcinoma of the ovary, fallopian tube and peritoneum. *BMC Cancer*. 2017;17:580. doi:10.1186/s12885-017-3573-1.
  14. Cancer Genome Atlas research Network. Integrated genome analysis of ovarian carcinoma. *Nature*. 2011;474(7353):609–15.
  15. Verhaak RG, Tamayo P, Yang JY, Hubbard D, Zhang H, Creighton CJ, et al. Prognostically relevant gene signatures of high grade serous carcinoma. *J Clin Invest*. 2013;123(1):517–25.
  16. Nieman KM, Kennay HA, Penicka CV, Ladanyi A, Buell-Gutbrod R, Zillhardt MR, et al. Adipocytes promote ovarian cancer metastasis and provide energy for rapid tumor growth. *Nat Med*. 2011;17(11):1498–503.
  17. Berek JS, Kehoe ST, Kumar L, Friedlander M. Cancer of the ovary, fallopian tube, and peritoneum. *Int J Gynaecol Obstet*. 2018;143(Suppl 2):59–78.
  18. National Comprehensive Cancer Network. NCCN clinical practice guidelines in oncology. Ovarian cancer including fallopian tube cancer and primary peritoneal cancer. National Comprehensive Cancer Network. Plymouth meeting, PA; 2017. Available from: <https://www.nccn.org/>.
  19. Komiyama S, Katabuchi H, Mikami M. Japan Society of Gynecologic Oncology guidelines 2015 for the treatment of ovarian cancer including primary peritoneal cancer and fallopian tube cancer. *Int J Clin Oncol*. 2016;21(3):435–46.
  20. Arie AB, McNally L, Kapp DS. The omentum and omentectomy in epithelial ovarian cancer: a reappraisal. Part I-omental function and history of omentectomy. *Gynecol Oncol*. 2013;131(3):780–3.
  21. Arie AB, McNally L, Kapp DS. The omentum and omentectomy in epithelial ovarian cancer: a reappraisal: part II-the role of omentectomy in the staging and treatment of apparent early stage epithelial ovarian cancer. *Gynecol Oncol*. 2013;131(3):784–90.

## Author biography

**Kafil Akhtar**, Professor  <https://orcid.org/0000-0002-3482-1195>

**Zohra N Hashmi**, Resident

**Sara Fatima Aslam**, Resident

**Adiba Khan**, Resident

**Cite this article:** Akhtar K, Hashmi ZN, Aslam SF, Khan A. Metastatic ovarian high grade serous carcinoma with intestinal and omental deposits and marked clinicopathological treatment response in right ovary: A rare case report. *IP Arch Cytol Histopathology Res* 2023;8(4):281-284.