

Content available at: <https://www.ipinnovative.com/open-access-journals>

IP Archives of Cytology and Histopathology Research

Journal homepage: <https://www.achr.co.in/>

Case Series

Sinonasal malignant melanoma- Diagnostically hidden Gem

Alankrita Madhur¹, Kalpana Mangal^{1*}, Ishita Bansal¹

¹SMS Medical College, Jaipur, Rajasthan, India



ARTICLE INFO

Article history:

Received 30-11-2023

Accepted 11-12-2023

Available online 08-01-2024

Keywords:

Sinonasal

Melanoma

Histopathology

ABSTRACT

Malignant melanoma is a prevalent form of skin cancer, but its occurrence as a sinonasal tumour is exceptionally uncommon, constituting less than 1% of nasal and sinonasal malignancies. Typically diagnosed in individuals aged 50 to 60, these tumours often manifest with symptoms such as nasal obstruction and recurrent, painless epistaxis. Despite their location, malignant melanoma cases generally have a bleak prognosis. Diagnosis primarily relies on Immunohistochemistry and histopathology.

This is an Open Access (OA) journal, and articles are distributed under the terms of the [Creative Commons Attribution-NonCommercial-ShareAlike 4.0 License](https://creativecommons.org/licenses/by-nc-sa/4.0/), which allows others to remix, tweak, and build upon the work non-commercially, as long as appropriate credit is given and the new creations are licensed under the identical terms.

For reprints contact: reprint@ipinnovative.com

1. Introduction

Malignant melanoma, a form of skin cancer, comprises only 2% of all human malignancies, primarily originating from the skin. Lucke first described this malignancy in 1969.¹ Sinonasal malignant melanoma is an extremely rare presentation, constituting less than 1% of nasal malignancies.² Arising from abnormal melanocytes and neural crest cells, these tumours are more commonly found in the nasal cavity than in the sinuses, particularly in the anterior septum, inferior turbinate, and middle turbinate. Paranasal sinus melanomas typically affect the antrum and then the ethmoid.

With an equal distribution between genders and a common occurrence in the fifth decade, patients usually present with a nasal mass. Upon examination, these masses appear as pigmented, sessile, or polypoidal masses. Early detection and complete excision result in a high cure rate. The 5-year survival rate is 35%, with a median survival time of 36%.

Histomorphologically, melanomas exhibit various patterns with medium-sized polygonal cells, featuring

small to moderate amounts of eosinophilic cytoplasm and pleomorphic, hyperchromatic nuclei.³ Mitotic figures and apoptotic bodies are numerous, and melanin can vary from scant to abundant in cells. Immunohistochemistry (IHC) studies, employing markers such as HMB-45, S100, Melan A, and the Pigment Epithelium-Derived Factor (PEDF), aid in diagnosis, especially in challenging cases. Confusion in diagnosis may arise with olfactory neuroblastoma, lymphoepithelioma, rhabdomyosarcoma, and small cell undifferentiated carcinoma.⁴

While malignant melanoma is highly curable when detected early and fully excised, as the disease metastasizes, treatment options become limited, leading to a decrease in survival rate to months.⁵

2. Case Series

The following cases from 2018 to 2021 were received at Department of Pathology SMS Medical College Jaipur. Haematoxylin and Eosin staining were performed on following cases followed by IHC.

* Corresponding author.

E-mail address: dralankritamadhur2015@gmail.com (K. Mangal).

2.1. Case 1

Patient History: A 47-year-old male presents with a polypoidal mass in the left nasal cavity.

Microscopic Examination: The examination reveals a poorly differentiated pleomorphic malignant neoplasm (Figure 1).

IHC Findings: Tumor cells show positivity for vimentin, S-100, and focal positivity for Melan A. However, they are negative for Desmin, p40, CK 5/6, Pan CK, CD 34, CD31, and HMB-45.

Impression: The diagnosis indicates a poorly differentiated Malignant Melanoma.

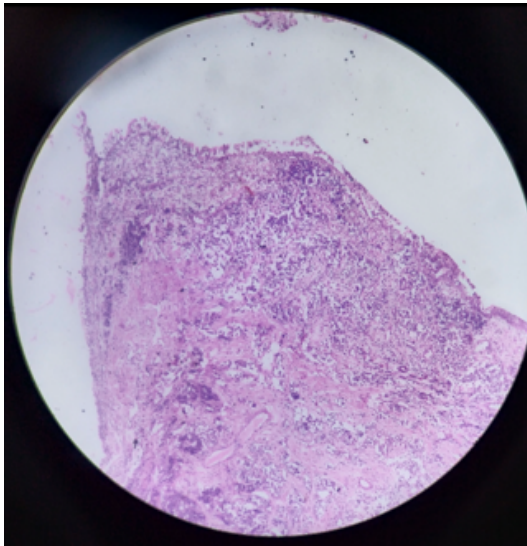


Figure 1: respiratory epithelium with infiltrating tumour cells (H&E scanner view)

2.2. Case 2

Patient History: A 70-year-old female presented with an orbital mass appearing to arise from the ethmoidal sinus.

Microscopic Examination: The examination reveals Malignant Melanoma.

IHC Findings: Tumor cells exhibit diffuse positivity for HMB-45 and patchy positivity for S-100 and Melan A (Figure 2). However, they are negative for Pan CK and GFAP.

Impression: The diagnosis indicates Malignant Melanoma.

2.3. Case 3

Patient History: A 74-year-old female presents with a mass in the right nasal cavity.

Microscopic Examination: Examination reveals ulcerated nasal mucosa with necrotic exudates. The underlying subcutaneous tissue shows an inflammatory

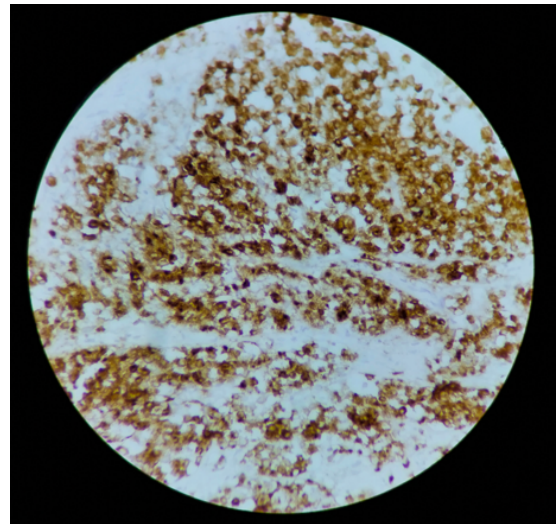


Figure 2: Tumour cells displaying HMB-45 positivity

infiltrate along with sheets of malignant large cells displaying hyperchromatic, angulated nuclei, and a plasmacytoid appearance in some areas.

IHC Findings: Tumor cells demonstrate positivity for HMB-45, S-100, Melan A, and vimentin. However, they are negative for pan CK and synaptophysin (Figure 3).

Impression: The diagnosis indicates Malignant Melanoma.

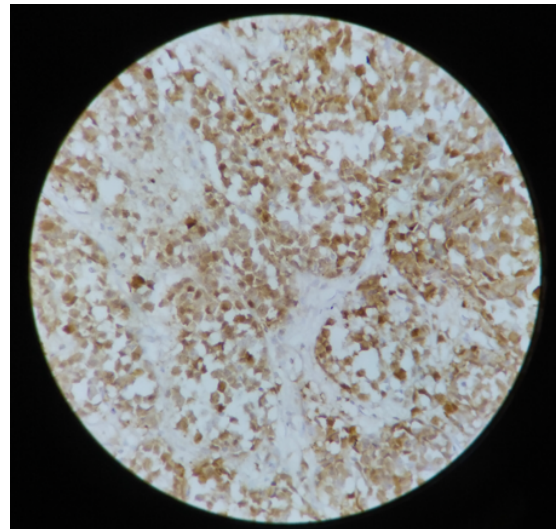


Figure 3: Tumour cells with S100 positive.

2.4. Case 4

Patient History: An 18-year-old female with a right nasal mass.

Microscopic Examination: Biopsy reveals tumor cells arranged in clusters and sheets. The cells exhibit a round to

oval and spindled morphology with an infiltrative pattern. The nucleus is vesicular with nucleolar prominence, and some cells show pigment.

IHC Findings: Tumor cells are diffusely positive for S-100 and vimentin, with focal positivity for CD 56. However, they are negative for Pan CK, synaptophysin, and CD 31 (Figure 4).

Impression: The diagnosis indicates Malignant Melanoma.

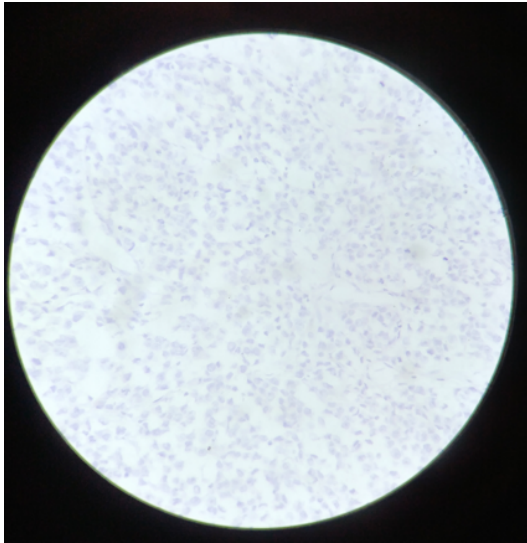


Figure 4: Microscopic view showing synaptophysin –ve status

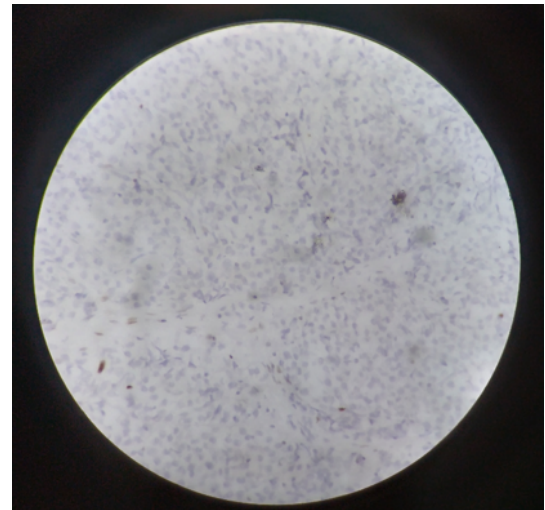


Figure 5: Tumour cells showing desmin negative

2.5. Case 5

Patient History: An 86-year-old male with a mass in the right nasal cavity.

Microscopic Examination: Malignant Melanoma is observed.

IHC Findings: Tumor cells exhibit diffuse positivity for Vimentin, S-100, and Melan A. However, they are negative for Pan CK, CK5/6, CK7, p63, and Desmin (Figure 5).

Impression: The diagnosis indicates Malignant Melanoma.

2.6. Case 6

Patient History: A 55-year-old female with a mass in the left nasal cavity.

Microscopic Examination: Poorly differentiated Malignant Melanoma is observed.

IHC Findings: Tumor cells show positivity for vimentin, S-100, and Melan A, while being negative for Pan CK.

Impression: The diagnosis indicates Malignant Melanoma.

2.7. Case 7

Patient History: A 45-year-old female with a right orbital mass originating from the ethmoidal sinus.

Microscopic Examination: The findings are suspicious of Malignant Melanoma.

IHC Findings: Neoplastic cells exhibit positivity for Vimentin and focal positivity for Melan A and S-100. However, they are negative for Pan CK.

Impression: The diagnosis indicates Malignant Melanoma.

3. Discussion

Sinonasal malignant melanoma is a rare and aggressive tumor, constituting less than 1% of nasal and paranasal malignancies, with a 5-year survival rate of 35%. According to the American College of Surgeons, only 1.3% of the 84,836 melanomas observed over a 9-year period developed on mucosal surfaces, with 55% occurring on the head and neck.⁶ The pathophysiology is primarily associated with mutations in melanocytes of neural crest cells.

These tumors typically present unilaterally with nonspecific symptoms, and complaints may include unilateral nasal blockage and epistaxis.⁷ On physical examination, melanomas can manifest as sessile or polypoidal, as well as melanotic or amelanotic. Thompson LD et al studied 115 cases and found that histologically, the tumors displayed a diverse range of cell types, including epithelioid, spindled, and undifferentiated cells, often arranged in a peritheliomatous distribution (n = 39). Immunohistochemical studies substantiated the diagnosis of sinonasal tract mucosal malignant melanomas, revealing positive reactions for S-100 protein, tyrosinase, HMB-45, melan A, and microphthalmia transcription factor.⁸ For the infiltration of tumors with T cells targeting tumor antigens,

it is essential to initiate an innate immune response. This process involves the production of type I interferons and the maturation and activation of dendritic cells. The activated dendritic cells play a crucial role in cross-presenting tumor antigens to T cells, facilitating an adaptive immune response against the tumor.⁹Top of Form

The treatment of choice is complete surgical excision, but the prognosis remains poor, with a 5-year survival rate of 35%.^{10,11}

Confirmation of the diagnosis relies on histopathology and immunohistochemistry (IHC). In the discussion of seven cases of sinonasal malignant melanoma, all presented as nasal masses and were diagnosed based on histopathology and IHC. Among the seven cases, five were female, and two were male, spanning different age groups, including the 4th, 7th, 5th, 8th decades, and one 18-year-old.

The IHC panel employed includes Melan A, S-100, HMB-45, vimentin, CK 5/6, CK 7, Desmin, and Pan CK. Melan A, S100, vimentin, and HMB 45 showed strong positivity for melanocytes. Additional IHC markers, such as MART1 and tyrosinase, were included. Notably, BRAF mutations, common in cutaneous melanomas, are not frequently observed in mucosal counterparts.

4. Conclusion

Hereby we present 7 rare cases of sino nasal melanoma. If not analysed carefully these cases may lead to diagnostic pitfall. Use of IHC in troubled cases is very essential for correct diagnosis.

5. Source of Funding

None

6. Conflict of Interest

None

References

1. Lund VJ. Sinonasal Malignant Melanoma. *Adv Otorhinolaryngol.* 2020;84:185–96.
2. Freedman HM, Desanto LW, Devine KD, Weiland LH. Malignant melanoma of the nasal cavity and paranasal sinuses. *Arch Otolaryngol.* 1973;97(4):322–5.
3. Gupta S, Singh PA, Misra V, Jain S. Malignant melanoma of maxillary sinus. *J Clin Diagn Res.* 2009;3(6):1801–4.
4. Strauss JE, Strauss SI. Oral malignant melanoma: A case report and review of literature. *J Oral Maxillofac Surg.* 1994;52(9):972–6.
5. Smoller BR. Immunohistochemistry in the Diagnosis of Malignant Melanoma. *Clin Dermatol.* 1991;9(2):235–41.
6. Chang AE, Karnell LH, Menck HR. The National Cancer Data Base report on cutaneous and noncutaneous melanoma: a summary of 84,836 cases from the past decade. The American College of Surgeons Commission on Cancer and the American Cancer Society. *Cancer.* 1998;83(8):1664–78.
7. Alves IS, Berriel LG, Alves RT, Pinto MB, Oliveira CF, Cazzotto AC, et al. Sinonasal Melanoma: A Case Report and Literature Review. *Case Rep Oncol Med.* 2017;p. 8201301. doi:10.1155/2017/8201301.
8. Thompson LD, Wieneke JA, Miettinen M. Sinonasal tract and nasopharyngeal melanomas: a clinicopathologic study of 115 cases with a proposed staging system. *Am J Surg Pathol.* 2003;27(5):594–611.
9. Ott PA. Intralesional Cancer Immunotherapies. *Hematol Oncol Clin North Am.* 2019;33(2):249–60.
10. Tarhini A, Atzinger C, Gupte-Singh K, Johnson C, Macahilig C, Rao S, et al. Treatment patterns and outcomes for patients with unresectable stage III and metastatic melanoma in the USA. *J Comp Eff Res.* 2019;8(7):461–73.
11. Nyakas M, Aamdal E, Jacobsen KD, Guren TK, Aamdal S, Hagene KT, et al. Prognostic biomarkers for immunotherapy with ipilimumab in metastatic melanoma. *Clin Exp Immunol.* 2019;197(1):74–82.

Author biography

Alankrita Madhur, Senior Resident

Kalpana Mangal, Professor

Ishita Bansal, Junior Resident 2nd Year

Cite this article: Madhur A, Mangal K, Bansal I. Sinonasal malignant melanoma- Diagnostically hidden Gem. *IP Arch Cytol Histopathology Res* 2023;8(4):292-295.