

Content available at: <https://www.ipinnovative.com/open-access-journals>

IP Archives of Cytology and Histopathology Research

Journal homepage: <https://www.achr.co.in/>

## Case Report

# Inflammatory myofibroblastic tumor of urinary bladder in young male: A case report and literature review

Jigna Jerambhai Kalariya <sup>1</sup>\*

<sup>1</sup>Dept. of Pathology, B.T Savani Kidney Hospital, Rajkot, Gujarat, India



## ARTICLE INFO

### Article history:

Received 22-02-2024

Accepted 29-04-2024

Available online 04-05-2024

### Keywords:

Inflammatory myofibroblastic tumor (IMT)

Histopathological examination

Immunohistochemistry study

## ABSTRACT

The objective of this study is to present a rare case of inflammatory myofibroblastic tumor (IMT) of the urinary bladder in young male, detailing its clinical presentation, diagnostic approach, treatment strategy, and outcome. Additionally, the objective includes conducting a literature review to provide insights into the characteristics, management, and prognosis of this uncommon tumor entity.

A 20-year-old male presenting with dysuria and dribbling of urine underwent diagnostic workup including imaging studies, cystoscopy. On cystoscopy there was a presence of 5x4 cm sized pedunculated mass in the urinary bladder. Partial cystectomy is done and specimen is examined for histopathology. Histopathological examination and Immunohistochemistry study of the tumor specimen was performed to confirm the diagnosis of inflammatory myofibroblastic tumor. A thorough literature review was conducted to gather relevant studies on IMT of the urinary bladder, focusing on clinical presentations, diagnostic modalities, treatment approaches, and outcomes. Diagnostic evaluation revealed a mass lesion in the urinary bladder, and histopathological examination following partial cystectomy confirmed the diagnosis of inflammatory myofibroblastic tumor. The patient underwent surgical excision of the tumor followed by adjuvant therapy. Regular follow-up examinations showed no evidence of tumor recurrence. The literature review identified a limited number of reported cases of IMT of the urinary bladder in young male, emphasizing its rarity and diverse clinical presentations. Various diagnostic modalities and treatment options, including surgery, chemotherapy, and targeted therapy, were discussed in the reviewed literature. Inflammatory myofibroblastic tumor of the urinary bladder is a rare neoplasm at younger age that can present with nonspecific symptoms, making its diagnosis challenging. However, timely recognition and appropriate management, including surgical resection and adjuvant therapy, can lead to favorable outcomes with low recurrence rates. This case report highlights the importance of considering IMT in the differential diagnosis of bladder masses in young patient and underscores the need for further research to better understand the pathogenesis and optimal treatment strategies for this rare tumor entity.

This is an Open Access (OA) journal, and articles are distributed under the terms of the [Creative Commons Attribution-NonCommercial-ShareAlike 4.0 License](https://creativecommons.org/licenses/by-nc-sa/4.0/), which allows others to remix, tweak, and build upon the work non-commercially, as long as appropriate credit is given and the new creations are licensed under the identical terms.

For reprints contact: [reprint@ipinnovative.com](mailto:reprint@ipinnovative.com)

## 1. Introduction

Inflammatory myofibroblastic tumor (IMT) of the urinary bladder is an exceptionally rare neoplasm characterized by the proliferation of myofibroblastic spindle cells within a background of chronic inflammation.<sup>1–4</sup> Despite its infrequency, IMT poses diagnostic and therapeutic

challenges due to its diverse clinical presentations and resemblance to other bladder malignancies. This report aims to present a case of IMT of the urinary bladder in young male, detailing its clinical course, diagnostic approach, treatment strategies, and outcome. Furthermore, a comprehensive literature review will be conducted to provide insights into the characteristics, management, and prognosis of this uncommon tumor entity.

\* Corresponding author.

E-mail address: [drjignapath83@gmail.com](mailto:drjignapath83@gmail.com) (J. J. Kalariya).

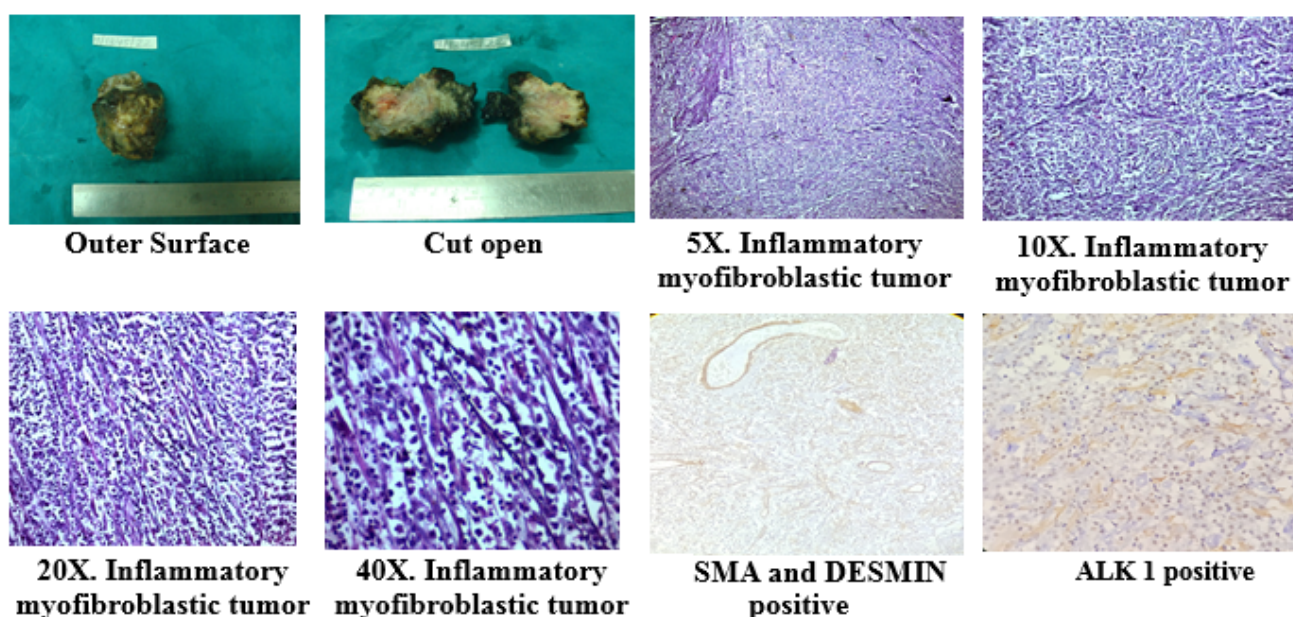


Figure 1:

## 2. Case Presentation

A 20-year-old male presented with complaints of dysuria and dribbling of urine without any episodes of hematuria. The patient was investigated through CT abdomen, which showed irregular heterogeneously enhancing mass on left dome of urinary bladder. All blood investigations including renal function test were normal. Cystoscopic examination demonstrated a protruding mass originating from the left dome of bladder wall measuring 5x4 cm sized. Partial cystectomy with bilateral iliac lymphnodes dissection was performed. Specimen was sent for histopathological examination. Histopathological examination and Immunohistochemistry study of the excised tissue done. On gross examination weight of specimen was 67.2 gms. 6.4 X 5.0 X 4.8 cm sized part of Urinary bladder with perivesicle fat with mass with surrounding margins received. There was a presence of 5.0 X 4.0 X 4.0 cm sized mass. Mass was single, solid, greyish white with yellowish brown colored areas and hard in consistency. On microscopic examination Sections from mass show Spindled cell proliferation with infiltration by inflammatory cells predominantly lymphocytes and plasma cells. Spindle cells are stellate myofibroblasts with abundant eosinophilic cytoplasm and elongated nuclei. Areas with hyalinisation present. Lamina propria and muscularis propria were showing involvement by tumor cells. Perivesical fat and surgical margins were free from tumor cells. Total 6 iliac lymphnodes were identified microscopically from the both sides and all were free from tumor cells. On immunohistochemistry study(7,8,9) shows positivity for ALK1, SMA and DESMIN in spindle

cells. CD 3, CD 20, CD138, Kappa and lambda were positive in background inflammatory cells. Negative for myogenin and EMA. So confirmed the diagnosis of inflammatory myofibroblastic tumor. Subsequent evaluation ruled out distant metastasis, and the patient after surgical excision followed by adjuvant therapy. Regular follow-up examinations showed no evidence of tumor recurrence.

## 3. Discussion

Inflammatory myofibroblastic tumor<sup>1,2</sup> of the urinary bladder in young male is a rare entity with a wide spectrum of clinical manifestations, ranging from asymptomatic to hematuria, dysuria, and abdominal pain. Diagnosis<sup>3,4</sup> relies on histopathological examination demonstrating spindle cell proliferation with inflammatory infiltrates. Differential diagnosis includes other bladder tumors such as sarcomatoid urothelial carcinoma, leiomyosarcoma and rhabdomyosarcoma which can be ruled out by immunohistochemistry study. Treatment strategies encompass surgical resection as the cornerstone, with adjuvant therapy reserved for unresectable or recurrent cases. The literature review highlights the rarity of IMT of the urinary bladder, with limited reported cases at young age and variable treatment outcomes. Various diagnostic modalities and treatment options, including chemotherapy and targeted therapy, have been explored with varying success rates.

#### 4. Conclusion

An Inflammatory myofibroblastic tumor of urinary bladder is an uncommon benign tumor of urinary bladder of unknown neoplastic potential. Inflammatory myofibroblastic tumor of the urinary bladder<sup>5,6</sup> at younger age remains a diagnostic and therapeutic challenge due to its rarity and nonspecific clinical features. However, timely recognition and appropriate management, including surgical excision and adjuvant therapy, can lead to favourable outcomes with low recurrence rates.<sup>7–11</sup> This case underscores the importance of considering IMT in the differential diagnosis of bladder masses and the need for further research to elucidate optimal treatment strategies for this rare tumor entity.

#### 5. Source of Funding

None.

#### 6. Conflict of Interest


None.

#### References

1. Machioka K, Kitagawa Y, Izumi K, Kitamura S, Ikeda H, Namiki M, et al. Inflammatory myofibroblastic tumor of the urinary bladder with benign pelvic lymph node enlargement: a case report. *Case Rep Oncol*. 2014;7(2):571–5.
2. Teoh JY, Chan NH, Cheung HY, Hou S, Ng C. Inflammatory myofibroblastic tumors of the urinary bladder: a systematic review. *Urology*. 2014;84(3):503–8.
3. Alam R, Johnson MH, Caldwell T. Diagnosing and treating inflammatory myofibroblastic tumor of the bladder. *Case Rep Urol*. 2016;p. 5724020. doi:10.1155/2016/5724020.

4. Siemion K, Reszec-Gielazyn J, Kisluk J, Roszkowiak L, Zak J, Korzynska A, et al. What do we know about inflammatory myofibroblastic tumors?-A systematic review. *Adv Med Sci*. 2022;67(1):129–38.
5. Marais B, Eyal P, Kesner K, John J. Inflammatory myofibroblastic tumour of the bladder: a case report and review of the literature. *Ther Adv Urol*. 2022;14. doi:10.1177/17562872221096385.
6. Balagobi B, Gobishangar S, Ginige A, Gamlaksha D, Sanjeyan J, Suvethini L, et al. Inflammatory myofibroblastic tumour: Case report of a rare form of bladder tumour. *Int J Surg Case*. 2022;92:106786. doi:10.1016/j.ijscr.2022.106786.
7. Coffin CM, Hornick JL, Fletcher CD. Inflammatory myofibroblastic tumor: Comparison of clinicopathologic, histologic, and immunohistochemical features including ALK expression in atypical and aggressive cases. *Am J Surg Pathol*. 2007;31(4):509–20.
8. Coffin CM, Patel A, Perkins S, Elenitoba-Johnson KS, Perlman E, Griffin CA, et al. ALK1 and p80 expression and chromosomal rearrangements involving 2p23 in inflammatory myofibroblastic tumor. *Mod Pathol*. 2001;14(6):569–76.
9. Cook JR, Dehner LP, Collins MH, Ma Z, Morris SW, Coffin CM, et al. Anaplastic lymphoma kinase (ALK) expression in the inflammatory myofibroblastic tumor: a comparative immunohistochemical study. *Am J Surg Pathol*. 2001;25(11):1364–71.
10. Libby EK, Ellis LT, Weinstein S, Hammer RD, Murray KS. Metastatic inflammatory myofibroblastic tumor of the bladder. *Urol Case Rep*. 2018;p. 10–2. doi:10.1016/j.eucr.2018.11.007.
11. Gros L, Tos AD, Jones RL, Digklia A. Inflammatory Myofibroblastic Tumour: State of the Art. *Cancers*. 2022;14(15):3662. doi:10.3390/cancers14153662.

#### Author biography

**Jigna Jerambhai Kalariya**, Consultant Pathologist  
 <https://orcid.org/0000-0003-3804-6154>

**Cite this article:** Kalariya JJ. Inflammatory myofibroblastic tumor of urinary bladder in young male: A case report and literature review. *IP Arch Cytol Histopathology Res* 2024;9(1):59–61.