

Chondroid syringoma: Cytomorphology of four cases and review of literature

Reetu Kundu^{1*}, Rajpal Singh Punia², Uma Handa³, Usha Dalal⁴

¹Assistant Professor, ²Professor, ³Professor and Head, Dept. of Pathology, ⁴Professor, Dept. of General Surgery, Government Medical College and Hospital, Chandigarh

***Corresponding Author:**

E-mail: reetukundu@gmail.com

Abstract

Introduction: Chondroid syringoma also known as benign mixed tumor of the skin presents as a slow growing, painless dermal/subcutaneous nodule. The cytological features of this entity have been rarely described, and are limited to a few case reports. The present study emphasizes on the cytological features of chondroid syringoma on fine needle aspiration (FNA).

Materials and Methods: A retrospective analysis of all cases of chondroid syringoma diagnosed/missed on fine needle aspiration (FNA) with subsequent histopathologic confirmation over a period of five years (2011-2015) was undertaken. FNA was done using a 23 gauge needle fitted to a 10 mL syringe mounted on Franzen's handle. Chondroid syringoma was diagnosed on cytology in 3 cases of which 2 were confined to head and neck region while 1 was in axilla. One case was misdiagnosed as fibroadenoma with secondary myxoid change on cytology.

Results: Case 1 was a 57-year-old man with a nodule in left axilla. Case 2 was a 52-year-old woman who presented with a nodule on tip of the nose. Case 3 was a 46-year-old man with nodule on upper lip. Case 4 was a 38-year-old lady with lump breast. FNA smears were cellular in all the cases and showed clusters of cells embedded in chondromyxoid stroma. Cells were round to oval with bland nuclear features and moderate amount of cytoplasm. Plentiful of chondromyxoid material was seen in the background. No cytological atypia/mitosis/necrosis was seen.

Conclusions: Chondroid syringoma can undoubtedly be diagnosed on FNA. Cytologic smears are reminiscent of pleomorphic adenoma of salivary gland. Rarity of this adnexal tumor may be responsible for the diagnosis being missed on evaluation of aspirates.

Keywords: Adnexal, Chondroid syringoma, Fine needle aspiration cytology.

Introduction

Chondroid syringoma also known as benign mixed tumor of the skin is an uncommon benign primary skin adnexal tumor having a predilection for the head and neck region⁽¹⁾. Amongst the primary cutaneous malignancies the incidence of this tumor is 0.01-0.098%⁽²⁾. It presents as a slow growing, painless dermal or subcutaneous nodule. A correct clinical diagnosis of this tumor is seldom made given the absence of peculiar presenting features. Fine needle aspiration is a minimally invasive and rapid preliminary diagnostic modality which can be used to diagnose primary adnexal neoplasms. A search through the existing literature shows that there is paucity of published data on fine needle aspiration cytology (FNAC) findings of chondroid syringoma and with only isolated case reports⁽²⁻⁵⁾. Herein, we report FNAC findings in four cases of chondroid syringoma subsequently confirmed on histopathological examination.

Materials and Methods

A retrospective analysis of all cases of chondroid syringoma diagnosed/missed on fine needle aspiration (FNA) with subsequent histopathologic confirmation over a period of five years (2011-2015) was undertaken in department of pathology, tertiary care hospital, North India. The inclusion criterion was cases diagnosed as chondroid syringoma on histopathology with prior

FNA. The exclusion criteria were; non availability of subsequent biopsy, aspiration & surgical pathology forms with incomplete relevant clinical details, cases falsely diagnosed as chondroid syringoma on FNA.

The clinical data from the cytology forms and case files of the patients was collected. FNA was performed by cyto-pathologist using 23 gauge needle fitted to a 10 ml syringe mounted on Franzen's handle. One to two passes were taken in each case. The smears were air dried for May-Grünwald-Giemsa (MGG) and wet-fixed in 95% alcohol for hematoxylin and eosin (H&E) and Papanicolaou staining. Histopathologic confirmation was available in all the four cases.

Results

The compiled results including the clinical findings and cytological diagnosis have been surmised in Table 1.

Case 1: A 57-year-old man presented with a swelling in left axilla for 3 years. The swelling measured 2 cm in diameter and was firm to hard and mobile. The clinical diagnosis was dermatofibroma. FNA was done and hemorrhagic particulate material was obtained. The cytologic diagnosis was benign adnexal tumor suggestive of chondroid syringoma.

Case 2: A 52-year-old woman presented with a swelling on tip of the nose for one and a half years. The swelling measured 0.5 cm in diameter. The clinical diagnosis was sebaceous cyst. FNA was done and

scanty hemorrhagic aspirate was obtained. On smears the cytologic diagnosis was chondroid syringoma.

Case 3: A 46-year-old man presented with a swelling just above vermilion border of upper lip for 1 year. The swelling measured 1 cm in diameter. The clinical diagnosis was sebaceous cyst. FNA was done and hemorrhagic particulate aspirate was obtained. On smears the cytologic diagnosis of benign adnexal tumor likely chondroid syringoma was suggested.

Case 4: A 38-year-old woman presented with lump left breast which had been present for 3 years. The lump measured 2.5 cm in diameter. The clinical diagnosis was fibroadenoma. FNA was done and hemorrhagic particulate aspirate was obtained. On smears the cytologic diagnosis was fibroadenoma with secondary changes of myxoid change.

Cytologic Findings: Smears in all the cases were cellular and showed sheets, clusters and few scattered cells intermingled with chondromyxoid material at places (Fig. 1a). Cells were round to oval with uniform bland nuclei, inconspicuous to tiny nucleoli and moderate amount of cytoplasm (Fig. 1b). Background

showed chondromyxoid stromal material with intermingled cells (Fig. 1c) in all the cases but in variable proportions. It was plenty in Case 1 & 2, moderate in amount in Case 3 and scanty in Case 4. Aspirate smears in Case 1 showed occasional clusters of sebaceous cells in addition. Some areas of fibrocapillary proliferation were seen in Case 4.

Areas of calcification/ossification were not seen in any case. FNAC smears in all the cases were devoid of atypia, mitosis and necrosis.

Histologic Findings: The excision biopsy specimens in all the cases showed a circumscribed tumor comprising of variably sized branching and dilated tubular lumina (Fig. 1d). The lumina were lined by double layer of cells, inner cuboidal and outer flattened. At places the lumina showed presence of eosinophilic material.

Abundant chondromyxoid stroma was seen. In addition, focal areas of calcification were seen in case 1 while islands of cartilaginous tissue were seen in case 3. The final diagnosis on histopathology in all the four cases was chondroid syringoma.

Table 1. Clinical findings and cytomorphological diagnosis in chondroid syringoma.

Case	Age & Sex	Location & Size	Duration	Clinical diagnosis	Cytological diagnosis	Histopathological diagnosis
1	57 yrs/M	Axilla, 2 cm diameter	3 yrs	Dermatofibroma	Benign adnexal tumor suggestive of chondroid syringoma	Chondroid syringoma
2	52 yrs/F	Nose, 0.5 cm diameter	1.5 yrs	Sebaceous cyst	Chondroid syringoma	Chondroid syringoma
3	46 yrs/M	Upper lip, 1 cm diameter	1 yr	Sebaceous cyst	Benign adnexal tumor likely chondroid syringoma	Chondroid syringoma
4	38 yrs/F	Breast, 2.5 cm diameter	3 yrs	Fibroadenoma	Fibroadenoma with secondary myxoid change	Chondroid syringoma

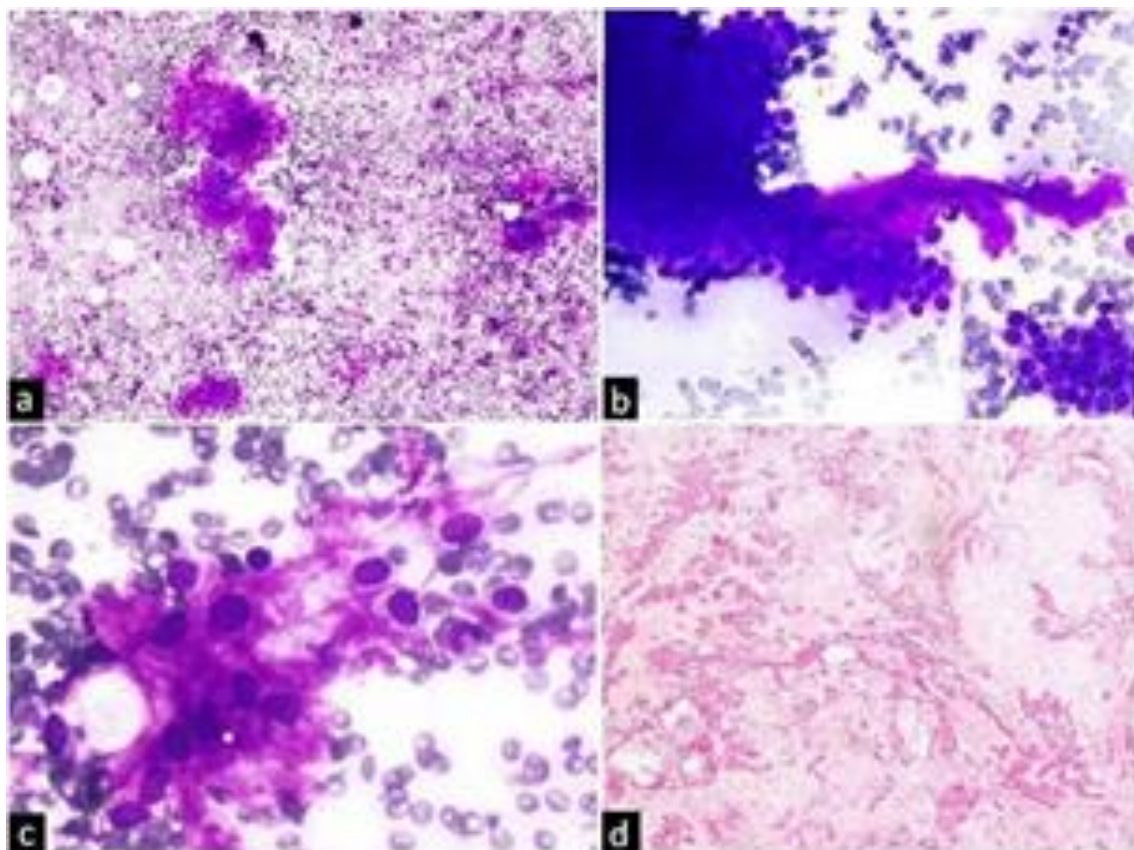


Fig. 1: a. FNAC smear showing sheets, clusters and scattered tumor cells with chondromyxoid stromal material (MGG, x100). b. Cells with round nuclei with bland nuclear chromatin (MGG x200) (Inset shows cytomorphology on higher magnification, MGG x400). c. Tumor cells embedded in chondromyxoid ground substance (MGG, x400). d. Histologic section showing variably sized branching tubular lumina at places filled with eosinophilic material. Abundant chondromyxoid stroma is well visualized (H&E x40).

Discussion

Chondroid syringoma is benign tumor of the epidermal appendages with either eccrine or apocrine differentiation⁽³⁾. Hirsch and Helwig⁽⁶⁾ coined the term 'chondroid syringoma' in 1961. These are small tumors measuring between 0.5-3 cm in diameter and are common in men than women⁽⁴⁾. Chondroid syringoma has a predilection for the head and neck region however rare locations include the axilla, trunk, abdomen, extremities and genital region⁽²⁾. Two of our cases had head and neck tumors, one had an axillary tumor and there was one case with breast lump. The clinical differentials are sebaceous cyst, dermoid cyst, neurofibroma, pilomatricoma, basal cell carcinoma and benign fibrous histiocytoma⁽³⁾.

On FNA, the aspirate is usually mucoid. The smears show clusters of uniform looking epithelial cells

with moderate to plenty of cytoplasm and myoepithelial cells with plasmacytoid appearance⁽²⁻⁵⁾. The cells are intermingled with metachromatic, chondromyxoid, ground substance. Focal nuclear atypia, representing a degenerative change has also been described⁽⁷⁾. Ossification rarely can be seen⁽²⁾. These unusual changes were not seen in our cases. Comparison of present study with cases previously reported in literature is shown in Table 2. Rarely malignant change can occur and clinching a correct cytodiagnosis then may be difficult. Mishra and Agarwal⁽⁸⁾ have reported one such case wherein the smears were highly cellular, with obvious pleomorphic dyscohesive epithelial cells forming in ill-defined cords at places in a myxoid stroma. Such features were not observed in any of our cases.

Table 2. Comparative analysis of clinical features and FNAC findings in chondroid syringoma.

Author, Year	No. of Cases	Age & Gender	Location	Size	Clinical diagnosis	Aspirate	Peculiar cytological features
Kumar ^[3] , 2010	1	20yrs/M	Nose	2cm	Dermoid cyst	Mucoid	None
Dubb & Michelo ^[7] , 2010	3	32yrs/F	Scalp	2cm	None	Not mentioned	Focal nuclear atypia in one case
		23yrs/M	Scalp	2cm			
		18yrs/F	Upper lip	0.5cm			
Akhtar et al ^[11] , 2016	1	68yrs/F	Breast	4x3cm	Not mentioned	Not mentioned	Calcification
Gottschalk-Sabag & Glick ^[4] , 1994	1	82yrs/F	Axilla	1.3x1x1cm	Metastasis from thyroid	Not mentioned	Tubular conformations
Rogers et al ^[2] , 2016	1	67yrs/F	Axilla	1cm	Lymph node/cyst	Blood tinged	None
Siddaraju et al ^[12] , 2009	1	43yrs/F	Nose	0.8x0.8cm	Basal cell carcinoma	Thick gelatinous material	Occasional perinuclear halos, conspicuous nucleoli
Mishra & Agarwal ^[8] , 1998	1	40yrs/F	Scalp	5x4x2cm	Appendage tumor	Hemorrhagic with gelatinous material	Pleomorphic cells, ill-formed cords, dyschesiveness; Malignant chondroid syringoma
Present study	4	57yrs/M	Axilla	2cm	Dermatofibroma	Hemorrhagic particulate	None
		52yrs/F	Nose	0.5cm	Sebaceous cyst		
		46yrs/M	Upper lip	1cm	Sebaceous cyst		
		38yrs/F	Breast	2.5cm	Fibroadenoma		

FNAC smears in chondroid syringoma show a biphasic tumor containing both epithelial and mesenchymal elements reminiscent of pleomorphic adenoma of salivary glands⁽⁹⁾. The cytologic differential diagnoses depending upon the relative preponderance of one component over the other include carcinomas with plentiful mucinous stroma, soft tissue neoplasms with chondroid/myxoid foci, spindle cell tumors, myoepithelial tumors and carcino-sarcoma^(5,7).

On FNAC nerve sheath tumors show spindled cells with elongated nuclei showing kinking and presence of fibrillary intercellular stroma. Cytosmears in leiomyoma with myxoid change show typical benign smooth muscle cells with cigar shaped nuclei having blunt ends. Fibrohistiocytic tumors on cytology show multinucleated giant cells and some inflammatory cells

in the background in addition to the tumor cells. Marked anisocytosis and anisokaryosis in dispersed proliferating fibroblasts with bi-nucleation and multi-nucleation is seen in nodular fasciitis on FNA smears. Aspirates in myxomas have scanty cellularity with slender tumor cells showing long cytoplasmic processes and rarely pose a diagnostic difficulty. Myxofibrosarcoma, low grade shows tumor tissue fragments with branching vessels embedded in a myxoid matrix on cytology. Carcinomas with background mucin and carcinosarcomas can be distinguished on FNAC on the basis of obviously malignant cytological features seen in epithelial cells and both epithelial and mesenchymal cells respectively.

Careful evaluation of cytomorphologic features usually suffices to arrive at a correct diagnosis in a good number of cases. FNA is quick, minimally invasive and cost effective preliminary diagnostic modality as compared from biopsy which is an invasive procedure. Special stains like mucicarmine and Alcian blue to demonstrate myxoid stroma may be helpful in some cases⁽¹⁾. Papanicolaou stain is good for visualization of cellular features. CK and EMA are immunomarkers for the epithelial component and the myoepithelial component is highlighted using S-100, neuron-specific enolase, glial fibrillary acidic protein and vimentin.

A vast majority of chondroid syringomas are benign and malignant chondroid syringoma is extremely rare with only about 40 cases reported till date⁽¹⁰⁾. Majority of these arise de novo, however tumors developing in a previous benign counterpart are on record. These occur more commonly in the extremities than on head and neck and are invariably larger than 3 cm with a history of rapid increase in size⁽⁸⁾. During FNA the malignant focus may be missed and the aspirates in such a case will be misdiagnosed as benign. An excision biopsy of all lesions hence is the recommended approach.

Conclusion

Chondroid syringoma can be diagnosed on fine needle aspiration cytology without posing much of a difficulty. Cytologic smears bear resemblance to pleomorphic adenoma of salivary gland. It should be considered as a differential in small swellings especially in the head and neck region. The diagnosis is often not thought and missed considering the rarity of this adnexal neoplasm.

References

1. Ahmed TSS, Priore JD, Seykora JT. Tumors of the epidermal appendages. In: Elder DE, Elenitsas R, Johnson BL, Murphy GF, eds. *Lever's Histopathology of the skin*. 10th ed. Philadelphia: Lippincott Williams & Wilkins; 2005:851-909.
2. Rogers R, Zhou F, Grunes D, Shapiro RL, Bannan M, Simsir A, Leung A. Chondroid syringoma of the axilla: An unusual tumor diagnosed by fine needle aspiration. *Diagn Cytopathol* 2016;44(4):342-6.
3. Kumar B. Chondroid syringoma diagnosed by fine needle aspiration cytology. *Diagn Cytopathol* 2010;38(1):38-40.
4. Gottschalk-Sabag S, Glick T. Chondroid syringoma diagnosed by fine-needle aspiration: a case report. *Diagn Cytopathol* 1994;10(2):152-5.
5. Srinivasan R, Rajwanshi A, Padmanabhan V, Dey P. Fine needle aspiration cytology of chondroid syringoma and syringocystadenoma papilliferum. A report of two cases. *Acta Cytol* 1993;37(4):535-8.
6. Hirsch P, Helwig EB. Chondroid syringoma: Mixed tumor of skin, salivary gland type. *Arch Dermatol* 1961;84:177-89.
7. Dubb M, Michelow P. Cytologic features of chondroid syringoma in fine needle aspiration biopsies: a report of 3 cases. *Acta Cytol* 2010;54(2):183-6.
8. Mishra K, Agarwal S. Fine needle aspiration cytology of malignant chondroid syringoma: a case report. *Acta Cytol* 1998;42(5):1155-8.
9. Le Boit PE, Burg G, Weedon D, Sarasin A, editors. *Pathology and genetics of skin tumors*. World Health Organization Classification of Tumors. Leon: IRAC Press; 2003. P.147-8.
10. McKee PH, Calonje E, Granter S, editors. *Pathology of the skin with clinical correlations*. Third edition, Volume 2. Philadelphia: Elsevier Mosby; 2005. P.1602-9.
11. Akhtar M, Rangwala M, Saxena D, Bhisikar V, Philipose A. Chondroid syringoma of breast: a case report with literature review. *European Journal of Pharmaceutical and Medical Research* 2016;3(2):298-300.
12. Siddaraju N, Murugan P, Wilfred CD, Choudhury N, Basu D. Preoperative cytologic diagnosis of chondroid syringoma. *Acta Cytol* 2009;53:607-10.