

Carcinoid Tumor of the appendix: an incidental finding in child

Dhiraj B. Nikumbh^{1,*}, Sudhir Singhavi², Shirish R Gondane³, Kishor H Suryawanshi⁴, Poonam S Pagare⁵

^{1,4}Associate Professor, ³Assistant Lecturer, Dept. of Pathology, JMF'S ACPM, MC, Dhule, ²McH, Consultant Paediatric Surgeon, Dhule, ⁵Consultant Pathologist, Hi-Tech Diagnostics, Dhule

***Corresponding Author:**

E-mail: drdhirajnikumbh@rediffmail.com

Editor

With reference to carcinoid tumor of the appendix in a child, we want to share our experience and enlighten the occurrence of this carcinoid tumor in a child as an incidental finding in routine appendectomy specimen. Carcinoid tumors are rare neuroendocrine tumours with most common frequency in the appendix⁽¹⁾. In children, they are less common with a reported incidence of 0.08%⁽²⁾. To the best of our knowledge, only handful of cases of carcinoid tumor in children has been reported in Indian sub-continent. Although rare, carcinoid tumor is considered the most common type of appendiceal primary malignant lesion and usually diagnosed incidentally in appendectomy specimen and is found in 0.3-0.9% of patients undergoing appendectomy⁽³⁾. Despite the fact that it is among the most frequently occurring carcinoids in surgical practice with rare pre-operative diagnosis, most of surgeons may encounter only one or two such lesions during their career⁽⁴⁾. Hence it is important to know correct management of such a rare tumor⁽⁵⁾. Personally it was the first time; we encountered incidental histopathological diagnosis of carcinoid in appendix in 12 years of Pathology practice.

Routinely we received the various histopathological specimens including appendectomy specimen like this case. An emergency appendectomy was done and specimen of an 11 year old child was received and grossing was done. The patient was operated for perforation of appendix with clinical manifestations and diagnosis on imaging modalities. Rest of the abdominal and pelvic organs were normal in ultrasonography of abdomen and pelvis. We received appendectomy specimen measuring 6cms in length and 0.8cms in diameter. External surface showed a golden brown defect on tip of appendix covered with exudation. On cut surface showed a tiny whitish area measuring 0.6x0.3 cms at tip of appendix with perforation and covered with exudation. Serial sections were cut and to our surprise we found carcinoid tumor in the appendix. Microscopical examination showed features of acute perforative appendicitis with tumor islands in submucosa and muscular layer. The whole of epithelium was ulcerated and replaced by inflamed granulation tissue with tumor seen in submucosa and muscularis propria (Fig. 1). The tumor was composed of solid nests, cords and islands of uniform population of round to oval cells with open stippled salt and pepper

chromatin and eosinophilic cytoplasm (Fig. 2, 3). All the surgical margins including proximal surgical margin was 0.5 cm away and free from tumor. This was not diagnosed pre-operatively and not on even gross and cut sections. It was ultimately diagnosed on histopathology. Incidental finding of carcinoid tumor in 11 year child was reported in routine appendectomy specimen. The patient was free from disease and there was no evidence of metastasis in long term follow up. Post-operatively, we performed the 5-HIAA (hydroxyindole acetic acid), metabolite of neuroendocrine cells in urine was within normal limits. Otherwise it will be very high in metastasis of carcinoid tumor. Neuroendocrine cells are related to Enterochromaffin cells that are placed in the GIT and associated with bronchial tree-carcinoids. Post-operative chest CT scan was done and it was within normal limits like that of GIT.

Regarding treatment of carcinoid tumor, size of the tumor is important factor⁽⁶⁾. For tumours which are < 1 cm in diameter, simple appendectomy is sufficient as in our case whereas when the tumor size is >2 cms, an ileocecal resection or even hemicolectomy is indicated⁽⁶⁾. Immunohistochemical (IHC) analysis according to standard procedures with chromogranin A and synaptophysin antibodies is recommended to confirm the diagnosis. The proliferation marker Ki-67 and the number of mitoses are very low in most appendicular endocrine tumors(AETs). Their relevance is not as precisely defined for AETs as it is for other endocrine tumors⁽⁷⁾. We were unable to perform the IHC, in view of block was exhausted in serial sections and to our surprise it was an incidental finding. On regress of the specimen, we were not able to find the tumor. Tumor subtyping by immunohistochemistry is not necessary on a routine basis for appendicular carcinoids, in view of its incidental findings and small size⁽⁷⁾. The goal of this case discussion is to describe an 11 year old female with carcinoid of appendix diagnosed as incidental finding in histopathological examination of appendectomy specimen. Almost 70-90% of tumours are discovered incidentally during histopathological examination of resected appendix by pathologist⁽⁶⁾ as in present case also. The prognosis of carcinoid tumor of appendix is excellent in children as the tumor is overall small in size and less aggressive without evidence of metastasis⁽¹⁾. In view of its incidental diagnosis of such rare tumours like carcinoid,

we highlighted the role of histopathology in every appendectomy specimen even if the appendix is vestigial organ.

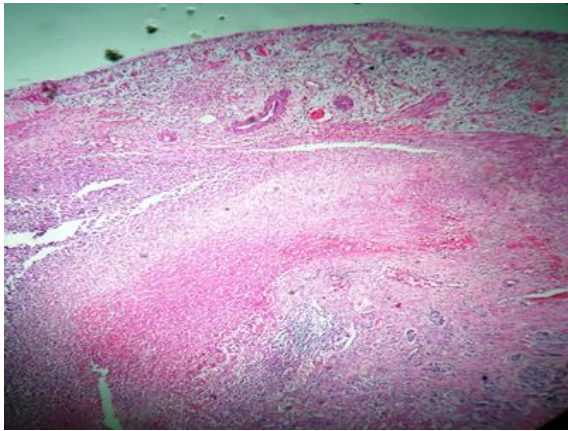


Fig. 1: Photomicrograph showing ulcerated epithelium and inflamed granulation tissue with tumor in Submucosa and muscularis propria (H&E, x100)

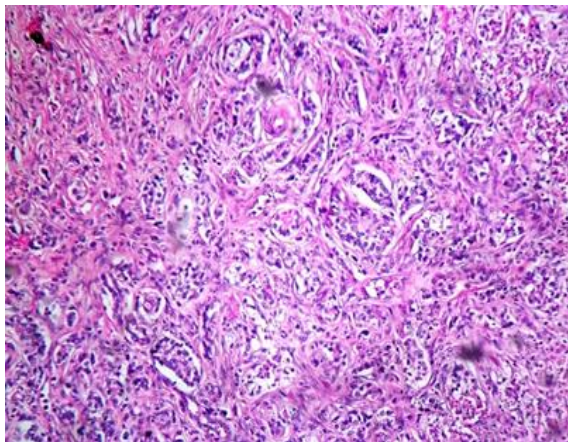


Fig. 2: The tumor with nests, cords of round to oval tumor cells with stippled salt and pepper chromatin and eosinophilic cytoplasm (H & E, x100)

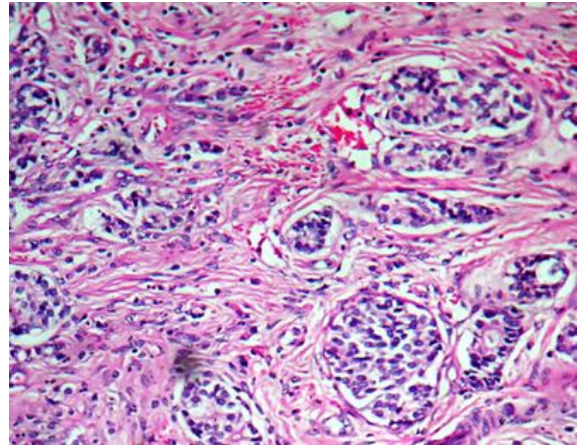


Fig. 3: The Tumor with nests, cords of round to oval tumor cells with stippled salt and pepper chromatin and eosinophilic cytoplasm (H & E, x400)

References

1. Vani BR, Thejaswini MV, Kumar DB, Murthy SV, Gethamala K. Carcinoid tumor of appendix in a child: A rare case at an uncommon site. *Afr J Paediatr Surg.* 2014;11(1):71-73
2. Dali' Igna P, Ferrari A, Luzzatto C, Bisago G, Casanova M, Alaggio R, et al. Carcinoid tumor of the appendix in childhood. The experience of two Italian institutions. *J Peadiatr Gastroenterol Nutr.* 2005;40:216-9.
3. Goede AC, Caplin ME, Winslet ME. Carcinoid tumor of the appendix. *Br J surg.* 2003;90:1317-22.
4. Sandor A, Modlin IM. A retrospective analysis of 1570 appendiceal carcinoids. *Am J Gastroenterol.* 1998;93:422-428.
5. Tchana-Jato V, Detry O, Polus M, Thiry A, Detroz B, Maweja S, et al. Carcinoid tumor of the appendix: A consecutive series from 1237 appendectomies. *World J Gastroenterol.* 2006;7(12):6699-6701.
6. Pelizzo G, La Riccia A, Bonvier R, Chappunis JP, Frandella A. Carcinoid tumor of the appendix in children. *Pediatr Surg Int.* 2001;17:399-402.
7. Lydia Deschamps and Anne Couvelard. Endocrine Tumors of the Appendix: A Pathologic Review. *Archives of Pathology & Laboratory Medicine.* 2010;134(6):871-875.