

## Histopathology of endometrium in dysfunctional uterine bleeding

Divya K. N.<sup>1\*</sup>, Jayashree K.<sup>2</sup>, Bharath C.<sup>3</sup>

<sup>1</sup>Associate Professor, <sup>2</sup>Professor, <sup>3</sup>Professor and Head, Dept. of Pathology, VIMS, Ballari

**\*Corresponding Author:**

E-mail: divyaaural@yahoo.co.in

---

### Abstract

**Introduction:** Abnormal uterine bleeding is a common condition affecting women of reproductive age that has significant social and economic impact. Dysfunctional uterine bleeding (DUB) is defined as abnormal uterine bleeding in the absence of organic disease. Dysfunctional uterine bleeding is one of the most commonly encountered gynaecological problems.

**Objectives:** This study is done to evaluate the histopathological pattern of the endometrial biopsies of patients with dysfunctional uterine bleeding and its correlation with clinical data.

**Methods:** The present prospective study included evaluation of 104 cases of dysfunctional uterine bleeding in the Department of Pathology, Vijayanagar Institute of Medical Sciences, Ballari, over a period of 1 year, from January 2015 to December 2015. Women presenting with abnormal uterine bleeding were included in the study. Those women in which bleeding is secondary to systemic causes, organic causes and due to cervical and vaginal causes were excluded. The specimens were processed, embedded and cut into sections of 3-4 microns. The histopathological patterns were studied

**Results:** Age distribution varied from 18 years to 70 years, majority of the patients were between 21 to 30 years. Among the cases of DUB, proliferative phase accounted for 66.3% and secretory phase accounted for 21.3%. 9 cases (8.6%) of atrophic endometrium, two cases (1.9%) of irregular shedding and two cases of luteal phase insufficiency were received.

**Conclusion:** Dysfunctional uterine bleeding is a common and debilitating condition in women of reproductive age. Endometrial biopsy could be effectively used as the first diagnostic step in DUB and thus ensures correct management.

**Keywords:** AUB, DUB, Endometrial biopsy, Histopathology, Patterns.

---

### Introduction

Menstrual dysfunction is the cause of discomfort, inconvenience and disruption of a healthy life style, which affects millions of women in both the developed and developing countries. Successful management of dysfunctional uterine bleeding requires a rational organized approach.<sup>[1]</sup> Excessive menstrual bleeding has several adverse effects, including anaemia and iron deficiency, reduced quality of life, and increased healthcare costs because it is a major indication for referral to gynaecological outpatient clinics.<sup>[2]</sup> About 25-30% of abdominal hysterectomies are done for abnormal uterine bleeding. Decades have not changed this picture.<sup>[3]</sup> Dysfunctional uterine bleeding is a form of abnormal uterine bleeding for which no detectable pathology is found. It is the abnormalities of endometrial development and maturation, which are secondary to ovarian dysfunction. Dysfunctional uterine bleeding is defined as pathological bleeding from uterus unexplained on the basis of inflammation, neoplasia or pregnancy within the uterus.<sup>[4]</sup> A study showed high incidence of apparently normal endometrium in cases of Dysfunctional uterine bleeding.<sup>[5]</sup> The present study is undertaken to evaluate the histopathological patterns of the patients presenting with dysfunctional uterine bleeding.

### Methodology

The present study was a prospective study, conducted in the Department of Pathology, Vijayanagar Institute of Medical Sciences, Ballari for a period of one

year from January 2015 to December 2015. Patients of dysfunctional uterine bleeding attending outpatient department, admitted in OBG Department of VIMS, Ballari and other peripheral hospitals formed the source of data. Relevant clinical details were collected.

**Inclusion Criteria:** Women presenting with abnormal uterine bleeding.

**Exclusion criteria:**

1. Abnormal bleeding secondary to systemic diseases like coagulation disorders, hypothyroidism and cirrhosis.
2. Abnormal bleeding secondary to organic causes within the uterus like infection, pregnancy and neoplasia.
3. Abnormal bleeding secondary to cervical and vaginal lesions.

**Timing of Endometrial Biopsy:** The best time for observing cyclical changes is between 7<sup>th</sup> and 11<sup>th</sup> postovulatory days. If tuberculosis is suspected, biopsy may be done on 12<sup>th</sup> and 13<sup>th</sup> postovulatory days. However in presence of abnormal uterine bleeding, it may be impossible to select the accurate time for biopsy.<sup>[6]</sup>

The material consisted of endometrial biopsy and dilatation and curettage of the patients presenting with dysfunctional uterine bleeding.

The specimens were fixed in 10% formalin and examined grossly for amount, colour and consistency. They were processed using automatic tissue processor

and embedded in paraffin, according to the procedures given in the handbook of histopathology and histochemical technique by Culling.<sup>[7]</sup> Sections of 3-5  $\mu$  were cut using rotary microtome and stained with Hematoxylin & Eosin.

## Results

A total number of 108 samples of Dysfunctional Uterine Bleeding were received in the Department of Pathology, Vijayanagar Institute of Medical Sciences, Ballari during the study period of 1 year, from January 2015 to December 2015. Among 108 cases, 4 biopsies were inadequate, showing only the fragments of blood clots without any glands. So, a total of 104 cases were taken for histopathological study.

**The following data were recorded and analyzed:** In the present study, age distribution varied from 18 years to 70 years. Majority of the patients were between 21 to 30 years (36.5%), followed by the age groups of 31 to 40 years (24%). Mean age of presentation was 28.5 years. The parity of the patients varied from nullipara to para more than 4. 19 were nulliparous. Maximum numbers of patients were of para 3.

Metrorrhagia was the main symptom making 34.6%. Menorrhagia of different durations was seen in 30 women, making 28.8%. Dysmenorrhoea was associated with DUB in 50 cases accounting to 48%. 10 cases of postmenopausal bleeding were encountered in the study period.

**Table 1: Distribution of DUB**

Type	Number	Percentage
<b>Proliferative Phase</b>	<b>69</b>	<b>66.3</b>
Early Proliferative	34	32.6
Mid Proliferative	27	25.9
Late Proliferative	8	7.7
<b>Secretory Phase</b>	<b>22</b>	<b>21.3</b>
Early Secretory	11	10.6
Mid Secretory	4	3.8
Late Secretory	7	6.7
<b>Irregular Shedding</b>	<b>2</b>	<b>1.9</b>
<b>Luteal phase insufficiency</b>	<b>2</b>	<b>1.9</b>
<b>Atrophic Endometrium</b>	<b>9</b>	<b>8.6</b>
<b>Total</b>	<b>104</b>	<b>100</b>

Proliferative phase was the most common pattern detected in the patients of DUB, which accounted for 66.3%. Biopsy was taken in postovulatory period and hence, these patients were having an ovulatory cycle. Many of the cases of dysfunctional uterine bleeding were due to absence of ovulation. It was followed by secretory phase of endometrium 21.3%. (Table 1). Two cases each of irregular shedding and luteal phase defect were detected. Atrophic endometrium accounted for 8.6%.

**1. Proliferative Phase:** Early Proliferative phase of endometrium showed round and short narrow glands, lined by cuboidal to columnar epithelium in a compact stroma. Mid Proliferative phase showed longer curved glands. Variable amount of stromal edema was noted. The stromal cells showed mitotic activity. Late Proliferative phase showed tortuous glands with pseudo stratification. The stroma was dense, showing numerous mitotic figures.

Many of the cases of dysfunctional uterine bleeding are due to absence of ovulation. An ovulatory cycles are caused by hyper estrogenic state. Hyper estrogenic state may be due to increased levels of estrogen or due to its unopposed action.<sup>[8]</sup> Clinically the patient may present with oligomenorrhoea, amenorrhoea, infrequent heavy vaginal bleeding and infertility.<sup>[9]</sup>

Histologically, the absence of ovulation manifests as prolonged proliferative phase. Mitotic activity continues beyond fourteenth day, glandular stratification persists and stroma remains immature and cellular. Characteristically the secretory vacuoles are absent.<sup>[10]</sup> The withdrawal bleeding at the end of an ovulatory cycle is due to fall of estrogen level. Curettage at the menstrual phase yields scant sample. The glands are inactive with no evidence of secretory activity.<sup>[11]</sup> The persistent and prolonged hyper estrogenic state ultimately leads to endometrial hyperplasia.<sup>[12]</sup>

**2. Secretory Phase:** Early secretory phase showed sub nuclear vacillation of glandular epithelium. The stroma showed moderate oedema. Mid secretory glands showed distension of the lumen with secretions. The glands were lined by tall columnar epithelium, with regular oval basal nuclei. The stroma showed marked oedema. Late secretory glands showed irregular serrated outline. They were closely packed, without stromal oedema. Spiral arteries and pre-decidual stromal cells were also seen.

**3. Luteal phase defect:** Luteal phase defect is defined as improper development of endometrium for normal notation.<sup>[13]</sup> It has been reported that secretory endometrium to be frequently associated with dysfunctional uterine bleeding, indicating that anovulation is not necessarily a feature of the disorder.<sup>[14]</sup>

The abnormalities of progesterone secretion may be due to delayed progesterone secretion, decreased level of progesterone, gradual rise in the level instead of rapid rise, premature decrease in progesterone level, abnormal persistence of an active corpus luteum beyond 14 days, relative deficiency of progesterone associated with hyperestrogenism. These different types of abnormalities of progesterone secretion result in several patterns of luteal phase insufficiencies.<sup>[15]</sup>

**A. Luteal phase insufficiency with coordinated delay:** Endometrium shows a coordinated delay of both glandular and stromal maturation. The endometrium lags

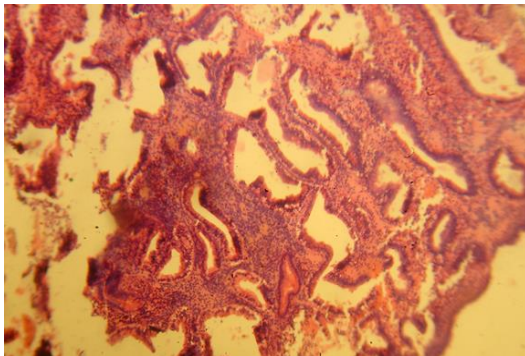
behind at least by 2 days. A repeat biopsy is needed to confirm the diagnosis.

**B. Luteal phase insufficiency with dissociated delay:** In this type the biopsy is scant with small sparse narrow glands. Stroma is more mature compared to glands with the appearance of few spiral arterioles. This type of pattern is seen in associated estrogen deficiency.

When the estrogen levels are normal, the luteal insufficiency is manifested by variations in the glandular maturation. Small round glands with basal nuclei and tall tortoise glands with secretory activity can be seen in the same biopsy. This variation in maturation is called Irregular Ripening.<sup>[16]</sup>

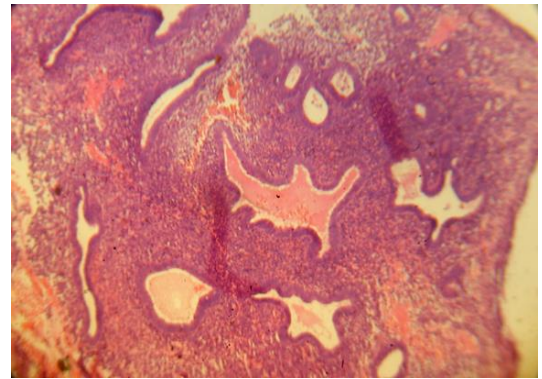
**C. Premature failure of corpus luteum:** Premature failure of corpus luteum leads to a short luteal phase. It is recognized in biopsy by finding of focal stromal hemorrhage in an immature endometrium.<sup>[17]</sup>

In two patients where the date of last menstrual period was mentioned, luteal phase deficiency was evident. The biopsy was done on the twenty fourth day but the glands showed intraluminal secretions, corresponding to twentieth day. In the second case, biopsy was done on twenty first day and the glands showed secretory vacuoles corresponding to seventeenth day on the histopathology slide. Elongated glands showed orderly row of nuclei above and large vacuoles below (Fig. 1)



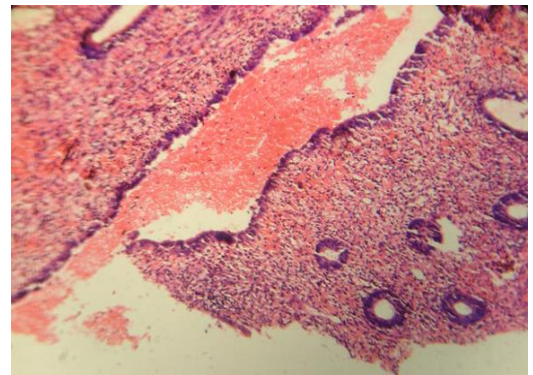
**Fig. 1: Luteal phase defect-Subnuclear vacuolation seen in the glands corresponding to seventeenth day of the cycle, while the biopsy is obtained on twenty first day (H & E) x 10**

- a. **Irregular shedding:** Irregular shedding is due to a lag in the shedding of the secretory endometrium. Both proliferative and secretory glands were seen. Necrotic fragments were seen. The patient presented with prolonged and increased bleeding for 12 days (Fig. 2).



**Fig. 2: Irregular Shedding-Both proliferative and secretory glands (H & E) x 10**

- b. **Atrophic endometrium:** If the ovaries are removed in the childbearing age like by X-ray irradiation, by chemical toxins, then the endometrial atrophy results. It is seen in normal premenarchal child and postmenopausal women. It is stated that atrophied endometrium is the predominant cause of postmenopausal uterine bleeding with an incidence of 82%.<sup>[18]</sup> Atrophic Endometrium accounted for 8.6% in the present study. Microscopy showed sparse small glands lined by cuboidal epithelium. Stroma contained small spindle cells. (Fig. 3)



**Fig. 3: Atrophic endometrium-small sparse glands in a stroma containing spindle cells (H & E) x 10**

## Discussion

Functional uterine bleeding is a term collectively used to indicate a group of disorders associated with endometrial bleeding not related to neoplasia, pregnancy, induction or trauma. Dysfunctional uterine bleeding may be due to low estrogen, high estrogen and abnormalities in the relative proportions of estrogen and progesterone<sup>[19]</sup> Although the dating of normal endometrium is relatively simple, the dating of an abnormal endometrium is more difficult. In abnormal biopsies, there is a difference in the developmental patterns in different areas of the biopsy and divergence between appearance of glands and stroma. The accepted rule is that the most advanced date must be assigned.<sup>[14]</sup>

In the present study 104 patients with DUB were studied and data were compared with standard studies.

The highest incidence of AUB in Kanakadurgamba<sup>[20]</sup> and Joshi-Deshapande<sup>[5]</sup> was in the age group of 21-30 years. In the present study also the highest incidence was in 21-30 years age group. In Dass A<sup>[21]</sup> series, the highest incidence was in the age group of 31-40 years.

The second commonest age group was between 31-40 years, in all the 3 series. Incidence of AUB below 20 years was 9.3% in the present study, which was similar to Joshi-Deshapande<sup>[5]</sup> study (9.7%). The percentage of AUB below 20 years in Kanakadurgamba<sup>[20]</sup> study was 14.6%. The percentage of patients above 51 years in the present study was 9.2%, whereas it was 1.9% in Joshi-Deshapande series. Dass A<sup>[21]</sup> reported an incidence of 4.3% in their study.

41% of patients were of 2<sup>nd</sup> to 4<sup>th</sup> para in the present study. This correlates with the study by Joshi and Deshapande<sup>[5]</sup> who reported 35% of patients. The percentage of nullipara in Bhattacharji<sup>[22]</sup> study and Joshi and Deshapande<sup>[5]</sup> study was 18.8% and 25.9%. This correlates with the present study (18.5%). Pilli GS and others reported a lower incidence of 6% in their study.<sup>[23]</sup> The percentage of multipara in Joshi and Deshapande study was 61.6%. In the present study the percentage of multipara was 59.5%.

In the present study, Metrorrhagia outnumbered the other forms of bleeding accounting to 34.6%. In their study Domingo and others<sup>[24]</sup> showed metrorrhagia as the commonest presenting complaint, which accounted for 33.8%. Moghal N.<sup>[25]</sup> reported a higher incidence of 48% in his study. The next common symptom in the present study was menorrhagia, constituting 28.8%, which was comparable to Domingo study 26.6%. Polymenorrhoea was seen in 7.1% of cases in the present study. It was seen in 17.2% of cases in Domingo study and 2% of cases in Moghal study.

Proliferative Phase of endometrium accounted for majority of the cases of DUB, in all the studies. Joshi-Deshapande<sup>[5]</sup> reported 60.3% and Dass A<sup>[21]</sup> reported 59.7%. In the present study proliferative phase formed 66.3%. Proliferative phase is predominantly seen in all age groups. Joshi-Deshapande observed a high incidence of apparently normal endometrium in cases of dysfunctional uterine bleeding. Many cases of dysfunctional uterine bleeding were due to an ovulatory cycles. These cases presented as prolonged proliferative phase on histopathological examination. A correlation with the date of last menstrual period and the date of biopsy is thus mandatory, for correct treatment.

The next common pattern of DUB was secretory phase. In the present study secretory phase accounted for 21.3%, which is comparable to Joshi-Deshapande (19.6%) study. Dass A reported a higher incidence of 32.8%. Cases of luteal phase defects manifest as secretory phase on microscopic examination. Dating of the endometrium and correlation with the date of last menstrual period is mandatory to come to a proper diagnosis. A date obtained from the endometrial biopsy should be more than two days retarded before the

diagnosis of underdeveloped secretory endometrium is made.

In the present study 87.6% of endometrial biopsies showed proliferative and secretory pattern. Bhattacharji<sup>[22]</sup> observed that in cases of dysfunctional uterine bleeding, a large number of biopsies show no departure from the normal. Abnormal bleeding can occur from any type of endometrium. It is thus evident that there is no constant relationship between the pattern of endometrium and type of bleeding in dysfunctional uterine bleeding.

Dass A reported 2.5% of cases of irregular shedding, which correlated with the present study (1.9%). Joshi-Deshapande reported higher percent (10.6%) of irregular shedding.

8.6% of patients of DUB presented with atrophic endometrium in the present study. Bleeding is seldom profuse in atrophic endometrium. Joshi-Deshapande (3.9%) and Dass A (2.5%) reported lower percentage of atrophic endometrium. Patients aged above 50 years formed 9.2% in the present study but only 1.9% and 4% in Joshi-Desapande and Dass A study. This higher percentage of elderly patients was the reason for increased incidence of atrophic endometrium in the present study.

## Conclusion

The Microscopic examination of endometrium bears the pivotal role in diagnosing the various etiopathological factors in the cases of dysfunctional uterine bleeding. Proliferative phase out numbered dysfunctional uterine bleeding in reproductive age group, while atrophic endometrium is the cause for DUB in postmenopausal bleeding. An ovulatory cycles which form the bulk of DUB, present as prolonged proliferative phase on histopathological examination. In luteal phase defects, secretory endometrium lag behind at least by two days. Proper clinical data, including the date of last menstrual period is mandatory for the interpretation of endometrial samples. Endometrial biopsy helps to facilitate accurate diagnosis and individualized treatment options.

## References

1. Joan Pitkin. Dysfunctional uterine bleeding. *BMJ* 2007; 334-1110.
2. Mahapatra M, Mishra P. Clinicopathological evaluation of abnormal uterine bleeding. *J Health Res Rev* 2015; 2:45-9.
3. Youssif SN and Macmillan DN, Outpatient endometrial biopsy. *British J Hospl Med.* 1995; 54(5), 198-201.
4. Khan PK. Dysfunctional Uterine Bleeding. *J Obstet Gynecol India.* 1964; 14; 348- 354.
5. Joshi SK and Deshapande DH, Clinicopathological study in 274 case of DUB. *J Obstet Gynecol India.* 1964; 14; 360-371.
6. Dallenbach G and Hellwegh. *Histopathology of the endometrium.* New York: Springer-Verlag; 1993: 325-327.

7. Culling CEA, Allison RT and Barr WT. Cellular Pathology Technique. London: Bitter worth; 1985: 77-78.
8. Doraiswami S, Johnson T, Rao, Rajkumar A and Panicker V K. Study of endometrial pathology in abnormal uterine bleeding. J Obstet Gynecol India 2011; 61; 426-429.
9. Maheshwari V, Chakrabarti AK, Tyagi SP, Sharma R, Alam K and Mohsin S. Endometrial changes in abnormal uterine bleeding. J Obstet Gynecol Ind. 1996; 46 (3); 389-94.
10. Altchek A, DUB in adolescence. Clinical Obstet Gynecol, 1977; 20(3): 633-650.
11. Kilbourn CL and Christine RS, AUB: Diagnostic considerations, management options. Postgrad Med. 2001; 109 (1); 137-150.
12. Hofmeister FJ, Vondrak B and Barbo D. The value of endometrial biopsy. Am J Obstet Gynecol. 1996; 95; 91-98.
13. Sloboda L, Molnar E, Popovic Z, Zivkovic S. Analysis of pathohistological results from the uterine mucosa 1965-1998 at the gynecology department in Senta Med Pregl. 1999 Jun-Aug; 52(6-8): 263-265.
14. Moszkowski E, Woodruff DJ, Seegar GE. The inadequate luteal phase, Am J Obstet Gynecol, 1962; 83 (3): 363-372.
15. Hatasak H, Evaluation of AUB. Clinic Obstet Gynecol, 2005;48 (2), 258-273.
16. Sheppard BL, The pathology of DUB, Clinic Obstet Gynecol 1984; 11, 227-235.
17. Rosenfeld DL, Chudow S and Bronson RA, Diagnosis of Luteal Phase Inadequacy. Obstet Gynecol, 1980;56(2), 193-196.
18. Choo YC, Mak KC, Hsu, Wong TS And Ma HK, Postmenopausal uterine bleeding of nonorganic cause. Obstet Gynecol, 1985; 66: 225-27.
19. Dangal G. A study of endometrium of patients with abnormal uterine bleeding at Chitwan valley. Katmandu Univer Med J. 2003 Vol 1(2): 110-112.
20. Kanakadurgamba K and Rao S, A clinical and histopathological review of dysfunctional uterine bleeding. J of obstet Gynecol Ind. 1964; Vol 14: 380-386.
21. Dass A and Chugh S, Dysfunctional uterine bleeding – A Clinicopathological study. J Obstet Gynecol India. 1964;14; 348-354.
22. Bhattacharji S. Dysfunctional uterine bleeding- correlation of endometrial pattern with clinical behavior. J obstet gynecol Ind.1964; 14; 372-379.
23. Pilli GS, Sethi B, Dhadeel A and Prakash R. Dysfunctional uterine bleeding-A study of 100 cases. J Obstet Gynecol Ind. 2002; Vol 52 (3); 87-89.
24. Domingo B and Hadley JO Endometrial Biopsy-pathologic findings in 3,600 biopsies from selected patients. A J Clinic patho.1975: Vol 63; 9-15.
25. Moghal N. Diagnostic value of endometrial curettage in abnormal uterine bleeding a histopathological study. J Pak Med Assoc. 1997; 47(12):295-299.