

## Evaluation of Effectiveness of Visual Inspection with Acetic Acid (VIA) Method for Screening of Cervical Lesions

Karumanchi Pushpalatha<sup>1\*</sup>, Souujanya Rakam<sup>2</sup>, Sreedevi Chowkula<sup>3</sup>

<sup>1</sup>Associate Professor, <sup>2,3</sup>Assistant Professor, Dept. of Pathology, Maheshwara Medical College, Chitkul, Sangareddy, Hyderabad

\*Corresponding Author:

E-mail: dr.kp.latha@gmail.com

### Abstract

**Introduction:** Cervical cancer is the most common cancer among women in developing countries. Cervical cytology often referred to as Pap smear is a proven and reliable screening method. It requires large number of steps and is difficult to implement in low resource setting. Visual inspection with acetic acid application is an alternative method which is cost effective, simple and can be easily implemented in under-resourced areas. At the same time its sensitivity and specificity are more or less same as that of Pap smears.

**Aims and Objectives:** To compare visual acetic acid test (VIA) with Pap smear test for screening of cervical lesions in unhealthy cervixes.

**Materials and Methods:** This was a prospective hospital based study carried out over a period of six months from March to August 2016 in the departments of Pathology and Obstetrics and Gynecology, Maheshwara Medical College, Hyderabad. The study group consisted of 523 women, having unhealthy cervix on direct inspection. Pap smears were collected and then VIA test was performed on all subjects. The positive VIA tests were compared with the Pap smear reports.

**Observations and Results:** Women less than 40 years comprised 63 % cases.

Among pap smears, LSIL was more common and reported in 15 cases (55.56 %).

Out of total 523 cases, 19 cases (3.63 %) showed the SIL /squamous intraepithelial lesions. The positive cytology was seen in 21 cases (4.01 %) including both dysplastic and malignant conditions.

VIA test was positive in 27 cases (5.16 %) and showed 100 % sensitivity and 98.80 % specificity for detecting cervical lesions.

**Conclusions:** VIA test has high sensitivity and low specificity for picking up cervical lesions. The false positive cases can be reduced by Pap smear test or colposcopy guided biopsies. It is simple, easy to perform and gives immediate results thereby obviating the patients' second visit for report collection. VIA is a real time screening test and a suitable alternative to Pap smear testing and is especially useful in low resource setting.

**Keywords:** Cervical screening programs, Comparison of VIA and Pap smears, Pap smears, Unhealthy cervix, VIA test.

### Introduction

Cervical cancer is the most common cancer among women in developing countries.<sup>[1]</sup> In India, breast and cervical cancers are the most common of all cancers.<sup>[2]</sup> Cervical cancer accounts for 26% of all cancer deaths in women in India.<sup>[3]</sup>

Global evidence demonstrates that early detection and timely treatment of cervical precancerous lesions reduces the mortality and morbidity of cervical cancers. Voluntary testing remains the best method of preventing cervical cancer and in a study done by Muntean et al.<sup>[4]</sup> They demonstrated the prevention ratio of 80-90% by the Pap test.

Cervical cytology often referred to as Pap smear is a well-known and proven method for detection of premalignant cervical lesions. Although performing a pap test may seem relatively simple, it involves a large number of steps from specimen preparation to informing patients of the results. The entire screening program can break down if all the steps are not followed properly. Hence, there is a need for alternative simpler and low cost methods especially for low resource settings. Visual inspection with acetic acid (VIA test) is one such method.<sup>[5]</sup>

In VIA test, the cervix is washed with acetic acid and then inspected by eye for evidence of disease. This

has potential advantages over traditional screening technique "pap test" in poorly resourced locations as it does not require a second person for interpretation of results and a second visit by the patient is also not required to collect the report.

### Aims and Objectives

To compare visual acetic acid test (VIA) with Pap smear test for screening of cervical lesions in unhealthy cervixes.

### Materials and Methods

This was a prospective hospital based study carried out over a period of six months from March to August 2016 in the departments of Pathology and Obstetrics and Gynecology, Maheshwara Medical College, Hyderabad. The study group consisted of 523 women, all of them having unhealthy cervix on direct inspection. Women who were menstruating and those having visible, frank cervical growths were excluded from the present study.

Informed consent was taken from all the patients. Unaided visual inspection of the cervix was performed under good illumination and normal / abnormal features were noted. The following instruments were used: Sterile rubber gloves, sterile specula, Cusco's

Vulsellum, Ayre’s spatula, numbered glass slides, Coplin jars with fixative, 3-5% acetic acid and Papanicolaou stain.

The cervix was visualized with a speculum. Smears were taken using Ayer’s spatula for cytological examination from all 523 women. The material was immediately spread evenly onto a previously marked glass slide and immediately fixed in a Coplin jar filled with 95% isopropyl alcohol. Routine Pap staining was performed on the fixed slides and the smears were examined. Smears were reported according to the Bethesda system for cervical cytology. Smears having Low grade squamous intraepithelial lesion (LSIL) and higher lesions were considered as positive on Pap smears.

After obtaining the Pap smear the cervix was painted with 3-5% freshly prepared acetic acid solution using sterile cotton swabs. The cervix was inspected after 1 minute and the results were noted as positive when there were distinct “acetowhite” areas and as negative when no “acetowhite” areas were seen.

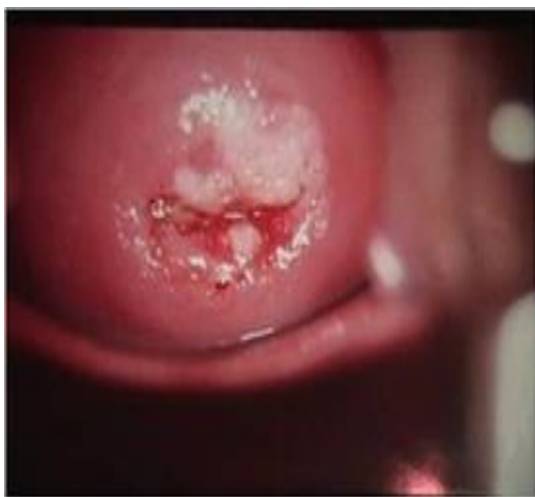

Fig. 1: Positive VIA test with Acetowhite area

**Observations and Results**

**Table 1: Age wise distribution of 523 patients.**

Age	No. of cases	Percentage
21-30	140	26.77%
31-40	190	36.33%
41-50	112	21.41%
51-60	46	8.80%
61-70	35	6.69%
<b>Total</b>	<b>523</b>	<b>100.00%</b>

The patient age ranged from 21 to 70 years. Women less than 40 years comprised 230 cases (63%).

**Table 2: Pap smear test results in VIA positive cases**

Pap smear report	No. of cases	Percentage
Normal Smears	1	3.70 %
Inflammatory Smears	2	7.41 %
ASCUS	3	11.11 %
LSIL	15	55.56 %
HSIL	4	14.81 %
Carcinoma	2	7.41 %
<b>Total</b>	<b>27</b>	<b>100 %</b>

Lesions having LSIL or higher categories were considered positive on Pap smears. Out of total 523 cases, 19 cases (3.63 %) showed the SIL (Squamous Intraepithelial Lesions) or dysplastic changes. The positive cytology was seen in 21 cases (4.01 %) including both dysplastic and malignant conditions.

**Table 3: Acetic Acid Test Results (VIA).**

VIA test	No. of cases	Percentage
Negative	496	94.84 %
Positive	27	5.16 %
<b>Total</b>	<b>523</b>	<b>100 %</b>

Out of total 523 cases, 496 cases (94.84%) were negative for VIA test and 27 cases (5.16%) were positive for VIA test.

The VIA test showed 100% sensitivity and 98.80% specificity for detecting cervical lesions when compared to Pap smears.

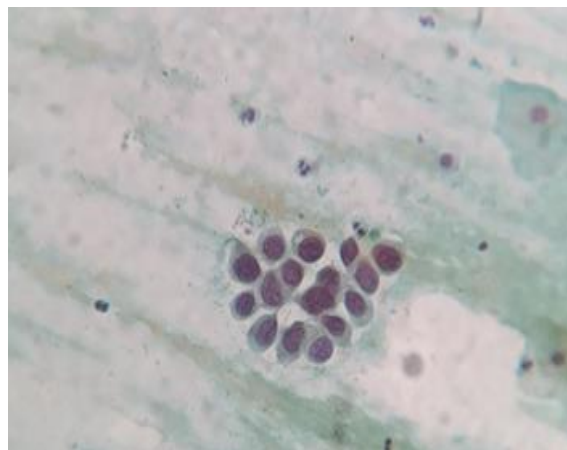


Fig. 2: LSIL on Pap smear

**Discussion**

Carcinoma cervix is the most common cancer in rural women. Early detection coupled with timely treatment reduces its mortality and morbidity. The Pap smear screening is well established in developed countries but is difficult to implement in developing countries because of its cost, lack of trained personnel and multistage nature of the procedure.<sup>[6]</sup>

These potential difficulties in cytology-based program have prompted the investigations of alternative low-cost screening technology such as visual inspection with acetic acid (VIA). The advantages of VIA are that its result is immediately available and does not depend on lab support.<sup>[6]</sup>

In the present study, women less than 40 years comprised 230 cases (63%). In a study done by Bhattacharya et al.<sup>[7]</sup> 34% women belonged to 30-39 years age and 52% belonged to women in 4th and 5th decades. In the present study, dysplastic changes were more in the third decade and this compares well with the findings of Bhattacharya et al, who observed a rate of 6.25% dysplastic changes among women in third decade.

In the present study, the cytology positive rate for dysplastic and malignant lesions was 4.01%. This compares well with the findings of Bhattacharya et al.<sup>[7]</sup> who reported a cytology positive rate of 7.3%. Our findings are in contrast with those of Hegde et al.<sup>[8]</sup> and Patil et al.<sup>[9]</sup> who reported a slightly higher rate of cytology positive cases of 11.7% and 17.5% respectively. Megevand et al.<sup>[10]</sup> observed abnormal Pap smears in 13% in their study.

The lower positive rates of cytology in our study could be due to the local practices or reluctance of symptomatic patients for hospital visits or due to unawareness of availability of cytology screening.

The VIA positive rate in the present study was 5.16%. Sankaranarayanan et al.<sup>[11]</sup> observed 9.9% positive rate for VIA in a large population based study in South India. Bhattacharya et al.<sup>[7]</sup> reported a VIA positivity of 17.3 % in their study. Ceccini et al.<sup>[11]</sup> and Malathi et al.<sup>[12]</sup> reported a VIA positivity of 25.4% and 29.16%, respectively, whereas, Hegde et al.<sup>[8]</sup> reported a low VIA positivity of 12%. Such high variation in positive VIA reporting can be due to the technique itself, including the quality and concentration of acetic acid, the timing of reading the test, light source for visualization and interpretation of doubtful or borderline aceto-white areas. Also other important contributors could be the population being studied; hospital based symptomatic population versus mass screening based non-symptomatic population.

In the present study, sensitivity of VIA test was 100% and specificity was 98.8%. Malathi et al.<sup>[12]</sup> observed 93.3% sensitivity and 80 % specificity for the VIA test. Bhattacharya et al.<sup>[7]</sup> observed sensitivity and specificity of VIA as 89 % and 87% respectively. Singh et al.<sup>[13]</sup> and Goel et al.<sup>[14]</sup> observed sensitivity and specificity of VIA to be 93.1% and 86.8%; and 96.7% and 36.4% respectively.

Hegde et al.<sup>[8]</sup> reported sensitivity and specificity of 70.8% and 95% for VIA test. Tayyeb et al.<sup>[15]</sup> in their study of 540 women, observed sensitivity of VIA as 93.9% and of Pap smear as 46.9% and the corresponding specificities as 30.4% and 69.5%. They concluded that that VIA has better sensitivity and higher accuracy as compared to Pap smear and could be

used effectively for detection of precancerous lesions of cervix.

In a study by Satyanarayana et al.<sup>[16]</sup> screen positivity rate by VIA was 9.7%. Sensitivity and specificity of detecting the cervical intraepithelial neoplasia grade III (CIN III) and above lesions was 50.0% and 96.7% for VIA test. They concluded that VIA screening is a feasible primary screening test to detect high grade CIN and can be used when the Pap test is not possible.

In a study by Mahmud et al.<sup>[6]</sup> the sensitivity of VIA test was 78.5% versus 61.1% for Pap smear and the specificity of VIA test was 99.3% versus 99.4% for cytology. Significantly higher sensitivity and specificity was found when both VIA and Pap test were done together. They recommended VIA as the primary screening tool for universal screening because of the many advantages of this test over Pap smears. They have further recommended VIA in combination with Pap test for opportunistic screening with high incidence of cervical intraepithelial neoplasias.

Authors comparing cytology with VIA have concluded that overall usefulness of VIA compares favorably with Pap test.<sup>[15]</sup>

## Conclusions

Visual inspection with acetic acid test (VIA) has high sensitivity for picking up cervical lesions. It has low specificity and picks up inflammatory lesions as well. The false positive cases can be reduced by Pap smear test or colposcopy guided biopsies. The VIA test is simple, easy to perform and gives immediate results thereby obviating the patients' second visit for report collection. VIA is a real time screening test and a suitable alternative to Pap smear testing and is especially useful in low resource setting.

## References

1. Sankaranarayanan R, Esmay PO, Rajkumar R, Muwonge R, Swaminathan R, Shanthakumari S, et al. Effect of visual screening on cervical cancer incidence and mortality in Tamil Nadu, India: a cluster randomized trial. *Lancet* 2007; 370:365-366.
2. National Centre for Disease Informatics Research, National Cancer Registry Programme, ICMR Three Year Report of Population Based Registries, 2009–2011 Bangalore, India: NCDIR-NCRP (ICMR:) 2014.
3. GLOBOCAN 2008 Cancer Fact Sheet. Lyon, France: International Agency for Research on Cancer Section of Cancer Information. <http://globocan.iarc.fr/factsheets/cancers/cervix.asp>.
4. Muntean M. Cytological Identification of the (Pre) Cancerous Cervical Lesions within a Clinically Asymptomatic Female Population, Pathology Laboratory, Slatina Emergency County Hospital, *Current Health Sciences Journal* 009; 35(3):176-179.
5. Perkins RB, Langrish SM, Stern LJ, Figueroa J, Simon CJ. Comparison of visual inspection and Papanicolaou (PAP) smears for cervical cancer screening in Honduras: should PAP smears be abandoned? *Trop Med Int Health* 2007; 12(9):1018-25.
6. Mahmud G, Tasnim N, Iqbal S. Comparison of Visual Inspection with acetic acid and Pap smear in cervical

- cancer screening at a tertiary care hospital. *JPMA* 2013; 63(8):1013-16.
7. Bhattacharya AK, Nath J, Deka H. Comparative study between Pap smear and visual inspection with acetic acid (via) in screening of CIN and early cervical cancer. *J Midlife Health* 2015; 6(2): 53-58.
  8. Hegde D, Shetty H, Shetty PK, Rai S. Diagnostic value of acetic acid comparing with conventional Pap smear in the detection of colposcopy biopsy-proved CIN. *Journal of Cancer Research and Therapeutics* 2011; 7(4):454-458.
  9. Patil K, Durdi G, Lakshmi KS, Swamy MK. Comparison of diagnostic efficacy of Visual Inspection of cervix with Acetic acid and Pap smear for Prevention of Cervical Cancer: Is VIA superseding Pap Smear? *Journal of South Asian Federation of Obstetrics and Gynaecology* 2011; 3(3); 131-134.
  10. Megevand E, Denny L, Dehaeck K, Soeters R, Bloch B. Acetic acid visualization of the cervix: An alternative to cytologic screening. *Obstet Gynecol* 1996; 88: 383-6.
  11. Ceccini S, Bonardi R, Mazzotta A, Grazzini G, Lossa A, Ciato S. Testing cervicography and VIA as screening tests for cervical cancer. *Tumori* 1993; 79:22-5.
  12. Malathi P, Vanaja E, Sirisha S. Cervical cytology in healthy and unhealthy cervices with acetic acid as agent for visual inspection. *Asian Pac. J. Health Sci.*, 2016; 3(3):325-332.
  13. Singh KN, More S. Visual inspection of cervix with acetic acid in early diagnosis of cervical intraepithelial neoplasia and early cancer cervix. *J Obstet Gynaecol India* 2010;60:55-60.
  14. Goel A, Gandhi G, Batra S. Visual inspection of the cervix with acetic acid for cervical intraepithelial lesions. *Int J Gyn and Obs* 2005; 88:25-30.
  15. Tayyeb R, Khwaja NP, Malik N. Comparison of visual inspection of cervix and Pap smear for cervical cancer screening. *J Coll Physicians Surg Pak* 2003; 13(4):201-3.
  16. Satyanarayana L, Asthana S, Bhambani S, Sodhani P, Gupta S. A comparative study of cervical cancer screening methods in a rural community setting of North India. *Indian J Cancer* 2014; 51:124-8.