

Inflammatory Myofibroblastic Tumor (IMT): Report of 8 cases at uncommon sites with literature review

Punam Prasad Bhadani^{1,*}, Iffat Jamal², Umesh Kumar Bhadani³, Shuchismita⁴

¹Additional Professor & HOD, ²Senior Resident, ³Professor & HOD, ⁴Assistant Professor, ^{1,2}Dept. of Pathology, AIIMS-Patna, ³Dept. of Anaesthesiology, AIIMS- Patna, Bihar, ⁴Dept. of Pathology, IGIMS, Patna, Bihar, India

*Corresponding Author:

Email: bhadanipunam@gmail.com

Abstract

Inflammatory myofibroblastic tumor (IMT) is a lesion of unknown etiology, originally described in lung but can be found at other sites also. Their presence in gall bladder, soft tissue and mesentery is rare. Eight cases of IMT is reported at abnormal sites of mesentery, gall bladder, soft tissue in thigh, disseminated form of IMT involving gall bladder adhered with liver, pylorus and 1st part of duodenum. The characteristic histopathology and immunohistochemistry confirmed the diagnosis of IMT in these cases. Diagnosis of IMT can be challenging and need a multi-disciplinary approach for the correct diagnosis and treatment.

Keywords: Inflammatory, Myofibroblastic, Tumor, Gall bladder, Pylorus, Immunohistochemistry.

Introduction

Inflammatory myofibroblastic tumor (IMT) is a rare benign solid tumor that most often affects various age groups ranging from 1 to 77 years with a peak at adulthood. Different terms have been applied to the lesion, namely, inflammatory pseudotumor, fibrous xanthoma, plasma cell granuloma, pseudosarcoma, lymphoid hamartoma, myxoid hamartoma, inflammatory myofibrohistiocytic proliferation, benign myofibroblastoma, and most recently, inflammatory myofibroblastic tumor.⁽¹⁾ Primary inflammatory myofibroblastic tumors of the gallbladder are rather infrequent. There is a slight female preponderance.^(1,2) They are characterized as solitary, well demarcated, fibrous tumor with numerous inflammatory cells,

mainly lymphoid or plasma cells along with proliferating blood vessels. Although the lung is the best known and most common site, subsequently, it was recognized that analogous tumors can occur in various sites other than the lung, including the breast, central nervous system, gastrointestinal tract, heart, kidney, submandibular gland, skin, spleen, lymph node, urinary bladder, uterus, mesentery, omentum, retroperitoneum, liver, upper respiratory tract and paranasal sinuses.⁽³⁻⁵⁾ We present here 8 cases of IMT, which posed diagnostic difficulties due to uncommon site of origin.

Case Reports

Clinical details of all IMT cases at unusual sites are summarized in Table I.

Table 1: Findings of Inflammatory myofibroblastic tumor at various unusual sites: Clinical, Radiological, Gross and Microscopic findings.

Case No.	Age/ Sex	Symptoms	Radiological findings	Clinical Diagnosis	Gross findings	Microscopic findings
1	6 years male	Upper abdominal pain, low grade fever	USG findings-7.5x7.2 cm, well defined hypochoic mass with homogenous internal echoes situated anterior to the right kidney	Mesenteric lymphadenopathy	Boselated, firm, well circumscribed mass measuring 9x8x7 cm. Cut surface was tan, homogenous	Interlacing fascicles of elongated spindle cells to loosely and haphazardly arrange plump, fusiform or stellate cells admixed with plasma cells, histiocytes and lymphocytes. The nuclei of spindle cells were oval and vesicular and open chromatin pattern and occasionally prominent nucleoli. Fair number of giant cells are also seen.
2.	32 years male	A nodular swelling over the lateral aspect of right thigh	A heterogeneously enhancing lesion of soft tissue on right thigh (lateral aspect) of size 7x6 cm	Soft tissue tumor	An ill circumscribed firm mass measuring 7x6x4 cm. Cut section- solid, homogenous	Interlacing bundles of bland looking spindle cells with extensive collagen deposition and infiltration of dense lymphocytes, plasma cells, few eosinophils, histiocytes and giant cells.
3.	40 years male	A nodular swelling over the lateral aspect of right thigh	A heterogeneously enhancing lesion of soft tissue on right thigh (lateral aspect) of size 5x3 cm	Soft tissue tumor	An ill circumscribed mass of size 5x3x3 cm, grayish white. Cut section- solid, homogenous	Fascicles of spindle cells seen with extensive collagen deposition in between along with infiltration of dense lymphocytes and plasma cells. Fair number of giant

						cells are also seen.
4.	28 years female	Pain abdomen, vomiting, indigestion, icterus	USG- distended Gall bladder measuring 9x5 cm with multiple gall stones.	Chronic cholecystitis	Distended Gall bladder specimen measuring 9x5 cm, containing multiple stones. A polypoidal, pedunculated, growth measuring 2x2 cms covered with partly ulcerated mucosa was seen projecting from the fundus .Cut section- homogenous gray white.	A polymorphic tumour cell population and a variable inflammatory infiltrate against vascularized collagenous stroma. The tumour cells varied from spindle fibroblastic like cells to large polygonal cells showing anisonucleosis, vesicular nuclei and prominent nucleoli. The cytoplasm was abundant and eosinophilic. Mono and multinucleated tumor giant cells were focally prominent. Inflammatory cells predominantly comprised of plasma cells including binucleate forms, with sprinkling of lymphocytes, histiocytes and a few neutrophils
5.	36 years female	Bloating of abdomen with dyspepsia	Abdominal USG-revealed contracted gall bladder with a multiple calculi, largest measuring 25.3 mm. Gall bladder wall showed asymmetric wall thickening in fundal region and maximum wall thickness was about 9.0 mm as well as loss of fat plane with adjacent duodenum and liver. Contrast enhanced computed tomography of abdomen and pelvis showed mild diffuse wall thickening along with significant asymmetrical wall thickening in body region extending along the adjacent duodenum with circumferential thickening of the duodenal wall.	Adenocarcinoma, gall bladder with metastatic dissemination	On gross examination gall bladder appeared dilated with thickened wall and presence of single oval stone. Liver bed, pyloric part of stomach and 1 st part of duodenum was also attached. Cut surface of gall bladder showed ulcerated and velvety mucosa with thickening of gall bladder ranging from 0.4 cm in body to 2 cm in fundal area. There was a solid nodular area in the serosal aspect extending upto the pyloric end of stomach and attached liver bed.	Sections showed ulcerated gall bladder mucosa with thickened wall infiltrated by mixed inflammatory infiltrate mainly lymphocytes, plasma cells along with proliferated spindle shaped myofibroblasts and giant cells. Hypertrophied muscle bundles are seen throughout the section with scattered eosinophils. Similar microscopic features are seen in the section taken from pyloric end of attached stomach, 1 st part of duodenum and attached liver bed.
6.	44 years male	Pain abdomen, nausea , loss of appetite	USG showed thickened Gall bladder wall with multiple stones	Chronic cholecystitis	Gall bladder specimen of size 7x5 cm, serosa unremarkable. Cut section filled with multiple gall stones, loss of mucosal rugosities. Wall thickness varied from -0.3 cm -0.8 cm.	Section show predominantly interlacing fascicles of elongated spindle cells which is loosely and haphazardly arranged with admixed fair number of plasma cells, histiocytes and lymphocytes.
7.	38 years, female	Pain abdomen, nausea , loss of appetite	USG showed thickened Gall bladder wall with multiple stones.	Chronic cholecystitis	Gall bladder specimen of size 6.3x5 cm, serosa unremarkable. Cut section filled with multiple gall stones. Wall thickness varied from 0.4cm -0.9 cm.	Elongated spindle cells are seen arranged in interlacing fascicles with admixed plasma cells, histiocytes, lymphocytes and giant cells.
8.	35 years, male	Right upper abdomen pain, bloating, vomiting, and icterus.	USG showed thickened gall bladder wall, filled with multiple gallstones.	Chronic cholecystitis	Contracted Gall bladder specimen of size 4.5 x 3 cm, serosa unremarkable, Cut section filled with multiple gall stones. Wall thickness varied from 0.4cm -0.9 cm.	Interlacing fascicles of elongated spindle cells to loosely and haphazardly arrange plump, fusiform or stellate cells admixed with plasma cells, histiocytes and lymphocytes. Few multinucleate giant cells also seen.

Case 1

6 year old male child presented with on and off upper abdominal pain, low grade fever for 3 months and generalized weakness for one month. His appetite

and bowel habits were normal. Physical examination revealed a firm, irregular, mobile, non-tender mass in the right lumbar region of about 12x10 cm. abdominal ultrasonography showed 7.5x 7.2 cm, well defined

hypoechoic mass with homogenous internal echoes situated anterior to the right kidney. A possibility of mesenteric lymph nodal mass was considered. Laboratory investigations revealed 7.9 gm/dl hemoglobin, total leukocyte count was 17100/mm³ with mild neutrophilia, platelet count was 5, 42,000/cmm, erythrocyte sedimentation rate (ESR) 61mm/hr, Montoux test was negative. At laparotomy a large, firm, lobulated, well circumscribed, mobile, 9x8 cm mass was seen in the mesentery of the caecum and could easily be enucleated. After one and half month follow up his CBC and ESR were normal.

Pathologic findings:

The gross specimen was well- circumscribed, firm mass measuring 9x8x7 cm. Cut surface was solid, tan and homogenous.

Microscopy revealed organized, interlacing fascicles of elongated spindle cells to loosely and haphazardly arranged plump, fusiform or stellate cells admixed with plasma cells, histiocytes and lymphocytes. The nuclei of spindle cells were oval and vesicular and open chromatin pattern and occasionally prominent nucleoli. Mitotic figures were rare. The case was diagnosed as IMT in combination with the result of IHC.

Case 2 & 3

A 32 and 40 year old male presented with gradually increasing nodular swelling over the lateral aspect of right thigh, with fair general condition. Local examination revealed 7cm and 5cm subcutaneous nodule respectively with limited mobility and mild tenderness. Hematological parameters and other investigations were within normal limit. A provisional clinical diagnosis of soft tissue tumor was made in both the cases. The mass was removed and sent for histopathological examination.

Pathological findings:

The gross specimen was firm, ill circumscribed in both the cases, measuring 7x6x4 cm, and 5x3x3 cm respectively. Cut surface was solid and homogenous. Microscopically features of IMT was present in both the cases, which was confirmed on IHC result.

Case 4

A 28 year old female presented with abdominal pain and fever for 7 days. Physical examination revealed mild jaundice without history of weight loss. Abdominal ultrasonography suggested distension of gall bladder with presence of multiple stones. Liver function test was within normal limit. Cholecystectomy was performed with the clinical diagnosis of cholecystitis with cholelithiasis.

Pathological findings:

Grossly, gall bladder was distended with presence of multiple stones. A polypoidal, pedunculated, partly infarcted 2x2 cm mass was seen projecting from the fundus of the gall bladder. Cut surface was solid, homogenous gray white.

The histopathology of polypoidal growth revealed a polymorphic cell population with a variable inflammatory infiltrate against a vascularized collagenous stroma. The tumour cells varied from spindle fibroblastic like cells to large polygonal cells showing anisonucleosis, vesicular nuclei and prominent nucleoli. The cytoplasm was abundant and eosinophilic. Mono and multinucleated tumor giant cells were focally prominent. Inflammatory cells predominantly comprised of plasma cells including binucleate forms, with sprinkling of lymphocytes, histiocytes and a few neutrophils. Background was well vascularized.

The lesion was diagnosed as IMT with the confirmation with IHC result. The tumour was not extending through the serosa. The patient has been in the follow up for the last one year and no abnormality has been picked up on T-USG.

Case 5

A 36 year old female, came to surgery OPD with complaints of bloated abdomen with dyspepsia for 5 months. Clinical examination was unremarkable. Laboratory investigation reveals neutrophilic leukocytosis with increased ESR. Other investigations were within normal limits except AST-45U/L and A: G ratio 0:0.84. Abdominal ultrasonography revealed contracted asymmetrically thickened gall bladder with presence of multiple calculi. Contrast enhanced computed tomography of abdomen and pelvis showed significant asymmetrical thickening of the gall bladder wall extending along the adjacent duodenum with circumferential thickening of the duodenal wall. Fat plane between GB and the lesion was poorly visualized with mild hepatic attenuation. Intraoperative finding revealed adhesion of the gall bladder with liver, pylorus and 1st part of duodenum. An extended cholecystectomy with Bilroth gastrectomy was performed and sent for histopathological examination. Gross examination of gall bladder appeared dilated and thickened with presence of single oval stone. Liver bed, pyloric part of stomach and 1st part of duodenum was also attached. Cut surface of gall bladder showed ulcerated and velvety mucosa with thickening of gall bladder wall ranging from 0.4 cm in body to 2 cm in fundal area. There was a solid nodular area in the serosal aspect extending upto the pyloric end of stomach and attached liver bed. (Figure 1) Microscopically the section showed ulcerated gall bladder mucosa with thickened fibrotic wall. Wall of gall bladder showed presence of dense lymphoplasmacytic inflammatory infiltrate, proliferated spindle shaped myofibroblasts and giant cells along with hypertrophied muscle bundles and scattered eosinophils. (Figure 2 & 3) Similar microscopic features seen in section from attached liver bed, pylorus and 1st part of duodenum too. No atypical mitosis and area of necrosis seen in any of the section. In view of all these finding diagnosis was given as disseminated

inflammatory myofibroblastic tumour involving gall bladder, liver, pylorus and 1st part of duodenum.

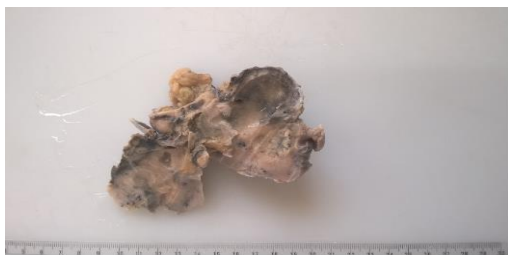

Fig. 1: Gross photograph of excised gall bladder specimen showing distorted gall bladder with grayish white solid areas with complete loss of mucosal rugosities. Wall thickness varied from 0.4-2 cm

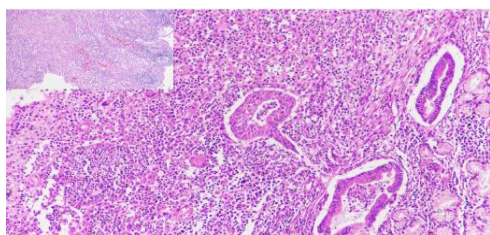


Fig. 2: Microphotograph showing dense interlacing bundles of spindle cells, few destructive mucosal glands with mixed inflammatory infiltrate composed of lymphocytes, plasma cells, macrophages and eosinophils (H & E; 400X), Inset shows microphotograph of same at lower magnification. (H & E; 100X)

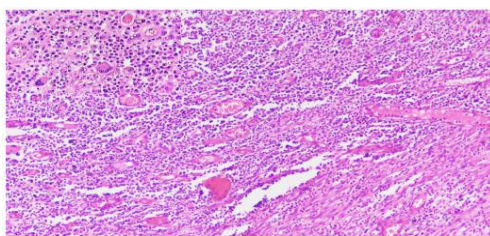


Fig. 3: Microphotograph showing proliferation of myofibroblasts, fibroblasts, capillaries long with mixed inflammatory cell infiltrate. (H & E; 100X). Inset: Microphotograph showing multinucleate giant cells, lymphocytes, plasma cells, eosinophils, few neutrophils and macrophages. (H & E; 400X)

Case 6, 7 and 8

Presented to surgical OPD with the complaint of abdominal pain, clinically diagnosed as chronic cholecystitis. Cholecystectomy turned out as thickened gall bladder, which on microscopy diagnosed as inflammatory myofibroblastic tumor of gall bladder. Immunohistochemistry (IHC) done in all the 8 cases revealed cytoplasmic positivity for ALK and SMA confirming the diagnosis of IMT. (Figure 4 & 5)

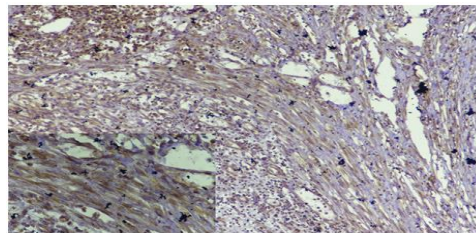


Fig. 4: Immunostaining with ALK showing cytoplasmic positivity in smooth muscles. (DAB; 100X). Inset shows same in higher magnification (DAB; 400X)

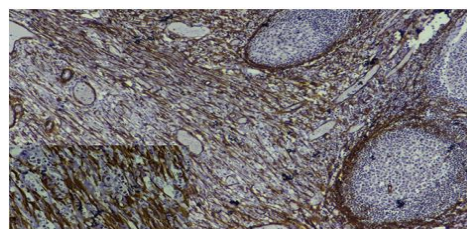


Fig. 5: Immunostaining for SMA showing cytoplasmic positivity (DAB; 100X). Inset shows same in higher magnification. (DAB; 400X)

Discussion

Inflammatory myofibroblastic tumour is a benign, non-metastasizing proliferation of myofibroblasts with potential for recurrence and persistent local growth, similar in some respect to the fibromatoses.^(2,3) IMT was first described in 1939 and because of it simulates malignancy, it was named as “Inflammatory pseudotumor” in 1954. IMT was considered as non-neoplastic, but is currently considered as a tumor with low-grade malignant potential because of local recurrence, infiltrative growth pattern, vascular invasion and malignant transformation.^(3,4)

Although IMTs can involve any organ or system in the body, lungs being the most common site of involvement. The other common sites are abdominal cavity, and urinary bladder, whereas location in peripheral soft tissues is rare. The most frequently involved organ in the abdomen is the liver, while primary gallbladder involvement is quite rare.⁽⁴⁾

Two theories have been emphasized to explain the etiopathogenesis: the first is an abnormal host response to tissue damage, while the second is disorders in immunological responses.^{5,6} IMTs are known to be benign tumors with no capacity to metastasis. However, these tumors are known to infiltrate surrounding tissues due to their severe proliferative capacity and they are thus known to recur frequently, even after resection. The Epstein-Barr virus, the human herpes virus HHV8, bacteria such as *Campylobacter equi*, *Campylobacter jejuni*, *Escherichia coli*, trauma, radio- and steroid therapy were considered to be causative factors.^(7,8) Hepatitis C, HIV and TB infections prior to the development of pseudotumor also been documented.⁽⁹⁾

Clinical features varies according to site of involvement. Abdominal IMTs occur mainly in children and young adults. They can cause intestinal obstruction and are often multiple and commonly large, >10 cm. They can involve omental and peritoneal soft tissues and less commonly any part of the gastrointestinal tract proper and such tumors can clinically simulate a gastrointestinal stromal tumor (GIST). A minority of patients (15%–30%) experiences constitutional symptoms that disappear after tumor removal but can reappear with tumor recurrence. These symptoms include fever, malaise, and weight loss, and children also can experience growth retardation.¹⁰ Gallbladder involvement, on the other hand, may result in acute cholecystitis, biliary colic, obstructive jaundice and cholangitis may be seen in cases with extension to the common bile duct.⁽¹¹⁾ So far very few number of cases of primary of the gallbladder reported in the literature.⁽¹²⁻¹⁶⁾

Peripheral soft tissue IMTs are rare. In a recent series that included atypical and aggressive examples, 8% of IMTs occurred in the head and neck, 5% in the extremities, and none in the trunk wall.⁽¹⁷⁾ No patient developed metastases. In one series predating ALK studies, such tumors occurred in adults of 28 to 83 years (median age, 54 years), and no recurrences or metastases were reported, although mortality was reported, related to co-morbidities.⁽¹⁸⁾ In one case, IMT of the forearm converted into a full-blown sarcoma after multiple recurrences; no ALK studies were available on this case. The above mentioned case showed microscopic features of IMT which was confirmed on immunohistochemistry.⁽¹⁹⁾

Four basic histologic patterns are commonly seen as follows: a) Dominant lymphoplasmacytic infiltrate; b) Dominant lymphohistiocytic infiltrate; c) Young and active myofibroblastic process and d) Predominantly collagenized process with lymphocytic infiltrate.

Laboratory abnormalities are not of much help in making the diagnosis of inflammatory pseudo-tumor. Anemia, thrombocytosis, elevated erythrocyte sedimentation rate may be seen in some patients.⁽⁷⁾ Laboratory values of this case are in accordance with other cases reported in the literature. To diagnose IMT based on ancillary diagnostic methods, such as imaging studies, is considerably difficult. IMTs mimic malignant tumors in imaging studies. Myofibroblastic proliferation is responsible for the confusion of IMTs with malignant tumors. The denser the proliferation is, the greater the difficulty of reaching a differential diagnosis with malignancy.⁽¹⁹⁾

Myofibroblastic tumors fall into four main groups: the family of reactive fasciitis like lesions, a group of benign lesions (e.g. Mammary myofibroblastoma, intranodal myofibroblastoma, angiomyofibroblastoma and dermatomyofibroma), the locally aggressive fibromatoses (either superficial or deep) which share features of fibroblasts and myofibroblasts in varying

degree and finally sarcomas showing myofibroblastic differentiation (low grade lesions – infantile myofibroblastic sarcoma, inflammatory myofibroblastic tumour, low grade myofibroblastic sarcoma, inflammatory fibrosarcoma and high grade lesions – malignant fibrous histiocytoma).^(2,18)

Grossly, the abdominal and pelvic lesions range widely in size, from 1 cm to 20 cm (median size is close to 10 cm). The tumor tissue is gray-white or tan-pink. The cut surface is usually rubbery but can be myxoid in some areas.

Microscopically, IMT is composed of myofibroblasts and inflammatory cells. The spindle myofibroblasts and inflammatory cells of IMT are arranged in three basic histological patterns.^(5,12) In first pattern, myofibroblasts are loosely arranged in an edematous myxoid background with abundance of blood vessels and chronic inflammatory infiltrate comprising of plasma cells, lymphocytes and eosinophils. This pattern mimics granulation tissue, nodular fasciitis, or other reactive processes. A second pattern is characterized by fascicular and storiform arrangement of myofibroblasts with variable myxoid and collagenized areas and mature lymphoid and plasma cell infiltrate with germinal centers. Ganglion like myofibroblasts are often seen in these two patterns. This pattern resembles fibromatosis, fibrous histiocytoma, or smooth muscle neoplasm. The third pattern is paucicellular with sparse inflammatory infiltrate and dense collagenisation. It resembles a scar or desmoids-type fibromatosis. Highly atypical polygonal cells with vesicular nuclei, prominent nucleoli and variable mitoses are seen in rare IMTs which undergo malignant transformation.^(19,20)

Immunohistochemical evaluation of ALK expression is useful in the differential diagnosis, because other inflammatory pseudotumor are usually ALK negative, although positivity has been reported in rhabdomyosarcoma and leiomyosarcoma, indicating that an immunohistochemical panel addressing these different diagnostic possibilities is necessary.^(21,22) IMTs are also positive for vimentin, and variably for muscle actin (HHF-35), α -smooth muscle actin and occasionally focally for desmin, although cases with primitive nonmyoid phenotypes have also been reported.⁽²³⁾ Keratin positivity for AE1/AE3 cocktail and CAM5.2 antibodies is common, especially in the abdominal and urinary bladder tumors but seems to be less common in pulmonary lesions.⁽²⁴⁾ The tumor cells are negative for myoglobin, MyoD1/myogenin, S100 protein, and KIT (CD117).⁽¹⁹⁾ All the 8 cases discussed here showed positivity with ALK and SMA.

The ALK gene is located on the 2p23 chromosome; it encodes the ALK protein, the tyrosine kinase receptor. This method is a very sensitive tool used to differentiate an IMT from other spindle-cell tumors.^(25,26) Malignant transformations and recurrences of IMT have been reported to occur between four to seven years after surgery. Lifelong follow up is

necessary even in patients with radical surgery, as the exact biological behavior of IMT is unknown.⁽²⁸⁾

In general, the prognosis of IMT is good, but well documented examples that metastasized and caused patient death have occurred. Because of the paucity of malignant examples, no clear cut criteria can be developed to separate tumors with benign and malignant behavior. Surgery is the main treatment modality⁽¹⁰⁾ however, an article published revealing promising results with anti-inflammatory agents and anti-tumour necrosis factor- α binding antibodies.^(27,28)

To conclude, that inflammatory myofibroblastic tumour (IMT) is a rare tumour with a wide spectrum of clinical and radiologic findings because of the variability of location. These lesions can be challenging to diagnose to clinicians, radiologists or even pathologists, requiring a multi-disciplinary approach to better evaluate each case individually.

References

1. Sinha L, Hasan A, Sinha AK, Bhadani PP, Jha AN, Singh PK, Kumar M. Inflammatory myofibroblastic tumor involving liver, gall bladder, pylorus & duodenum: A rare case presentation. *Int J Surg Case Report*.2017; 31:27-29.
2. Narla LD, Newman B, Spottswood SS, Narla S, Kolli R. Inflammatory pseudotumor. *Radio Graphics*. 2003; 3:719–29.
3. Palaskar S, Koshti S, Maralingannawar M, Bartake A. Inflammatory myofibroblastic tumor. *Contemp Clin Dent*. 2011;2(4):274-77.
4. Germanidis G, Xanthakis I, Tsitouridis I, et al. Regression of inflammatory myofibroblastic tumor of the gastrointestinal tract under infliximab treatment. *Dig Dis Sci*. 2005;50:262-5.
5. Sukov WR, Chevillie JC, Carlson AW, Shearer BM, Piatigorsky EJ, Grogg KL, Sebo TJ, Sinnwell JP, Ketterling RP. Utility of ALK-1 protein expression and ALK rearrangements in distinguishing inflammatory myofibroblastic tumor from malignant spindle cell lesions of the urinary bladder. *Mod Pathol*. 2007;20:592–603.
6. Coffin CM, Hornick JL, Fletcher CDM. Inflammatory myofibroblastic tumor: Comparison of clinicopathologic, histologic, and immunohistochemical features including ALK-expression in atypical and aggressive cases. *Am J Surg Pathol*. 2007;31:509-520.
7. Solomon GJ, Kinkhabwala MM, Akhtar M: Inflammatory myofibroblastic tumor of the liver. *Arch Pathol Lab Med*. 2006;130:1548–1551.
8. Kasim AB, Peter S, Andrew W, et al. Inflammatory myofibroblastic tumour of the gallbladder. *World J Surg Oncol*. 2005;3:24- 29.
9. Fletcher CD. Myofibroblastic tumours: an update. *Verh Dtsch Ges Pathol*.1998;82:75-82.
10. Coffin CM, Humphrey PA, Dehner LP: Extrapulmonary inflammatory myofibroblastic tumor: a clinical and pathological survey. *Semin Diagn Pathol*.1998;15:85–101.
11. Coffin CM, Watterson J, Priest JR, Dehner L: Extrapulmonary inflammatory myofibroblastic tumor (inflammatory pseudotumor): a clinicopathologic and immunohistochemical study of 84 cases. *Am J SurgPathol*. 1995;9:859-872.
12. Karnak I, Senocak M, Cifci A, Caglar M, Bingol-Kologlu M, Tanyel F. Buyukpamukcu. Inflammatory myofibroblastic tumors in children: diagnosis and treatment. *J Pediatric Surg*. 2001, 36: 908–912.
13. Muduly D, Deo SVS, Shukla NK, et al. Inflammatory myofibroblastic tumor of gall bladder. *Trop Gastroenterol*.2012;33:297-9.
14. Ismail Ö, Mustafa Ö, Erkan Ş, et al. Inflammatory myofibroblastic tumor of the gallbladder. *Balkan Med J*. 2013;30:323-6.
15. Badea R, Veres AA, Andreica V, et al. Inflammatory myofibroblastic tumor of the gallbladder: imaging aspects. *J Med Ultrasonics*. 2015;42:89-95.
16. Muduly D, Deo SVS, Shukla NK, Manjuath NMC, Durgapal P, Kallianpur A. Inflammatory myofibroblastic tumor of gall bladder. *Trop Gastroenterol*. 2012;33:297-9.
17. Corsi A, Bosman C. Chronic cholecystitis with features of diffuse inflammatory pseudotumour: a clinicopathological case study and review of the literature. *Ital J Gastroenterol*. 1995;27:252–5.
18. Ikeda H, Oka T, Imafuku I, Yamada S, Yamada H, Fujiwara K et al. A case of inflammatory pseudotumor of the gall bladder and bile duct. *Am J Gastroenterol*. 1990;85:203-205.
19. Olgan S, Saatli B et al. Hysteroscopic excision of inflammatory myofibroblastic tumor of the uterus: as case report and brief review. *Eur. J. Obstet. Gynecol Reprod Biol*.2011;157:234–240.
20. Coffin CM, Dehner LP, Meis-Kindblom JM. Inflammatory myofibroblastic tumour, inflammatory fibrosarcoma and related lesions: an historical review with differential diagnostic considerations. *Semin Diagn Pathol*.1998;15:102–10.
21. Meis JM, Enzinger FM. Inflammatory fibrosarcoma of the mesentery and retroperitoneum: A tumor closely simulating inflammatory pseudotumor. *Am J Surg Pathol*1991;15:1146- 1156.
22. Chan JKC, Cheuk W, Shimizu M. Anaplastic lymphoma kinase expression in inflammatory pseudotumors. *Am J Surg Pathol* 2001; 25: 761- 768.
23. Cook JR, Dehner LP, Collins MH, Ma Z, Morris SW, Coffin CM, et al. Anaplastic lymphoma kinase (ALK) expression in the inflammatory myofibroblastic tumor: A comparative immunohistochemical study. *Am J Surg Pathol*. 2001;25:1364–1371.
24. Hisaoka M, Hussong JW, Brown M, Perkins SL, Dehner LP, Coffin CM. Comparison of DNA ploidy, histologic and immunohistochemical findings with clinical outcome in inflammatory myofibroblastic tumors. *Mod Pathol*. 1999;12:279–286.
25. Montgomery EA, Shuster DD, Burkart AL, Esteban JM, Sgrignoli A, Elwood L, et al. Inflammatory myofibroblastic tumors of the urinary tract: a clinicopathologic study of 46 cases, including a malignant example inflammatory fibrosarcoma and a subset associated with high-grade urothelial carcinoma. *Am J Surg Pathol*. 2006; 30:1502–1512.
26. Solomon GJ, Kinkhabwala MM, Akhtar M: Inflammatory myofibroblastic tumor of the liver. *Arch Pathol Lab Med* 2006,130:1548–1551.
27. Cessna MH, Zhou H, Sanger WG, Perkins SL, Tripp S, Pickering D, Daines C, Coffin CM. Expression of ALK1 and p80 in Inflammatory Myofibroblastic Tumor and Its Mesenchymal Mimics: A Study of 135 cases. *Mod Pathol*.2002;15:931–938.
28. Bharatnur S, Ramkumar V, K Natrajan. Inflammatory Pseudo-Tumor of Ovary - A Case Report. *The Internet Journal of Gynecology and Obstetrics*.2012;16:1-4.