

Enterobius vermicularis infestation in appendectomies: A retrospective analytical study

Riti TK Sinha¹, Arohi Parekh^{2,*}, Mansi Patel³, Dhruvi P. Shah⁴, Nidhi N. Shah⁵

¹Associate Professor, ^{2,3,4,5}3rd Year Resident, ¹⁻⁵Dept. of Pathology, Gujarat Adani Institute of Medical Sciences, Bhuj, Kutch, Gujarat, India

***Corresponding Author:**
Email: arohi9825@gmail.com

Abstract

Introduction: Gastrointestinal infection due to enterobius vermicularis is undoubtedly one of the most common human helminthic infections worldwide. It often causes acute appendicitis pain and is diagnosed only after histopathological examination of the resected appendix. Adult worms and their eggs are often found in resected appendices. Worldwide, the reported incidence of enterobius infestation in patients with symptoms of appendicitis ranges from 0.2–41.8%.

Materials and Methods: This was a retrospective study conducted for a period of one year in the department of Pathology in a tertiary care hospital, GAIMS, G.K. General Hospital, Bhuj, Kutch in India. All the 151 surgically resected appendices submitted were included in the study. Out of these 151 appendectomies, H&E stained sections of 15 cases were re evaluated due to the presence of parasite, enterobius vermicularis. Calculation of the modified Alvarado score was done and interpretation of the results was done according to published protocols.

Results: 15 /151 cases (9.93%) were found to have the presence of enterobius vermicularis in the lumen of the appendix on histopathology. 6/15 (40%) cases that had the presence of acute inflammatory cells had a higher modified Alvarado score due to the presence of leucocytosis. 9/15 (60%) cases had the presence of abundant eosinophils in the wall of the appendix along with the presence of enterobius vermicularis. 6/15 (40%) cases that did not have the presence of acute inflammatory cells had a threshold or low score due to the absence of leucocytosis.

Conclusion: Our study highlights the importance of histopathological examination of every resected specimen of appendix along with calculation of the modified Alvarado score in all cases of acute appendicitis, especially those having suspicious clinical findings suggestive of parasite infestation. Thus management of patients with parasites is different warranting antihelminthic medication.

Keywords: Enterobius vermicularis, Histopathological examination, Modified alvarado score.

Introduction

Acute appendicitis is the most frequent cause for emergency operations worldwide. The lifetime risk of acute appendicitis for men and women is 8.6% and 6.7%, respectively. However, the lifetime risk of having an appendectomy is 12% for men and 25% for women.¹

A history of migratory pain along with the constellation of the physical findings and raised leukocytosis is considered to be an accurate diagnosis of acute appendicitis for both adults and children, leading to surgical removal of appendices. However, studies have reported 250,000 appendectomies annually, with approximately 15% resulting in removal of histologically normal appendices (incidental appendectomies).² It has also been found that parasitic infestations with enterobius vermicularis (EV) of the appendix may not always associated with acute inflammation of the appendix. Adult worms and their eggs are often found in inflamed as well as non inflamed appendices.³

Important incidental findings such as worms in lumen, tuberculosis and presence of tumor can only be diagnosed by histopathological examination of resected specimens of the appendix aiding in the appropriate and timely treatment of the disease condition. This fact highlights the importance of histopathological analysis of each and every single resected appendix.

Obstruction of the appendix lumen by the parasite has been postulated as the cause of the abdominal colic. Along with parasites, fecolith, lymphoid hyperplasia, or fibrosis are the other etiologies that can lead to luminal obstruction.⁴

Gastrointestinal infection due to EV is undoubtedly one of the most common human helminthic infection worldwide.¹ The reported incidence worldwide, of enterobius infestation in patients with symptoms of appendicitis ranges from 0.2 – 41.8%.⁵

The presence of EV in the appendix usually produces symptoms resembling acute appendicitis. These signs and symptoms of acute appendicitis are due to obstruction of lumen rather than mucosal invasion. Also interestingly the appendiceal colic caused in these cases occurs without eliciting acute inflammation in many cases.⁶

EV is cosmopolitan in distribution with the adult worm lying in the caecum and vermiform appendix of man. It is the most common parasitic helminth of temperate and developed countries. It infects around 1000 million cases worldwide particularly in the temperate and cool climates.⁷

Aims and Objectives

1. To study the incidence of enterobius vermicularis in histopathological examination of the resected appendectomy specimens
2. To identify the other associated histopathological features along with the presence of EV
3. To compare the histopathological features in enterobius vermicularis along with the modified Alvarado score and the pre clinical diagnosis

Materials and Methods

This was a retrospective study conducted for a period of one year, in the department of Pathology in a tertiary care hospital; G.K. General Hospital, Bhuj, Kutch, India. All the 151 surgically resected appendices submitted were included in the study. Relevant gross findings and all the histopathological diagnoses were recorded. Out of these 151 appendectomies, haematoxylin and eosin (H&E) stained sections of 15 cases were re evaluated due to the presence of parasite EV. These reports were further analysed for incidences of age, gender and other co incidental findings. Calculation of the modified Alvarado score was done and interpretation of the results was done according to published protocols. A score of seven or more was strongly predictive of acute appendicitis.⁸ The presence of EV was also correlated with the pre clinical diagnoses.

Inclusion Criteria: All age groups of both genders were included in this study. Only the H&E stained sections that on reevaluation showed the presence of EV were included.

Exclusion Criteria: Appendectomies done as incidental procedure during some other operation were excluded from this study.

Results

1. Out of the 151 appendectomies performed with the pre-operative diagnosis of acute appendicitis, 15 cases (9.93%) were found to have the presence of parasite EV in the lumen of the appendix on histopathology examination.
2. The distribution of males and females with age distribution is given in (Table 1). The age range was from seven to 30 years.

3. The modified Alvarado score is shown in (Table 2).
4. In all the 15 cases the parasite was identified as enterobius vermicularis. The other associated histological features that were present along with the modified Alvarado score are summarized in (Table 3). A score of seven or more is strongly predictive of a preoperative diagnosis of acute appendicitis.⁸
5. It was observed that 6/15 (40%) cases that did not have the presence of acute inflammatory cells had a threshold or low score due to the absence of leucocytosis (Table 3).
6. It was also seen that 6/15 (40%) cases that had the presence of acute inflammatory cells had a higher score due to the presence of leucocytosis (Table 3).
7. Furthermore, 9/15 (60%) cases had the presence of eosinophils in the wall of the appendix along with the presence of EV.

Table 1: Age and gender distribution of patients with enterobius vermicularis (EV) in the appendectomy specimens

Age (years)	Male	Female	Total
1 – 10	01		01
11-20	05	03	08
21-30	03	03	06
Total	09	06	15

Table 2: Modified Alvarado score

Clinical / laboratory features	Score
Migratory pain right iliac fossa	1
Anorexia	1
Nausea / vomiting	1
Sensitivity in the lower right quadrant	2
Rebound tenderness	1
Elevated temperature (> 37.3 degree Celcius)	1
Leucocytosis (> 10 ⁹ /l)	2
Total	09

Table 3: Distribution of associated histopathological findings along with Modified Alvarado score in the appendectomy specimens with enterobius vermicularis (EV)

Associated histopathological findings along with EV	Number of cases	Percentage	Modified Alvarado score	Pre operative clinical diagnosis
Eosinophils and neutrophils	06	40	08	Acute appendicitis
Eosinophils	03	20	07	Acute appendicitis
Absence of Eosinophils and neutrophils	06	40	06	Recurrent appendicitis

Irrespective of the associated histopathological features, gross examination of the appendix revealed the wall of the appendix to be thickened and oedematous (Fig. 1). The lumen was reduced size and

contained semisolid fecal material. There was no luminal obstruction due to vegetable seed, stone, tumour. No grossly visible worms and appendicular septa were seen (Fig. 2).

Microscopic examination of the resected appendices revealed the presence of the lining epithelium of the appendix with inflammation in 6/16 cases (Table 3). Lamina propria showed the presence abundant inflammatory cells comprising mainly of neutrophils. Eosinophils were also present. The serosa and muscular layer was thickened with heavy infiltration with neutrophils and eosinophils. Serosal exudates and vascular congestion was also seen (Fig. 3).

In cases without acute inflammatory cells apparent normal mucosa was seen. The submucosa revealed the presence of lymphoid aggregates, chronic inflammatory infiltrate along with eosinophils (Fig. 4).

The lumen in all cases contained numerous parasites with histological characteristic features consistent with enterobius vermicularis. In 10/16 cases longitudinal and transverse sections of the parasite were seen lying within the fecolith (Fig. 4). The remaining five cases showed the presence of the presence of gravid female parasite with plano convex eggs and characteristic two lateral alae, also known as hooklets. (Fig. 5,6). A diagnosis- acute appendicitis secondary to enterobius vermicularis was rendered.

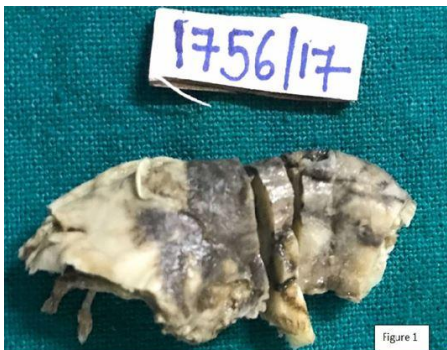

Fig. 1: Resected specimen of the appendix showing edematous wall with thickening

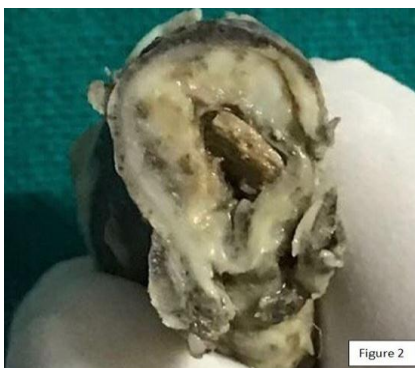

Fig. 2: Cut surface of resected specimen of the appendix showing thickened wall, presence of stercolith and the absence of appendicular septa

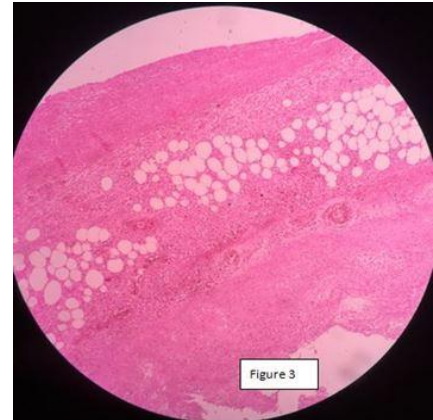


Fig. 3: Microphotograph shows wall of the appendix with inflammation, ulceration and periappendicitis (H&E x 50)

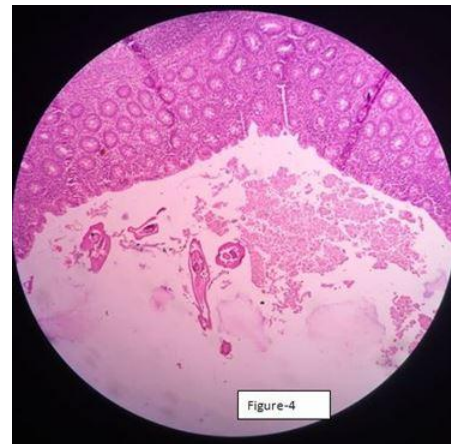


Fig. 4: Microphotograph shows wall of the appendix with chronic inflammation and a part of lymphoid follicle with the presence of parasites in the lumen (H&E x 50)

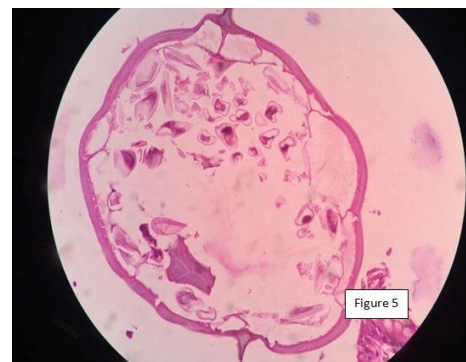


Fig. 5: Microphotograph shows the presence of gravid female parasite with eggs and characteristic two lateral alae (H&E x 400)

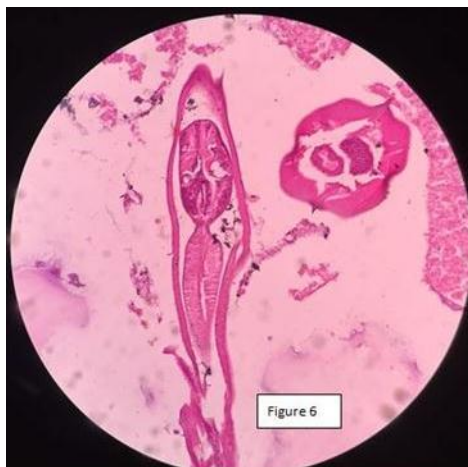

Fig. 6: Microphotograph shows the presence of transverse and longitudinal section of the parasite in the lumen of the appendix with characteristic the hooks (H&E x 100)

Discussion

Enterobius vermicularis is one of the most common intestinal nematode in human population, affecting over 400 million people worldwide. Humans are the only known hosts of this parasite.⁹ Humans are infected by the fecal-oral route after ingestion of the eggs of the parasite from contaminated water and food. Intestinal parasitic infections are common in this region. Enterobius vermicularis (Linnaeus 1758), also known by the common names of threadworm, pinworm and seat worm. It is cosmopolitan in distribution, being found all over world. The adult worm (gravid female) lives in the caecum and vermiform appendix of man. They generally remain on the surface of the mucosa and may occasionally encyst in the submucosa.¹⁰

The eggs are laid in the perianal skin and infection occurs by ingestion of their eggs. The life cycle of the worm is completed in the small intestine of man from where the gravid female then migrates to the caecum, colon and appendix and remains there till the eggs develop. It then wanders down to the rectum and works its way out of the anus at night to deposit the eggs in the perianal skin. The significant pathology is the irritation caused by the gravid female around the anus. Clinical manifestation attributed to EV are pruritis periani et perinea, salphingitis, urethritis, nocturnal enuresis and inflammation of the appendix.¹⁰ Other than enterobius vermicularis, schistosoma, taenia and ascaris lumbricoides are the other common parasitic infections related with acute appendicitis.¹⁰

Fabricus first described parasitic infection of appendix in 1634. Later Aschoff and friends in early 1900's declared that the lumen of the appendix may contain parasites in less than 1% cases leading to infection mimicking acute appendicitis and appendicular colic. The role of parasites in acute appendicular infection is still controversial, with very few evidences about their relation. The simple presence

of EV in the appendix can give to symptoms of acute appendicitis. Onset of acute appendicitis may be either due to inflammation occurring secondary to the parasites and their ova or due to obstruction of the lumen by the parasite itself.¹¹ Relationship between EV and appendicitis was first described by Dr. G.F. Still in late nineteenth century.¹²

Retrospective studies have indicated that EV is the commonest worm found in the appendix. It can cause pathological changes ranging from lymphoid hyperplasia to acute phlegmatous inflammation and life threatening complications like gangrene and peritonitis.¹³

Along with clinical examination, a detailed history regarding loss of appetite, insomnia, pruritis in perianal region must be taken and elicited especially in children. Along with it, other routine investigations, blood for eosinophilia, stool floatation test for microscopic detection of eggs, direct visualization of adult worms and night time application of cellophane tape can aid in accurate diagnosis of the condition. Though night time application of cellophane tapes are said to have poor sensitivity,¹⁴ their use is still advocated.

The extraintestinal manifestations of EV can be attributed to the aberrant entry of these worms to the peritoneal cavity via the fallopian tubes. They have also been reported in the liver, lungs and bladder.¹⁰

In the present study the range of age group was between 7-30 years similar to the study by Ayden O.⁶ There was a male predominance in the present study.

Appendectomies of patients with EV usually show no signs of acute inflammation.^{6,9,15} The histological findings in appendectomies range from normal to various histological patterns like lymphoid hyperplasia, eosinophilic and neutrophilic infiltrate and perforation.^{5,6,16}

In the present study EV was associated with acute inflammation and eosinophils in 40% cases (Table 3). Few other studies also had similar findings of EV being associated with acute inflammation.^{5,15,17-19} The presence of inflammation has been postulated due to the presence of worm in the wall or due to luminal obstruction by the parasite itself.^{5,11,20} Way back in 1919, inflammation of the ileocolic region caused by EV was reported. It still remains controversial.²¹

In the present study 9/16 cases (60%) (Table 3) had the presence of abundant eosinophils in the submucosal layer. The presence of eosinophils strongly warrants the search for parasites in the appendix. Our study also advocates the same.

EV was not associated with the presence of acute inflammation in 40% cases (Table 3). Lymphoid hyperplasia and chronic inflammation was seen in these cases. Few other studies also had similar findings.^{4,6,13}

Appendicular colic was present in all the cases independent of the presence of acute inflammation. This was similar to the findings of other studies.^{6,9,11,15,19} This was also the cause of the clinical

appendiceal syndrome as coined by Ayden O.⁶ This can be explained by the hypothesis of appendiceal lumen obstruction due to the presence of pinworms in the lumen.⁶ However it is difficult to differentiate appendicular colic caused by parasitic infection from that caused by acute appendicitis.

In the present study we also evaluated the other histopathological feature associated with the presence of EV along with the modified Alvarado score and the pre operative diagnosis of acute appendicitis (Table 3). It was observed that, in the absence of acute inflammation the modified Alvarado score was at the threshold or just below the threshold. A score of seven or more is strongly predictive of a preoperative diagnosis of acute appendicitis.⁸ As acute appendicitis can manifest with unclear clinical features, various scoring systems were created to aid in decision making. Alvarado score, Eskelinen score and Ohmann scores are the different scoring systems used in the diagnosis of acute appendicitis.²² The modified Alvarado score is one of most frequently used scoring systems. This score was used in the present study. It does not include the left shift of neutrophilic granulocytes as one of its parameters as was used in the original Alvarado score.²² Similarly, one study used the Eskelinen score as the scoring system in the study of appendectomies that had the histological presence of EV.⁶ In view of the above facts the surgeon must always keep in the mind the possibility of the presence of worms in the appendix when performing appendectomies.

Conclusion

The present study describes a subset of patients having a curable infectious disease as management of these patients is different from that of acute appendicitis. It also further highlights the importance of histopathological examination of every resected specimen of appendix along with calculation of the modified Alvarado score is in all cases of acute appendicitis, especially those having suspicious clinical findings suggestive of parasite infestation. Detection of parasite can only be done by the gold standard histopathologic examination of the appendices. Management of these patients with parasites warrants antihelminthic medication. Detailed history taking and night time application of cellophane tape can aid in accurate diagnosis of the condition and is advocated.

References

1. Flum DR, Koepsell T. The clinical and economic correlates of misdiagnosed appendicitis. *Arch Surg* 2002;137:799-804.
2. Shelton T, McKinlay R, Schwartz RW. Acute appendicitis current diagnosis and treatment. *Curr Surg* 2003;60:502-5.
3. Yildirim S, Nursal TZ, Tarım A, Kayaselcuk F, Noyan T. A rare cause of acute appendicitis: parasitic infection. *Scand J Infect Dis* 2005;37:757-9.

4. Sinha RT, Dey A. A retrospective study of histopathological features of appendectomy specimens – What all can expect? *J Med Sci Health* 2016;2:6-12.
5. Marjorie JA, Robert LG, Jonathan IG, Sue H, Donna AC: Clinical manifestations of appendical pinworms in children: an institutional experience and a review of literature. *Pediatr Surg Int* 2004;20:372-5.
6. Ayden O: Incidental parasitic infestation in surgically removed appendices: a retrospective analysis. *Diagnostic Pathology* 2007;2:16.
7. Cook GC. *Enterobius vermicularis* infection. *Gut* 1994;35:1159-62.
8. Alvarado A. A practical score for the early diagnosis of acute appendicitis. *Ann Emer Med* 1986;557-64.
9. Kucik CJ, Martin GL, Sorter BV. Common intestinal parasites. *Am Family Phys* 2004;69:1161-8.
10. K.D Chatterjee: Helminthology. In: Parasitology (Protozoology and Helminthology) in relation to clinical medicine. 5th ed., 1965:156-159.
11. Dorfman S, Cardozo J, Dorfman D, Del Villar A. The role of parasites in acute appendicitis of pediatric patients. *Invest Clin* 2003;44:337-40.
12. Still GF. Oxyuris Vermicularis in children. *Br Med J*. 1899;1:898-900.
13. da Silva DF, da Silva RJ, da Silva MG, Sartorelli AC, Rodrigues MA. Parasitic infections as a cause of acute appendicitis. *Parasitol Res* 2007;102:99-102.
14. Jardine M, Kokai G, Dalzell M. *Enterobius vermicularis* and colitis in children. *J Pediatr Gastroenterol Nutr* 2006;43:610-2.
15. Lala S, Upadhyay V. *Enterobius vermicularis* and its role in paediatric appendicitis: protection or predisposition? *ANZ J Surg* 2016;86:717-9.
16. Lamps LW. Infectious causes of appendicitis. *Infect Dis Clin N Am*. 2010;24:995-1018.
17. Saxena AK, Springer A, Tsokas J, Willital GH. Laparoscopic appendectomy in children with *Enterobius vermicularis*. *Surg Laparosc Endosc Percutan Tech* 2001;11:284-6.
18. Beattie R, Walker-Smith A, Domizio P. Ileal and colonic ulceration due to *Enterobius*. *J Paediatr* 1995;132:1055-6.
19. Efaled B, Atsame-Ebang G, Soumana BM, Tahiri L, Hammam N, El Fatemi H et al. Acute suppurative appendicitis associated with *Enterobius vermicularis*: an incidental finding or a causative agent? A case report. *BMC Research Notes* 2017;10:494.
20. Sodergren MH, Jethwa P, Wilkinson S, Kerwat R. Presenting features of *Enterobius vermicularis* in the vermiform appendix. *Scand J Gastroenterol* 2009;44:457-61.
21. Wiebe BM. Appendicitis and *Enterobius vermicularis*. *Scand J Gastroenterol* 1991;26:336-8.
22. O'Connell PR. The vermiform appendix. In: Russell RC, Williams NS, Bulstrode CJ, editors. *Bailey and Love's Short Practice of Surgery*. 26th ed. London: Arnold Hodder; 2010. p.1203-18.