

Study of immunohistochemical expression of P53 In colorectal carcinoma

Pragati Singh¹, Tanu Agrawal^{2*}, S.K Sagar³, Shubhanshu Gupta⁴, Monika Nayak⁵

^{1,5}Junior Resident, ^{2,3}Professor, ⁴Assistant professor, ¹⁻⁵Dept. of Pathology, ¹⁻⁵Shri Ram Murti Smarak Institute of Medical Sciences, Nainital Road Bareilly, Uttar Pradesh, India

*Corresponding Author: Tanu Agrawal

Email: tanuagrawal510@yahoo.co.in

Abstract

Introduction: *p53* is a very commonly mutated gene in colon cancer and the prevalence of *p53* mutations in colorectal cancer varies from 40 to 60% in various studies. Molecular pathogenesis of colorectal cancer commonly involves mutation in *p53* gene which leads to expression of *p53* protein in tumor cells. Some studies have reported that the presence of *p53* mutations in colon cancer indicates a relatively poor prognosis, while other studies have failed to show such a relationship.

Observation: The present study was done to study *p53* expression in colorectal carcinoma and to correlate it with various pathological factors i.e. tumor size, tumor type, grade of tumor and depth of invasion.

Materials and Methods: We studied 38 cases of colorectal carcinoma (29 non mucinous adenocarcinoma and 9 mucinous adenocarcinoma). *p53* expression was evaluated by immunohistochemistry. The correlation between *p53* protein overexpression and each variable was evaluated using Chi-square analysis and Fisher Exact test.

Results: Positive *p53* immunostaining was observed in 58%. *p53* expression showed an increasing trend with increasing histological grade and the difference was statistically not significant. *p53* overexpression was related to the depth of tumor invasion which was maximum in stage pT4 followed by stage pT3 and stage pT2 and the difference was statistically significant (p value = 0.032). No significant correlation was found between *p53* expression and size, type and grade of tumor in colorectal carcinoma.

Keywords: *p53*, Colorectal carcinoma, Immunohistochemistry.

Introduction

Colorectal cancer (CRC) is the third most commonly diagnosed cancer in males and the second in females and approximately 10% of all incident cancer cases are believed to occur each year.^{1,2} The etiology of colorectal cancer is complex. It develops through a multistep process involving molecular genetic alterations including adenomatous polyposis coli (APC), K-ras, and *p53*.³

The *p53* tumor suppressor gene (TP53) is the most commonly mutated gene in human tumors and is localized to chromosome arm 17p13.⁴ *p53* negatively regulates the cell cycle and requires loss of function mutations for tumor formation. Loss of *p53* function may result in defective DNA replication and malignant transformation, increased genetic instability, changes in ploidy, and survival of cells with an increased mutational load.⁵ *p53* is also a genomic stabilizer and an inhibitor of angiogenesis. *p53* mutations are predominantly inactivating and can induce changes in protein conformation.⁶ In various studies, it was found that nuclear accumulation is usually not detectable due to the short half-life (5–20 min) of the wild-type protein.⁷ In contrast, *p53* mutations result in the production of *p53* proteins with a prolonged half-life leading to nuclear protein accumulation.⁸ So, most of the antibodies used in immunohistochemical studies detect both the wild type as well as the mutant form of the protein.⁹

TP53 contribute to human cancers in different ways. First is the somatic mutations which is observed frequently in most cancers and the main modes of TP53 inactivation are single-base substitution and loss of alleles, with inactivation by viral or cellular proteins.¹⁰ Second, inheritance of a TP53 mutation causes predisposition to early-onset cancers including breast carcinomas, sarcomas,

brain tumors, and adrenal cortical carcinomas.¹¹ Third, TP53 is highly polymorphic in as coding and noncoding regions and some of these polymorphisms which can increase cancer susceptibility and modify cancer phenotypes in TP53 mutation carriers.¹²

Allelic losses and point mutations in the counterpart of the locus of *p53* gene in chromosome 17 are frequently observed in tumors of colon, breast, lung, brain and esophagus.^{13,14} The functional loss of *p53* in colorectal carcinoma was proposed as a late event in the transition from adenoma to carcinoma.¹⁵

The objective of current study was to estimate *p53* expression in colorectal carcinoma and to correlate it with various pathological factors i.e. tumor size, tumor type, grade of tumor and depth of invasion.

Materials and Methods

We studied 38 surgically resected histologically proven cases which were submitted to the department of pathology in Sri Ram Murti Smarak Institute of Medical Sciences between January 2015 and December 2017. The record of brief clinical history with age, sex, specimen number were taken from the records and recorded in the proforma.

Paraffin embedded 4-micron tumor sections obtained from patients with CRC were utilized. Haematoxylin and Eosin staining was done by deparaffinising the section with xylene and rehydration in absolute ethyl ethanol followed by 95% ethyl alcohol. Then, it was washed with tap water, stained with Harris hematoxylin, differentiated with 1% hydrochloric acid, bluing with running tap water and stained with eosin. It was rinsed in water, then kept in increasing concentration of alcohol and cleared in xylene and mounted in DPX. For IHC staining for *p53* antibody, 2 – 3 microns

thick sections were cut and floated on a positive charged slide which was incubated for 37°C for a day and further at 58°C for over-night. The section was deparaffinized with xylene and rehydrated in alcohol, rinsed in distilled water and antigen retrieval was done by heat using microwave oven. It was rinsed in distilled water, washed in Tris Buffered Saline (TBS), then treated with peroxidase block and primary antibody for p53 (Mouse Monoclonal Antibody) and washed in TBS buffer (pH -7.6) three times. Then, treated with Super Sensitive enhancer and washed in TBS buffer, covered with Super Sensitive polymer (secondary antibody) and washed again in TBS buffer. Antibody was localized with diaminobenzidine (DAB) working solution and washed in buffer followed by water. Counter stained with Harris haematoxylin and washed in tap water to remove excess stain. Again, it was deparaffinized with xylene, dehydrated with alcohol, cleared with xylene and mounted.

All slides were evaluated for immunostaining without knowledge of the histological diagnosis. Immunohistochemical expression of p53 was calculated as percentage. Cases with p53 expression in more than 10% cells were considered positive for p53 expression.

Correlation of p53 expression with clinicopathological variables namely tumor size, tumor type, grade and depth of invasion was analysed by applying Pearson's Chi Square test and Fisher exact test. Staging was done using AJCC Staging System. Statistical analysis was performed using SPSS version 20 and p-value of less than 0.05 was

considered statistically significant at 95% level of significance.

Results

This study included 38 patients with colorectal cancer. Out of 38 cases of colorectal carcinoma, maximum cases (34%) were observed in age range 41-50 years and mean age of presentation was 50 years. 23 cases were males and 15 cases were females with M:F ratio was 1.53:1. Clinicopathological variables from patients with colon cancer are summarized in Table 1.

p53 was expressed in 22 cases (58%) of colorectal carcinoma. The relationship between p53 protein overexpression and various clinicopathologic variables are summarized in Table 2.

No significant correlation was found between p53 expression and size of tumor in colorectal carcinoma (p value=0.62).

No significant correlation was found between p53 expression and type of tumor in colorectal carcinoma (mucinous versus non-mucinous; p value=0.54).

p53 expression showed an increasing trend with increasing histological grade and the difference was statistically not significant (p value=0.81). (Fig. 1-3)

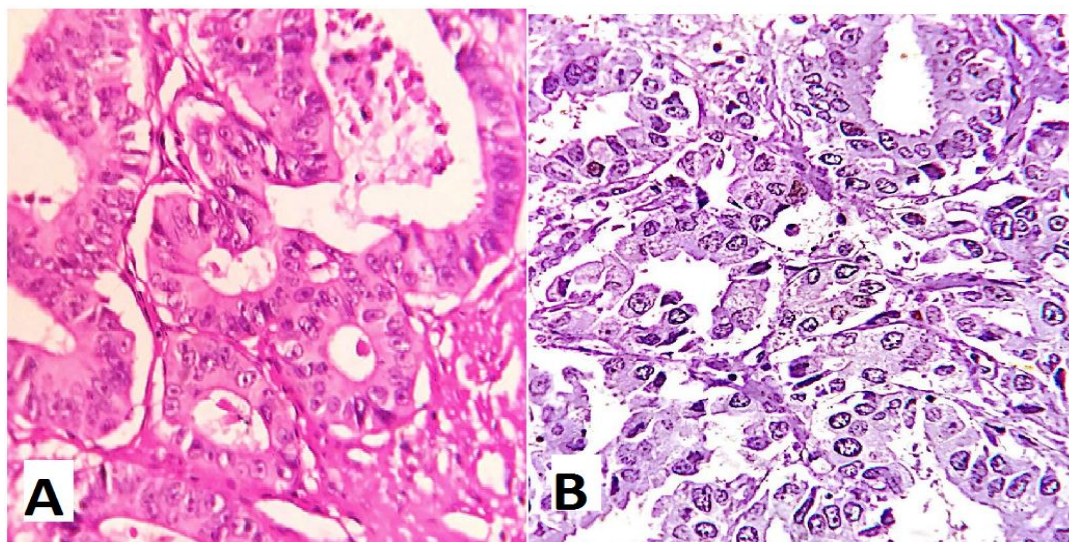
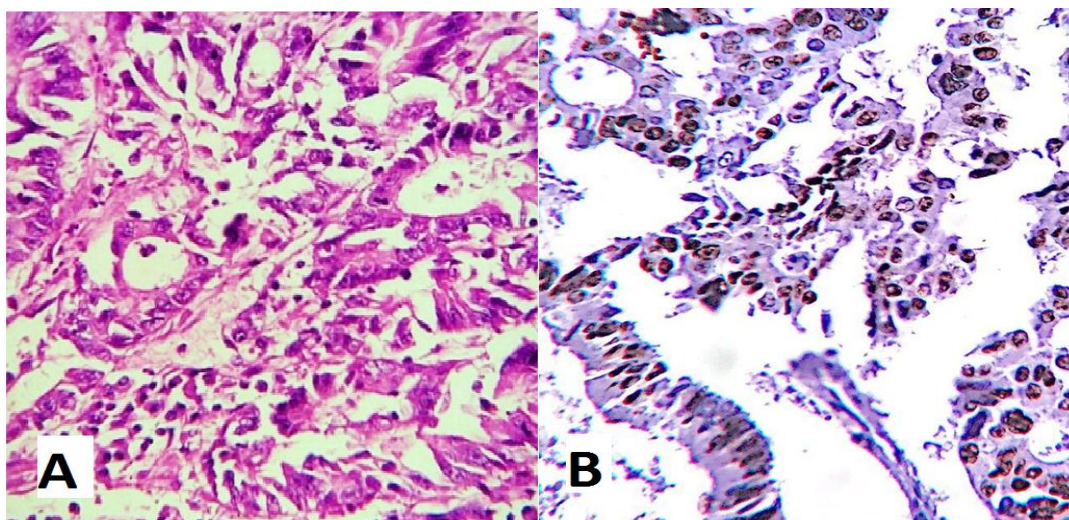
p53 overexpression was related to the depth of tumor invasion which was maximum in stage pT4 followed by stage pT3 and stage pT2 and the difference was statistically significant (p value = 0.032).

Table 1: Clinicopathologic variables from patients with colon cancer

Clinicopathologic variables	Number of cases	Percentage of cases
All cases	38	
Gender		
Males	23	60.50%
Females	15	39.50%
Tumor size		
≤ 4 cm	16	42%
> 4 cm	22	58%
Tumor type		
Mucinous adenocarcinoma	9	24%
Non mucinous adenocarcinoma	29	76%
Histological Grade		
WD	6	16%
MD	23	60%
PD	9	24%
Depth of invasion		
pT1	0	0
pT2	7	18%
pT3	25	66%
pT4	6	16%

Table 2: p53 overexpression and its relation to clinicopathologic variables.

Clinicopathologic variables	No.	p53 positive n (%)	P value
All cases	38		
Tumor size			
≤ 4 cm	16	10(62.5%)	0.62
> 4 cm	22	12(54.5%)	
Tumor type			
Mucinous adenocarcinoma	9	6(66.7%)	0.54
Non mucinous adenocarcinoma	29	16(55%)	
Histological Grade			
WD	6	3(50%)	0.81
MD	23	13(56.5%)	
PD	9	6(66.7%)	
Depth of invasion			
pT1	0	0	0.032
pT2	7	2(28.6%)	
pT3	25	14(56%)	
pT4	6	6(100%)	

**Fig. 1:** Well differentiated Adenocarcinoma. A. Haematoxylin and Eosin (40X); B. p53 expression (40X)**Fig. 2:** Moderately differentiated Adenocarcinoma. A. Haematoxylin and Eosin (40X); B. p53 expression (40X)

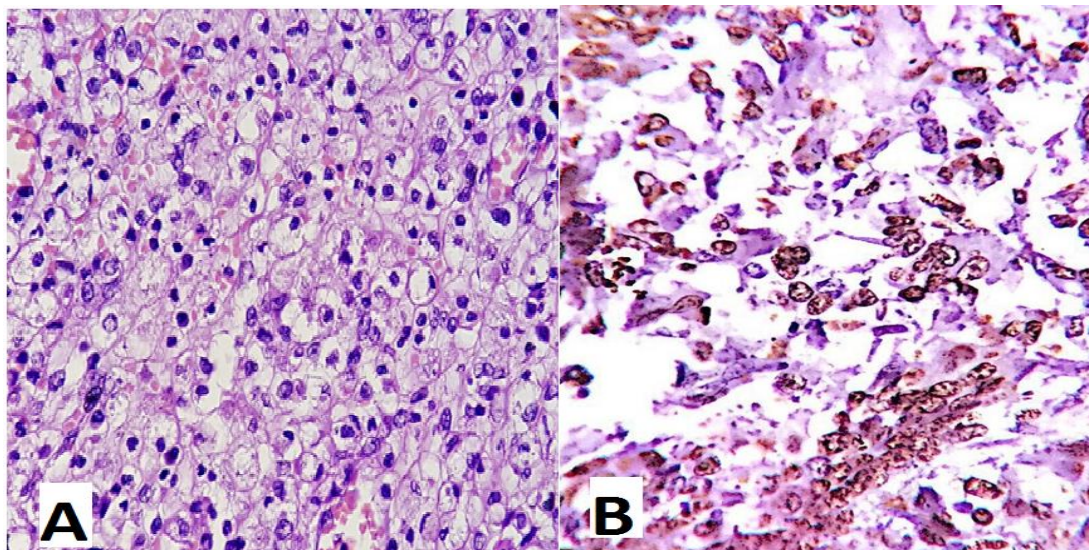


Fig. 3: Poorly differentiated Adenocarcinoma. A. Haematoxylin and Eosin (40X); B. p53 expression (40X)

Discussion

Colorectal carcinoma is one of the most common malignancies with high prevalence and low 5 year survival. Colorectal carcinoma is a heterogeneous disease and have a complex, genetic and biochemical background. Intracellular signaling pathways, including Wnt/ β -catenin signaling, Ras signaling, and p53 signaling are frequently dysregulated in CRC. p53 protein induces cell cycle arrest, senescence, and apoptosis under cellular stress. Patients with mutant p53 gene are often resistant to current therapies that leads to poor prognosis.¹⁶

Mutations of p53 are found in approximately half of all CRC cases, with a higher frequency observed in distal colon and rectal tumors as compared with proximal tumors. Alterations to this gene are likely to have very little or no prognostic significance in CRC patients treated by surgery alone, but may be associated with marginally worse survival for patients treated with chemotherapy.¹⁷

In this study, 38 cases of colorectal carcinoma were analysed. Maximum cases (34%) were in the age group of 41-50 years followed by 26% in age group 51-60 years (range, 25-75 years). Mean age of presentation was 50 years. 23 cases (61%) were males and 15 cases (39%) were females. M:F ratio was 1.53. Rambau et al in a study on 109 Ugandan patients found that mean age of the patients was 48.4 years (range, 13- 85 years) which was similar to the present study. Also in the same study, 56.8% were males.¹⁸

p53 overexpression was seen in 58% of colorectal carcinoma. The prevalence is similar to what have reported and varies from 40 to 60% in various studies.^{19,20} Iacopetta B reported that approximately half of all colorectal cancers show p53 gene mutations, with higher frequencies in distal colon and rectal tumors.¹⁷ The overexpression of p53 seen in this study and other previous studies, support the hypothesis that p53 gene mutations are important in colorectal carcinogenesis. This is also supported by results from a

number of studies showing that p53 expression is positively correlated with p53 gene mutation.²¹⁻²³

In the present study, 22 cases (58%) were of > 4 cm tumor size and 16 cases (42%) were of \leq 4 cm. Out of 22 cases, 12 cases (54.5%) showed p53 positivity in cases with tumor size of > 4cm and out of 16 cases, 10 cases (62.5%) showed p53 positivity in cases with tumor size of \leq 4 cm size. Cao et al in a study found similar results. They included 484 patients with colon cancer and found 272 cases (56%) to be of > 4 cm tumor size and 212 cases (44%) were of \leq 4 cm tumor size, however, p53 positivity rate was 63.2% in cases with > 4 cm tumor size and 38.2% in cases with \leq 4 cm tumor size (p value = <0.001).²⁴

In our study, 29 cases (76.3%) were non mucinous adenocarcinoma and 9 cases (23.7%) were mucinous adenocarcinoma and found 16 cases out of 29 cases (55%) to be positive for p53 expression in non mucinous adenocarcinoma and 6 cases out of 9 cases (66.7%) in mucinous adenocarcinoma. Lanza et al reported 183 out of 204 cases (89.7%) of non mucinous adenocarcinoma, of which 120 (65.6%) were positive and 21 (10.3%) cases of mucinous adenocarcinoma, of which 4 cases (19%) were positive for p53 expression.²⁵ Ghavam-Nasiri et al in an another study on 100 patients found 78 cases (78%) of non mucinous adenocarcinoma and 22 cases (22%) of mucinous adenocarcinoma and 47 cases (60.2%) were positive for p53 overexpression in non mucinous adenocarcinoma and 12 cases (54.5%) were positive in mucinous adenocarcinoma and the result was statistically not significant (p value = 0.63).²⁶

p53 positivity was observed in 6 cases out of 9 (66.7%) in poorly differentiated carcinoma followed by moderately differentiated which showed 56.5% positivity (13 out of 23 cases), then well differentiated carcinoma and showed 50% positivity (3 cases out of 6). p53 expression showed increasing trend with increased histological grade and the difference was not statistically significant (p value = 0.81). The results was similar to that of Starzynska et al.²⁷ In a

study, Starzynska et al studied the prognostic significance of p53 overexpression on both gastric and colorectal carcinoma and found that out of 107 cases of colorectal carcinomas, p53 positivity in 5 out of 10 cases (50%) of poorly differentiated, 33 cases out of 70 cases (47%) of moderately differentiated carcinoma and 11 out of 27 cases (40.7%) of well differentiated carcinoma and the results was not significant.²⁷ Whereas, Lan et al found that well to moderately differentiated tumors had significantly higher frequency of p53 overexpression than poorly differentiated tumors (40.0 vs 20.0%, $p=0.050$).²⁸

In our study, 7 cases (18.4%) were in stage T2, 25 cases (65.8%) in stage T3 and 6 cases (15.8%) in stage T4. Out of 7 cases, 2 cases (28.6%) were positive for p53 overexpression in stage T2. Out of 25 cases, 14 cases (56%) were positive in stage T3. Out of 6 cases, all cases (100%) were positive in T4. Hence, it suggests that p53 overexpression was related to the depth of tumor invasion and was maximum in stage pT4 followed by stage pT3 and stage pT2 and the difference was statistically significant (p value = 0.032). The odoropoulos et al in a study in Greece on 164 patients reported 12 cases (7.3%) in T1 stage, 16 cases (28%) in T2 stage, 80 (48.7%) cases in T3 stage, and 26 cases (16%) in T4 stage and p53 positivity was reported in 3 cases (50%) in stage T1, 16 cases (34.8%) in stage T2, 60 cases (75%) in stage T3 and 22 cases (84.6%) in stage T4 (p value = 0.004).²⁹ In an Indian study by Vandana et al found similar results with stage I showed only 50% p53 positivity, stage II showed 66.6% p53 positivity. stage III showed 80% p53 positivity and stage IV showed 83% p53 positivity in conventional adenocarcinoma and there is statistically significant correlation between stage and p53 expressions.³⁰

Conclusion

p53 overexpression was seen in 58% cases of colorectal carcinoma suggesting that p53 mutation has an important role in the pathogenesis of colorectal cancer.

p53 overexpression was significantly related to the depth of tumor invasion and it was more common in tumors of higher pathological T stage indicating a poorer prognosis.

Further studies performed on large series of patients are needed to accurately evaluate the significance of p53 expression in colorectal cancer.

Conflict of Interest: None.

References

- Jemal A DVM, Bray F, Melissa M, Ferlay J, Ward E, Forman E. Global Cancer Statistics. *CA Cancer J Clin* 2011;61:69–90.
- Parkin DM, Pisani P, Ferlay J. Global cancer statistics. *CA Cancer J Clin* 1999;49: 33.
- Vogelstein B, Fearon ER, Hamilton SR, Kern SE, Preisinger AC, Leppert M, et al. Genetic alterations during colorectal-tumor development. *N Engl J Med* 1988;319:525–32.
- Hollstein M, Sidransky D, Vogelstein B, Harris CC. 1991. p53 mutations in human cancers. *Sci* 253:49–53.
- Levine AJ. p53, the cellular gatekeeper for growth and division. *Cell* 1997; 88:323–31.
- Dameron KM, Volpert OV, Tainsky MA, Bouck N. Control of angiogenesis in fibroblasts by p53 regulation of thrombospondin-1. *Sci* 1994;265:1582–4.
- Giaccia AJ, Kastan MB. 1998. The complexity of p53 modulation: emerging patterns from divergent signals. *Genes Dev* 12:2973–83.
- Bodmer W, Minna JD, Jensen SM, D'Amico D, Carbone D, Mitsudomi T et al. Expression of mutant p53 proteins in lung cancer correlates with the class of p53 gene mutation. *Oncogene* 1992;7:743–749.
- Bosari S, Viale G. The clinical significance of p53 aberrations in human tumours. *Virchows Arch* 1995;427:229–241.
- Tommasino M, Accardi R, Caldeira S, Dong W, Malanchi I, Smet A, Zehbe I. 2003. The role of TP53 in Cervical carcinogenesis. *Hum Mutat* 21:307–12.
- Olivier M, Goldgar DE, Sodha N, Ohgaki H, Kleihues P, Hainaut P et al. Li-Fraumeni and related syndromes: Correlation between tumor type, family structure, and TP53 genotype. *Cancer Res* 2003;63: 6643–50.
- Whibley C, Pharoah PD, Hollstein M. 2009. p53 polymorphisms: cancer implications. *Nat Rev Cancer* 9:95–107
- Hollstein MC, Metcalf JA, Welsh JA. Frequent mutation of the p53 gene in human esophageal cancer. *Proc Natl Acad Sci USA* 1990;87:9958–61.
- Baker SJ, Preisinger AC, Jessup JM. p53 gene mutations occur in combination with 17p allelic deletions as late events in colorectal tumorigenesis. *Cancer Res* 1990;50:7717–772.
- Baker SJ, Markowitz S, Fearon ER, Willson JK, Vogelstein B. 1990. Suppression of human colorectal carcinoma cell growth by wild-type p53. *Sci* 249:912–5.
- Li XL, Zhou J, Chen ZR, Chng WJ. p53 mutations in colorectal cancer- molecular pathogenesis and pharmacological reactivation. *World J Gastroenterol* 2015;21(1): 84–93.
- Iacopetta B. TP53 mutation in colorectal cancer. *Hum Mutat* 2003;21:271–6.
- Rambau PF, Odida M, Wabinga H. p53 expression in colorectal carcinoma in relation to histopathological features in Ugandan patients. *Afr Health Sci* 2008;8:234–8
- Elsaleh H, Powell B, McCaul K, Grieu F, Grant R, Joseph D, et al. P53 alteration and microsatellite instability have predictive value for survival benefit from chemotherapy in stage III colorectal carcinoma. *Clin Cancer Res* 2001;7:1343 – 9.
- Nasierowska-Guttmejer A, Trzeciak L, Nowacki MP, Ostrowski J. P53 protein accumulation and p53 gene mutation in colorectal cancer. *Pathol Oncol Res* 2000;6:275–9.
- Zhao D, Ding X, Peng J, Zheng Y, Zhang S. Prognostic significance of bcl-2 and p53 expression in colorectal carcinoma. *J Zhejiang Univ* 2005;6:1163–9.
- Huang C, Cheng Y, Chen M Shyang Lin, Chou M, Lee H. Different p53 mutation patterns in colorectal tumors from smokers and nonsmokers. *Environ Mol Mutagenesis* 2006;47:527–32.
- Kapiteijn E, Liefers G, Los L. Mechanisms of oncogenesis in colon versus rectal cancer. *J Pathol* 2001;195:171–8.
- Cao DZ, Ou XL, Yu T. The association of p53 expression levels with clinicopathological features and prognosis of patients with colon cancer following surgery. *Oncology lett* 2017;13:3538–46.
- Lanza G Jr, Maestri I, Dubini A, Gafa R, Santini A, Ferretti S, et al. P53 expression in colorectal cancer: relation to tumor type, DNA ploidy pattern, and short-term survival. *Am J Clin Pathol* 1996;105:604 – 12.
- Ghavam-Nasiri MR, Razaee E, Ghafarzadegan K, Seilanian-Toosi M, Malekifard H. Expression of p53 in colorectal carcinoma : correlation with clinicopathologic features. *Arch Iran Med* 2007;10:38–42

27. Starzynska T, Bromley M, Ghosh A, Stern PL. Prognostic significance of p53 overexpression in gastric and colorectal carcinoma. *Br J Cancer* 1992;66:558–62.
28. Lan YT, Chang SC, Li AF, Lin TC, Chen WS, Jiang JK et al. p53 protein accumulation as a prognostic marker in sporadic colorectal cancer. *Int J Colorectal Dis* 2007;22:499-506.
29. Theodoropoulos GE, Karafoka E, Papailiou JG, Stamopoulos P, Zambirinis CP, Bramis K, et al. P53 and EGFR expression in colorectal cancer: a reappraisal of ‘old’ tissue markers in patients with long follow-up. *Anticancer Res* 2009;29:785-91.
30. Vandana G, Lokesh Rao Magar S, Swetha D, Sandhya S. An expression of p53 marker in colorectal cancer with histopathological correlation. *IAIM* 2017;4(12):168-84.

How to cite this article: Singh P, Agrawal T, Sagar SK, Gupta S, Nayak M. Study of immunohistochemical expression of P53 In colorectal carcinoma. *Arch Cytol Histopathol Res* 2019;4(2):118-23.