

## Retrospective study of tumor and tumor like lesions of the bone-Tertiary center experience

Jayanthi K.J<sup>1\*</sup>, Niranjan Gowda M.R<sup>2</sup>

<sup>1</sup>Assistant Professor, <sup>2</sup>Professor and Head, <sup>1,2</sup>Dept. of Pathology, <sup>1,2</sup>Sanjay Gandhi Institute of Trauma and Orthopaedics, Bengaluru, Karnataka, India

\*Corresponding Author: Jayanthi K.J

Email: drjayanthikj@yahoo.com

### Abstract

**Introduction:** Bone tumors are important contributors for morbidity and mortality. Our hospital being, trauma and orthopedic institution, many orthopedic cases are referred to our center. We have done this study to determine the pattern of bone tumors, age and sex distribution, clinico pathological characteristics seen in our tertiary orthopedic Hospital.

**Materials and Methods:** The study comprised of bone tumors diagnosed from January 2014 to December 2018 at Sanjay Gandhi Institute of Trauma & Orthopedics, Bangalore. Clinical and radiological details were collected from the data register. Microscopic findings were analyzed on Hematoxylin and eosin stained sections. Special stains and immunohistochemistry were done wherever essential. The bone tumors were classified based on WHO classification of bone tumors.

**Results:** Of the 166 bone biopsies in a period of four years, 28 were malignant, 40 were benign and 14 were tumor like lesions. Most common age group was 11-20 years and were benign. Malignant tumors were common in 51-60 years age with male predominance and most of them were metastatic tumors.

**Conclusion:** Diagnosis of bone tumors and treating them effectively reduces the morbidity and mortality as most of the tumors were benign and common in boys of younger age group. Correlation of clinico radiological features are essential for the conclusive histopathological diagnosis. This helps in planning the treatment and knowing the prognosis of the tumor.

**Keywords:** Bone tumors, tumor like lesions, tertiary care hospital.

### Introduction

Tumors of the bone are rare worldwide. The Surveillance, Epidemiology and End Results (SEER) Cancer Statistics estimate that bone sarcomas represent 0.2% of all malignancies diagnosed in the United States.<sup>1</sup> Although bone tumors are uncommon, they contribute significantly for morbidity and mortality. The incidence of benign bone tumors are more common in second decade of life with predominance in boys. Most of the benign bone tumors have characteristic and specific clinical and radiographic presentation.<sup>2</sup> But, some benign bone processes such as callus may mimic osteosarcoma, osteomyelitis as osteosarcoma and vice versa.<sup>3</sup>

For planning the treatment of bone tumors and knowing the prognosis, interpretation of bone biopsy is indispensable<sup>4</sup> Conclusive histopathological diagnosis is possible only by clinico-radiological correlation such as age, gender, skeletal site, specific area within the bone.<sup>2</sup> As our hospital is a tertiary government orthopedic center, many orthopedic cases are referred to our hospital. There are few published data and literature on bone tumors in and around Bangalore. Our study aims to determine the pattern of bone tumors, age and sex distribution, clinico pathological characteristics seen in our tertiary orthopedic Hospital.

### Materials and Methods

A retrospective cross sectional hospital based study was conducted at Department of Pathology, Sanjay Gandhi

Institute of Trauma & Orthopedics, Bangalore, Karnataka, India. The duration of study was four years from January 2014 to December 2018. The Clinical and Pathological data were collected from medical records and reviewed. Records were analyzed for patient demographics, age, sex and histological type of tumor. The biopsy samples were fixed in 10% buffered neutral formaldehyde. Following one day of fixation, biopsy samples with osseous tissue were decalcified with 5% nitric acid for 2-3 days. The decalcified tissue was processed by increasing concentrations of alcohol and paraffin blocks were prepared. Sections were cut to 4-6 $\mu$ , stained by hematoxylin and eosin and examined under microscope for histopathological examination. Special stains and immune histochemical studies were performed wherever necessary. The final diagnosis was made according to WHO classification. Data tabulation and analysis done to know the relative frequencies of observed data. Results expressed as numbers and percentages.

### Results

In the study period of four years from January 2014 to December 2018, 166 bone biopsies were received in the histopathology department. 82 biopsies were diagnosed as tumor and tumor like lesions. Of these, 40 were benign, 28 were malignant and 14 were tumor like lesions.

**Table 1:** Age and gender wise distribution of the bone tumors

Histological type	Age in years							Gender		Total
	11-20	21-30	31-40	41-50	51-60	61-70	71-80	Male	Female	
Benign	18	05	02	08	03	02	02	31	09	40
Malignant	01	04	02	04	10	03	06	18	10	28
Tumor like	05	03	02	01	02	00	01	09	05	14
Total %	24 29.26%	12 14.63%	06 7.31%	13 15.85%	15 18.29%	05 6.09%	09 10.97%	58 70.73%	24 29.26%	82

The peak age of incidence of bone tumors was in the age group of 11-20 years constituting 29.26%. [Table 1]. All of them were primary bone tumors and tumor like lesions. Second peak was in 51-60 years where the metastatic bone tumors were the commonest tumors. Metastatic tumors contributed to the highest number of malignant tumors accounting for 18 (21.95%) cases. Majority of the cases were of more than 50 years of age (67.85%). The commonest metastatic sites were vertebra, femur, scapula. The sites of primary tumors were lung, breast, thyroid, kidney and unknown cancers. Among metastatic tumors, tumors of unknown origin constituted 7(8.53%) cases.

**Table 2:** Bone tumors according to tissue of origin

Tissue of Origin	Nos	Percentage
Chondrogenic tumors	26	31.71%
Metastatic tumors	18	21.95%
Cystic lesions	17	20.73%
Osteogenic tumors	06	7.32%
Fibrous tumors	04	4.88%
Unknown origin	02	2.43%

Tumors of the cartilaginous origin contributed for majority of bone tumors 26[31.71%]. The chondrogenic tumors were Osteochondroma 12[14.63%], synovial chondromatosis 5[6.09%], chondroblastoma 4[4.87%], Chondrosarcoma 3[3.65%], enchondroma 2[2.43%],

Chondrosarcomas constituted the most common primary bone tumor in our study. Age range was 24-56 years. All the three cases were seen in males. Sites of involvement were vertebra, femur and scapula. All of them were conventional chondrosarcomas. (Fig. 2)

Osseous tumors constituted 69.73% of tumors. Osteoid osteoma-3 cases, osteoma-2 cases, osteoblastoma-One case, with no case of osteosarcoma.

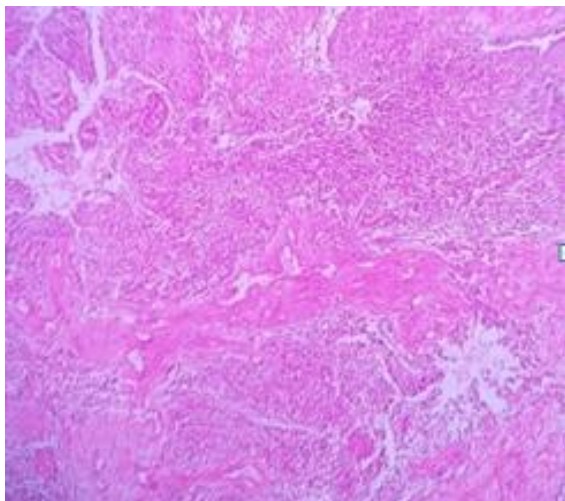
**Table 3:** Histological distribution of the bone lesions

Histological type	Number	Percentage
<b>Malignant tumors</b>		
Chondrosarcoma	03	3.65%
Metastatic tumors	18	21.95%
Plasma cell myeloma	01	1.21%
Spindle cell sarcoma	02	2.43%
Ewing's sarcoma	02	2.43%
Adamantinoma	01	1.21%
Malignant giant cell tumor	01	1.21%
<b>Benign tumors</b>		
Osteochondroma	12	14.63%
Chondroblastoma	04	4.87%
Enchondroma	02	2.43%
Synovial chondromatosis	05	6.09%
Osteoid osteoma	03	3.65%
Osteoma	02	2.43%
Osteoblastoma	01	1.21%
Benign giant cell tumor	11	13.41%
<b>Tumor -like lesions</b>		
Fibrous dysplasia	02	2.43%

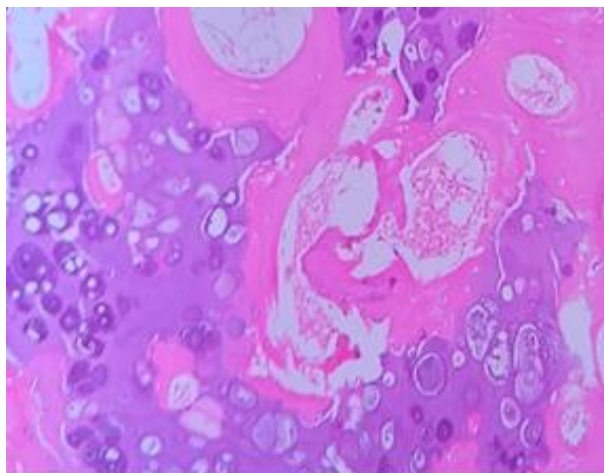
Osteofibrous dysplasia	02	2.43%
Aneurysmal bone cyst	06	7.31%
Solitary bone cyst	04	4.87%
Total	82	100%

Osteochondroma was the most common benign tumor followed by benign giant cell tumor.

Fourteen (17.07%) were tumor like conditions. Age range was 14 years to 70 years. Aneurysmal bone cyst was the most common tumor like lesion seen. Variant of fibrous dysplasia, with abundant cartilage, fibrocartilaginous dysplasia was seen.



**Fig. 1:** Adamantinoma: Biphasic pattern of spindle cells and epithelial islands are seen. Epithelial cells showed cytokeratin positivity. H&E-100x



**Fig. 2:** Chondrosarcoma: malignant chondrocytes are infiltrating bony trabeculae. H&E-400X

## Discussion

Bone tumors are classified as benign or malignant according to tissue of origin, pattern of growth and behavior.<sup>2-5</sup> Majority of the bone tumors are of benign in nature with distinctive and specific radiographic and clinical features.<sup>5</sup> Conclusive diagnosis of bone tumor is possible only by clinico radiological correlation. But, certain lesions can be confused clinically like, traumatic fracture or pathological fracture, osteomyelitis and osteosarcoma. Hence,

histopathological diagnosis is essential to confirm the diagnosis, estimate the prognosis and plan the treatment.

The present study was under taken to find out the pattern of distribution of tumor and tumor like lesions of the bone, and to find out the common type of bone lesion.

## Age Distribution

The age of the patients ranged from 11 to 82 years. The peak incidence was seen in the age group of 11-20 years with 24 cases (29.26%). This is similar to reports by Karuna Jain et al<sup>7</sup> Omololu et al<sup>8</sup> and Mohammed et al<sup>9</sup> in their study of bone tumors. Karuna Jain et al<sup>7</sup> reported that 33.33% of the bone tumors occurred among children. Omololu et al<sup>8</sup> concluded that about 45% of primary malignant bone tumors occurred among patients less than 20 years of age.

## Sex Distribution

In this study, males were predominantly affected with the male to female ratio of 2.41:1. This is similar to other studies who also reported male predominance. Karuna Jain et al<sup>7</sup> reported male predominance of 1.85:1 in bone tumors, Deka MK et al<sup>2</sup> reported in M:F -1.5:1 in bone tumors and tumor like conditions. Relatively higher male to female ratio in our study may be because of the referred cases which are mainly from the socioeconomically weaker sections of the society.

## Histopathological Diagnosis

Osteochondroma was the most common benign tumor in our study constituting 14.63%. This is similar to study by Karuna Jain et al<sup>7</sup> Mohammed et al<sup>9</sup> and Senac et al<sup>10</sup> occurring in 22.22%, 22.50% and 22.3% of the cases respectively.

Giant cell tumour accounted for 13.41% of cases. This is similar to the literature. The most common bones involved were long bones, less commonly, small bones of hands and feet were involved.<sup>11-14</sup>

The less common benign tumours were enchondroma, osteoid osteoma and osteoblastoma, 3, 2, 1 cases respectively. These tumours occur in patients with range of 11-40 years. Enchondroma was seen in hand bones and long bones osteoblastoma in cervical vertebra which can be correlated with literature.<sup>12-14</sup>

Chondrosarcoma was the most common primary malignant bone tumor in our study, in the age group of 40-60 years. Most common sites involved are pelvis, femur, ribs, shoulder girdle and vertebrae with male predilection.<sup>12-14</sup> Among the three cases in our study, all the cases were

seen in males in usual anatomical location. A single case was 24 year old male.

Adamantinoma is a primary low grade, malignant tumor, of unknown histogenesis. It is located predominantly in diaphysis of tibia. Histologically, classic adamantinoma is a biphasic tumor composed of epithelial cells and osteofibrous components. It is a rare tumor comprising 0.1-0.5% of all primary bone tumors.<sup>15</sup> In our study, a case of adamantinoma was seen in 22 year old female patient. It was located in diaphysis of tibia with classical radiological and histological features. IHC showed pan cytokeratin positivity.

Metastatic bone tumors are seen in patients older than 50 years. Femur, pelvis, vertebrae, humerus and ribs are the most common sites of metastasis. The common sites of primary tumors are Lung, GIT, prostate, breast and liver.<sup>12-14</sup> Most lesions present with osteolytic pattern. These are similar to study by Karuna Jain et al<sup>7</sup> and Xu et al.<sup>16</sup> In our study, metastasis of unknown origin were predominant.

### Conclusion

This study showed that bone tumors are more common in males than females. The bone tumors are mainly benign, predominantly in second decade of life. Osteochondroma and chondrosarcoma are the most common primary benign and malignant tumors respectively. Metastatic tumors were the commonest bone tumors. Clinico radiological, pathological correlation is essential for the accurate diagnosis of bone tumors.

**Conflict of Interest:** None.

### References

- Howlader N., Noone A.M., Krapcho M., Garshell J., Miller D., Altekruse S.F et al. SEER Cancer Statistics Review, 1975-2012, National Cancer Institute; 2015. [http://seer.cancer.gov/csr/1975\\_2012](http://seer.cancer.gov/csr/1975_2012) [online].
- Deka MK, Talukdar A.A retrospective analysis of bone tumors and tumor like lesions: a hospital based study of 76 cases. *Int J Res Med Sci* 2017;5:4915-8.
- Modi D, Rathod GB, Delwadia KN, Goswami HM. Histopathological study of bone lesions-A review of 102 cases. *IAIM* 2016;3(4):27-36.
- Pettersson H, Springfield DS, Enneking WF. Radiologic management of musculoskeletal tumors. Philadelphia: Springer publishers: 1999.
- Aboulaiaf AJ, Kennon RE, Jelinek JS. Benign bone tumors of childhood. *J Am Acad Orthop Surg* 1999;7:377-88.
- Aina O J, Adelusola KA, Orimolade AE, Akinmade A, Histopathological pattern of primary bone tumors and tumor-like lesions in Ife, Nigeria. *Pan Afri Med J* 2018;29:193
- Jain K, S, Ravishankar R, M, Rupakumar CS, Gadiyar HB et al. Bone tumors in a tertiary care hospital of south India: A review 117 cases. *Indian J Med Paediatr Oncol* 2011;32:82-5.
- Omololu AB, Ogunbiyi JO, Ogunlade SO, Alonge TO, Adebisi A, Akang EE et al. Primary malignant bone tumors in Ibadan. *West Afr J Med* 2002;21:201-3.
- Mohammed A, Sani MA, Hezekiah IA, Enoch AA. Primary bone tumours and tumour-like lesions in children in Zaria, Nigeria. *Afr J Paediatr Surg* 2010;7:16-8.
- Senac MO Jr, Isaacs H, Gwinn JL. Primary Lesions of bone in 1<sup>st</sup> decade of life: Retrospective survey of biopsy result. *Radiol* 1986;160:491-5.
- Rai KM, Venkateswarlu S. Osteoclastoma. *Indian J Radiol Imaging* 2008;18:4-11.
- Bone RJ, Joints. In: Rosai J, editor. *Ackerman's Surgical Pathology*. St. Louis: Mosby; 1996;1917-2020.
- Aston W, Briggs T, Solomon L. Tumors. In: Solomon L, Warwick D, Nayagam S, editors. *Apley's System of Orthopaedics and Fractures*. 9<sup>th</sup> ed. London: Hodder Arnold, Hodder education; 2010. p.187-224.
- Rosenberg AE. Bones, joints and soft tissue tumors. In: Kumar V, Abbas AK, Fausto N, Aster JC, editors. *Robbins and cotran; Pathologic Basis of disease*. 8<sup>th</sup>ed. Gurgaon: Elsevier, Reed Elsevier India private limited; 2010. p. 1205-56.
- Mirra JM. Adamantinoma and fibrous dysplasia, In: Mirra JM, editor. *Bone tumors*. 1. Lea & Febiger, Philadelphia; 1989. pp1203-1231
- Xu DL, Zhang XT, Wang GH, Li FB, Hu JY. Clinical features of pathologically confirmed metastatic bone tumors—a report of 390 cases. *Ai Zheng* 2005;11:1404-7.

**How to cite this article:** Jayanthi KJ, Gowda NMR. Retrospective study of tumor and tumor like lesions of the bone-Tertiary center experience. *Arch Cytol Histopathol Res* 2019;4(2):124-7.