



Original Research Article

A histomorphological pattern analysis in endometrial biopsies of infertile woman

CR Preethi¹, BM Soumya^{1,*}, Himani Gupta¹, Anvita Nilekani¹, KS Rajashekar¹

¹Dept. of Pathology, JJM Medical College, Davangere, Karnataka, India



ARTICLE INFO

Article history:

Received 26-06-2019

Accepted 01-08-2019

Available online 01-10-2019

Keywords:

Endometrial biopsy

Infertility

Tuberculous endometritis

ABSTRACT

Introduction: Infertility is an agonising problem to many couples, giving them a sense of hopelessness. The hormonal alterations gives rise to various histological patterns in endometrium.

Aims and Objective: To know the various morphological patterns of endometrium in females presenting with infertility (primary/secondary)

Materials and Methods: A cross-sectional study in which 237 cases of endometrial biopsies were reviewed along with clinical data, in infertile woman (primary/secondary) from January 2016 to December 2018. The results were analysed and interpreted.

Results: Of the 237 biopsies, 196 cases (82.7%) were of primary infertility and 41 cases (17.3%) of secondary infertility. Overall mean age was 28.3 years. The most common endometrial pattern was secretory phase (35.86%) followed by proliferative phase (30.8%). Disordered proliferative phase was seen in 17.7% cases. There were 23 cases of simple cystic hyperplasia and one case of complex hyperplasia. 5 cases each of polyp and tuberculous endometritis were diagnosed and two coincidental cases of endometrial carcinoma. One case was reported as Arias-Stella reaction.

Conclusion: Secretory phase of endometrium was the most common morphological pattern which suggests that despite of ovulation there could be other causes that might have led to this ailment. This study also proposes that endometrial biopsies can be used as a primary diagnostic tool especially in cases of unexplained infertility that could be due to tuberculosis or polyps.

© 2019 Published by Innovative Publication.

1. Introduction

Infertility is an agonising problem to the many couples, giving them a sense of hopelessness. In a country like India wherein the population explosion is a matter of concern, talking about infertility seems a bit ironic. But nevertheless stigmatization of infertility has been present since ages and hence has become imperial to know the cause and the various modalities of treatment to curb it.

WHO defines infertility as “ a disease of reproductive system defined by the failure to achieve a clinical pregnancy after 12 months or more of regular unprotected sexual intercourse.” Primary infertility is condition wherein the couple has never conceived and secondary wherein the couple has conceived previously, though not necessary to have had a successful outcome.¹

* Corresponding author.

E-mail address: soumyamahesh89@gmail.com (B. M. Soumya).

Endometrium is subjected to cyclical hormonal changes which are secreted from ovaries and via hypothalamic-pituitary-ovarian axis. Endometrium has two phases in a normal ovulating female. The earliest sign of ovulation is subnuclear vacuolation which coincides with LH surge. LMP and menstrual history are required for correct dating of endometrium which helps in diagnosing changes related to hormonal deficiency.^{2,3} These hormonal alterations gives rise to various histological patterns in endometrium and patterns can reflect the hormonal disturbances leading to infertility.^{4,5}

2. Materials and Methods

This was a cross-sectional study conducted in Department of Pathology, JJM medical college from January 2016 to December 2018. A total of 237 premenstrual endometrial biopsies were evaluated. All the patient suffering from

primary/ secondary infertility were included and patient suffering from DUB/AUB and non-diagnostic biopsies were excluded. Patient variables noted were age, obstetric history, menstrual cycle and last menstrual period. The endometrial biopsies were received in 10% formalin, 3 to 5 microns thick sections were made from formalin fixed, paraffin-embedded blocks and stained with H&E. Ziehl Neelsen stain was performed in suspected tuberculous endometritis cases. Morphological evaluation was done wherein the cyclical phase, hyperplasia, presence of endometritis, polyps or tubercular lesions were evaluated. Secretory phase was further divided into early, mid and late based on its morphological pattern.

3. Result

A total of 237 endometrial biopsy or curettage samples of infertile women were studied. Age ranged from 18 years to 47 years with a mean age of 28.3 years. Majority of infertile women were between ages of 21-25 years. Majority of the patients, 196(82.7%) patients presented with primary infertility and 41 cases (17.3%) presented with secondary infertility. Overall mean age was 28.3 years.

Among the 196 primary infertility cases, the age group ranged from 18- 47 years, youngest being 18 years and eldest being 47 years. The maximum number of cases of primary infertility fell under the age group of 21-25 years, mean age being 23.2 years. Among the 41 cases of secondary infertility, the age group ranged from 22- 45 years. The maximum number of cases fell under the age group of 26-30 years. The mean age being 28.0 years. The p value was 0.0022 suggesting that there was significant difference in the age groups of primary and secondary infertile woman.

The most common morphological endometrial pattern in infertile women in our study was secretory phase with 85 (35.86 %) cases followed by proliferative phase with 73 (30.80%) cases and disordered proliferative phase with 42 (17.7%) cases. In primary infertility, the most common pattern was secretory phase with 76 cases (38.76 %) of which late secretory phase with 44 cases (22.44%) was in predominance. In secondary infertility, the most common pattern was proliferative phase with 17 cases (41.46 %) followed by secretory phase with 09 cases (21.95%).

3.1. Morphological endometrial patterns

1. Proliferative phase: There were totally 73 cases of proliferative phase out of which this pattern was seen in 56 cases of primary infertility and 17 of secondary infertility.
2. Disordered proliferative phase: Disordered proliferation were also seen in good number with 42 cases overall. 34 of which was in primary infertility and 8 cases of secondary infertility. In Disordered

proliferation, the growth of glands and stroma exceeds that of the normal proliferative phase. The endometrial glands are irregular in shape, width, and distribution; the lining epithelial cells are pseudostratified and form a dense row, their nuclei are large and rich in chromatin, and mitoses are frequent. The stroma is densely cellular and focally edematous.

3. Secretory phase: The secretory phase was divided into early, mid and late secretory phase. There were total of 12 early secretory pattern and 24 cases of mid secretory pattern. The late secretory phase was in predominance overall with 49 cases; 44 in primary infertility and 5 in secondary infertility.
4. Endometrial hyperplasia: There were 24 cases of hyperplasia in total. Out of which 23 cases were showing the simple cystic hyperplasia and a single case of complex hyperplasia. Complex hyperplasia was seen in the endometrial biopsy of secondary infertility.
5. Arias-Stella reaction: There was a single case of Arias-Stella reaction in a biopsy of secondary infertility.
6. Endometrial polyp: 5 cases of endometrial polyp were seen out of which 4 were reported in case of primary infertility and one was reported in case of secondary infertility.
7. Tuberculosis: 5 cases of tuberculous endometritis were seen all of which presented with primary infertility. None showed positivity on Ziehl Neelsen stain.
8. Endometrial carcinoma: Two cases of endometrial carcinoma were incidentally detected in endometrial biopsies of primary infertility. Both of which were endometrioid type of endometrial carcinoma.

4. Discussion

4.1. Proliferative phase

Proliferative phase suggests an anovulatory phase of the endometrial cycle. In our study this phase was the second most common endometrial pattern we encountered with 73 cases (30.8%). Our study was in coordination with that of S Sahamay (20.95%) et al and Manjunath(32.3%) et al. In contrast, the studies done by Ahmed et al and Manoj Kumar et al found the proliferative pattern to be in slight predominance.⁶⁻⁹

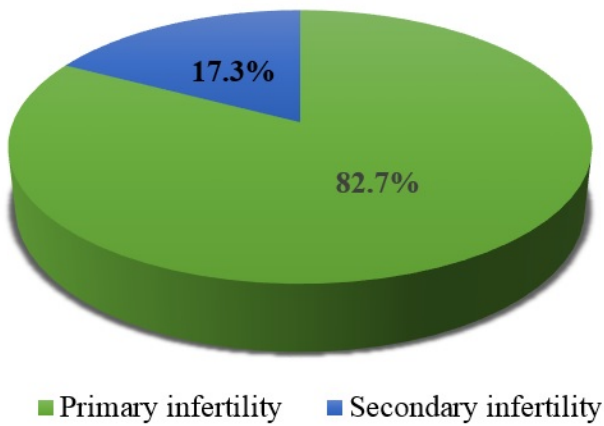
4.2. Secretory phase

Suggests that ovulation has taken place. It's divided into early, mid and late secretory phases.^{10,11} In our study secretory phase was most common endometrial pattern (35.86%) and in that late secretory phase was in predominance. Similar findings was seen in studies conducted by S Sahamay et al (37.8%) and Manjunath et al (56.7%). Though in the study conducted by Ahmed et

al., found the secretory pattern to be most common, in that late secretory phase was seen in most cases similar to that of ours.

4.3. Disordered proliferation

Disordered proliferation, which is considered a transitional form to simple (glandular cystic) hyperplasia was seen in 17.72% of cases in our study. Many researchers have not specifically mentioned about this group in their study of endometrial biopsies of infertile woman, but Sabeen Nasir, et al has made a similar observation to our study (17.5%).¹¹



Graph 1: Distribution of cases (total cases: 237)

4.4. Malignancy

In our study there were 2 cases (1.02%) of endometrial carcinoma both of which were endometrioid type of adenocarcinoma. Endometrial carcinoma is found usually in perimenopausal and postmenopausal age groups but can be rarely seen in reproductive age.¹⁰ In our study the two cases were diagnosed incidentally on endometrial biopsy, while investigating for primary infertility. There is scarcity of data on this in any other study other than S Sahmay et al, who in their study diagnosed 9 cases of endometrial malignancy (0.06%).⁸

4.5. Endometrial polyps

Endometrial polyps seen in 5 cases (2.10%) of endometrial biopsies of infertile women, four in primary infertility and one in a secondary infertility. Endometrial polyps can interfere with normal implantation and embryonic development by inducing local inflammatory changes and unresponsiveness of glands and stroma in polyps to progesterone stimulation.⁸ S Sahmay et al and Manjunath et al also observed endometrial polyps in endometrial biopsies of infertile women 0.23% and 1.1% respectively.

4.6. Endometrial hyperplasia

Simple cystic hyperplasia was seen in 23(9.70 %) cases in our study, of which 19(9.72%) seen in primary infertile women and 04(9.76%) in secondary infertile patients. Sabeen Nasir et al and Manoj Kumar et al observed lower incidence, 1.88% and 5.43% in their respective studies. Complex hyperplasia was seen in one case of secondary infertility (0.42%) whereas Sabeen Nasir et al found a higher incidence of 3.75% in their study. Endometrial hyperplasia in other studies ranges from 5.1% to 12.5%. We did not come across atypical hyperplasia in our study.

4.7. Tuberculous endometritis

There were 59(2%) cases of tuberculous endometritis. Tuberculosis is one of the major cause of granulomatous endometritis, especially in developing countries like India. Once the endometrium is affected, it suggests a more widespread disease affecting the genital tract; especially the fallopian tubes. This leads to infertility. Our study correlated with that of Manjunath et al (2.2%). Ahmed et al observed 0.51% cases and Manoj Kumar et al observed 3.26%. Rest of the studies the incidence of tuberculous endometritis ranged from 1% to 8%.¹⁴⁻¹⁶ All the cases were seen in females presenting with primary infertility and none in secondary infertility. This correlated with the study done by Kajal et al., with 3.5% cases.⁹

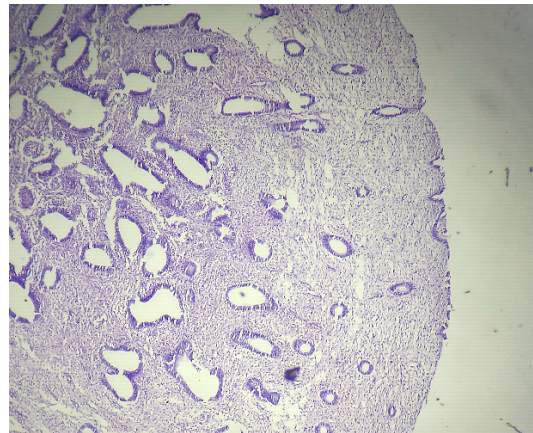


Fig. 1: Endometrial polyp, H and E, 10X

4.8. Arias-Stella reaction

In our study there was one case (2.44%) of Arias-Stella reaction in a female presenting with secondary infertility and it was associated with ectopic pregnancy. Arias-Stella reaction a mimic of carcinoma can indicate various conditions from pregnancy (intrauterine or ectopic) to external hormonal stimulation to trophoblastic disease. S Sahmay et al and Manoj Kumar et al in their studies observed 0.02% and 1.08% of Arias-Stella reaction

Table 1: Age distribution of cases (p value: 0.022)

Age groups (in years)	Primary infertility	Mean age	SD	Age groups (in years)	Secondary infertility	Mean Age	SD
≤20	09	19.2	0.78	≤20	00	00	00
21-25	77	23.2	1.36	21-25	07	23.7	1.16
26-30	59	28.3	1.27	26-30	15	28.0	1.46
31-35	29	33.1	1.22	31-35	10	33.0	1.18
36-40	16	37.7	1.36	36-40	08	37.8	1.63
41-45	05	42.2	1.47	41-45	01	45	-
46-50	01	47.0	-	46-50	00	00	-
Total	196	27.8	5.69	Total	41	30.8	5.37

Table 2: Overall endometrial patterns

Endometrial Patterns	Number	Percentage (%)
Secretory phase	85	35.86
Proliferative phase	73	30.80
Disordered proliferation	42	17.72
Simple cystic hyperplasia	23	9.70
Endometrial polyp	05	2.10
Tuberculous endometritis	05	2.10
Endometrial carcinoma	02	0.84
Complex hyperplasia	01	0.42
Arias stella reaction	01	0.42
Total	237	100

Table 3: Endometrial patterns in primary and secondary infertility

Endometrial Patterns	Primary infertility	Secondary infertility
Secretory phase	76 (38.76%)	09 (21.95%)
Early secretory	10(5.10%)	02(4.88%)
Mid-secretory	22(11.22%)	02(4.88%)
Late secretory	44(22.44%)	05(12.19%)
Proliferative phase	56(28.57%)	17(41.46%)
Disordered proliferation	34(17.34%)	08(19.51%)
Simple cystic hyperplasia	19(9.72%)	04(9.76%)
Endometrial polyp	04(2.04%)	01(2.44%)
Tuberculous Endometritis	05(2.55%)	-
Endometrial carcinoma	02(1.02%)	-
Complex hyperplasia	-	01(2.44%)
Arias stella reaction	-	01(2.44%)
Total	196(100%)	41(100%)

respectively which was more or less similar to our study.

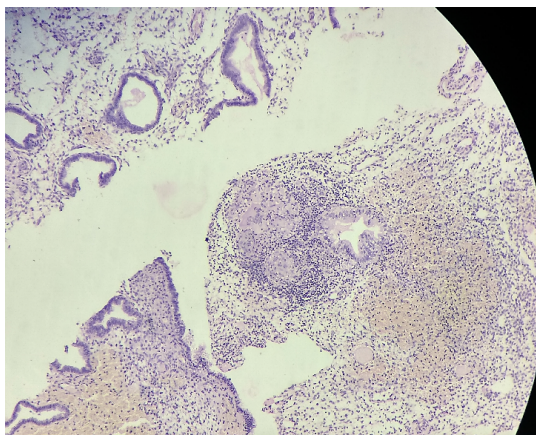
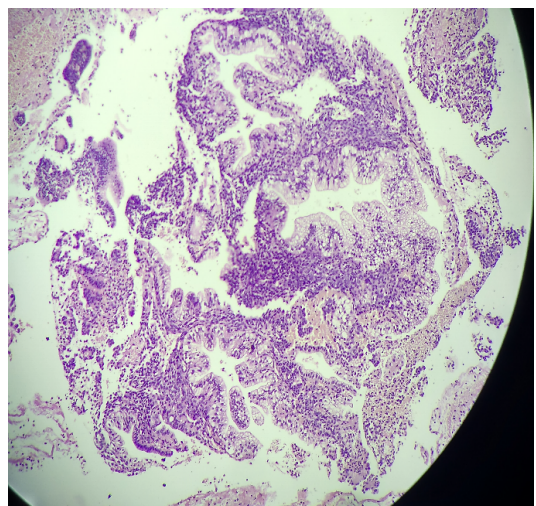
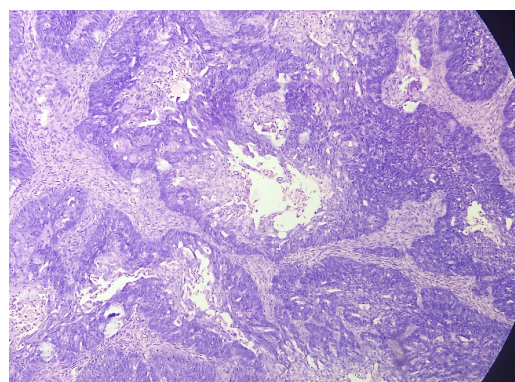
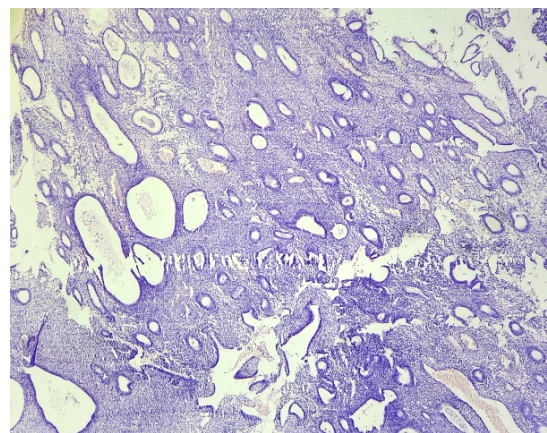
5. Conclusion

In endometrial biopsies sent for evaluation of primary and secondary infertility, histomorphological pattern analysis not only provides the cyclical phase but also throws light on other possible etiologies contributing to infertility like polyps, hyperplasia, endometritis, malignancy etc. Disordered proliferative phase was seen in significant number which can be considered as a separate entity

and should be evaluated for. In women presenting with unexplained infertility, tuberculous endometritis which still remains a major problem in India, has to be ruled out. Thus this study proposes that endometrial biopsies can be used as a primary diagnostic tool especially in cases of unexplained infertility that could be due to tuberculosis or polyps. Histopathological diagnosis can open the window to many such underlying etiologies and lead to appropriate management of them.

Table 4: Comparison of endometrial patterns among various studies

Endometrial Patterns	Ahmed M et al ⁶	Sabeen Nasir et al ¹²	S Sahmay et al ⁷	Manjunath et al ¹³	Manoj kumar et al ⁸	Present study
Proliferative phase	41.33	5.00	20.95	32.3	33.69	30.80
Secretory phase	40.30	63.75	37.58	56.7	32	35.86
Disordered proliferation	-	17.50	-	-	-	17.72
Simple cystic hyperplasia	-	1.88	-	5.5	5.43	9.70
Complex hyperplasia	-	3.75	-	-	-	0.42
Arias stella reaction	-	-	0.02	-	1.08	0.42
Endometrial polyp	-	-	0.23	1.1	-	0.84
Malignancy	-	-	0.06	-	-	0.84
Tuberculous Endometritis	0.51	-	-	2.2	3.26	2.10

**Fig. 2:** Tuberculous endometritis, H and E, 10X**Fig. 3:** Arias-Stella reaction, H and E, 10X**Fig. 4:** Endometrial carcinoma, H and E, 40X**Fig. 5:** Cystic glandular hyperplasia, H and E, 10X

6. Funding

None.

Conflicts of interest

None.

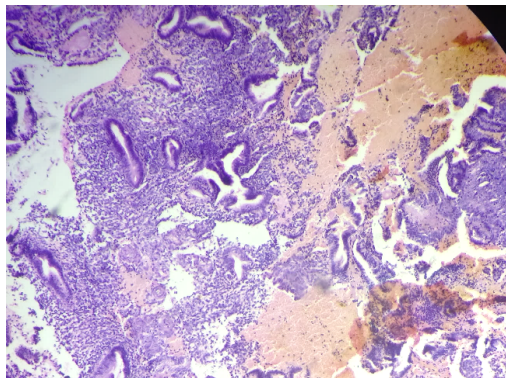


Fig. 6: Disordered proliferation, H and E, 10X

References

- World Health Organization. Reproductive health [online]. ;Available from: <http://www.who.int/reproductivehealth/topics/infertility/burden/en/index.html>.
- SG S. The endometrium: Pathologic principles and pitfalls. *Arch Pathol Lab Med.* 2007;131:372–82.
- Oru SJ. The differential diagnosis of female infertility. In: Principles and practice of endocrinology and metabolism Lippincott ; 1990,. p. 789–95.
- Female reproductive system-uterus. *Surgical Pathology Edinburgh: Mosby Elsevier.* 2011;p. 1477–1511.
- Nandedkar S, Patidar E, Gada D, Kamal M, Kavita M, Varma A. Histomorphological patterns of infertility. *J Obstet Gynecol India.* 2015;65(5):328–334.
- Ahmed M, Afroze N, Sabiha M. Histopathological Study of Endometrium in Infertility: Experience in a Tertiary Level Hospital. *BIRDEM Med J.* 2018;8(2):132–139.
- Sahmay S, Oral E, Saridogan E, Senturk L, Atasu T. Endometrial biopsy findings in infertility: Analysis of 12,949 cases. *Int J Fertil.* 1995;40(6):316–337.
- Kumar M, Dwivedy O, Mishra M, Sagar S. Histopathological evaluation of endometrial biopsy tissue of the patients suffering from primary infertility, attending in tertiary care hospital, at Muzaffarpur, Bihar. *J Med Clin Res.* 2019;7(1):182–188.
- Sharma V, Saxena V, Khatri SL. Histopathological Study of Endometrium in Cases of Infertility. *J Clin Exp Pathol.* 2016;6:272–272.
- Zawar MP, Deshpande NM, Gadgil PA, Mahanta AA. Histopathological study of endometrium in infertility. *Indian J Pathol Microbiol.* 2003;46(4):630–663.
- Kaur P, Kaur A, Suri AK, Sidhu H. A two year histological study of endometrial biopsies in a teaching hospital in Northern India. *Indian Journal of Pathology and Oncology.* 2016;3(3):508–527.
- Nasir S, Khan MM, Ahmad S, Ziaullah S, Alam S. Morphological spectrum of endometrial biopsies in infertile woman. *Gomal J Med Sci.* 2016;14:151–156.
- Girish CJ, Manjunath ML. Morphological patterns of endometrium in infertile woman-a prospective study. *Int J Appl Biol Pharm.* 2011;2(3):513–533.
- Dike EI, Ojiyi EC. Histopathological Characteristics of Endometrial Biopsies in the Igbos of Nigeria. *J Med Res.* 2017;3(4):187–90.
- Pereira N, Petrini A, Lekovich J, Elias R, Spandorfer S. Surgical management of endometrial polyps in infertile woman- A comprehensive review. *Surg R Prac.* 2015;p. 1–7.
- Punyashetty K. Tuberculous endometritis- a worrying recrudescence for infertility. *Int J Biol Med Res.* 2012;3(2):1708–1719.

Author biography

CR Preethi Associate Professor

BM Soumya Assistant Professor

Himani Gupta Post Graduate

Anvita Nilekani Post Graduate

KS Rajashekar Professor and HOD

Cite this article: Preethi CR, Soumya BM, Gupta H, Nilekani A, Rajashekar KS. A histomorphological pattern analysis in endometrial biopsies of infertile woman. *Arch Cytol Histopathol Res* 2019;4(3):187-192.