



## Original Research Article

## The study on morphology of placenta in gestational diabetes mellitus

Malathi B G<sup>1,\*</sup>, Ashok M<sup>2</sup><sup>1,2</sup>Dept. of Pathology, Mandya Institute of Medical Sciences, Mandya, Karnataka, India

## ARTICLE INFO

## Article history:

Received 06-08-2019

Accepted 06-09-2019

Available online 01-10-2019

## Keywords:

Gestational Diabetes Mellitus

Placenta

Histopathology

## ABSTRACT

**Introduction:** Gestational diabetes mellitus (GDM) refers to glucose intolerance with onset or first recognition during pregnancy. Its raising and varied prevalence in India makes it significant to study its effect on placenta for an effective euglycemic control.

**Aim:** To study the morphologic changes in placenta of GDM and its occurrence of onset in relation to maternal age and parity order.

**Materials and Methods:** The material for the present prospective study consisted of placenta from cases diagnosed as GDM received from the department of obstetrics and gynecology. The study was done for a period of one year from June 2014 to May 2015.

**Results:** A total of 80 placenta were analysed. 40 cases diagnosed as GDM were the Study group and remaining 40 was the control group the morphologic findings in GDM were found statistically significant. In the gross findings 37 (92.5%) GDM placenta weighed >500gm, the mean number of cotyledons was 21.08 and the mean size was 473.8cm<sup>3</sup>. The umbilical cord insertion was commonly eccentric. Various histopathological lesions identified were chorangiosis in 30(75%), increased syncytial knots in 29 (72.5%), villous edema in 28 (70%) cases, trophoblast basement membrane thickening in 24(60%), villous stromal fibrosis in 24(60%), fibrin deposition in 22(55%), and fibrinoid necrosis in 10(25%) cases. PAS stain for trophoblast basement membrane thickening and PTAH for fibrin deposition were positive. Majority of GDM cases were in the maternal age group of (25-30) years and were multiparous.

**Conclusion:** GDM causes significant morphologic changes consistent with dysmaturity and immaturity of the trophoblast tissue demanding an effective glycemic control.

© 2019 Published by Innovative Publication.

## 1. Introduction

Gestational diabetes mellitus (GDM) is glucose intolerance with first recognition during pregnancy.<sup>1</sup> 2 to 5% of Indian women are affected<sup>2,3</sup> with a prevalence rate of 10 to 14.3%.<sup>4</sup> This prevalence varied in respect to different geographical locations, ethnicity and level of glucose tolerance within the population. Kayal A and co-authors have reported a prevalence of 16.2% in urban and 9.9% in rural areas.<sup>2,4</sup> A random survey in various cities showed 3.8% in Kashmiri women, 12% in Bangalore, 15% in Trivandrum, 17.5% in Ludhiana, 18.8% in Erode and 21% in Alwaye.<sup>5</sup> The incidence is expected to raise by 20% indicating 1 every 5 pregnant mother's likely to have

GDM.<sup>4</sup> The risk factors are glucosuria, maternal age above 30years, obesity, family history of diabetes, GDM or glucose intolerance in previous pregnancy and a previous macrosomic baby.<sup>6</sup> GDM is associated with increased perinatal morbidity, macrosomia, neonatal hypoglycemia, hyperbilirubinaemia, shoulder dystocia and respiratory distress syndrome. The Gross and light morphologic changes in placenta are consistent with dysmaturity and immaturity of the trophoblast tissue.<sup>7-11</sup> This study was undertaken with the objective to study the morphologic changes in the placenta of GDM as documented in the literature and correlate them with maternal age and parity order.

\* Corresponding author.

E-mail address: [malathikush@gmail.com](mailto:malathikush@gmail.com) (Malathi B G).

## 2. Materials and Methods

A prospective study was conducted in the pathology department of a teaching hospital from June 2014 to May 2015 after obtaining permission from the Institutional Ethical Committee. The total sample size were 80 placenta of term pregnancy. 40 placenta from cases diagnosed as GDM formed the study group. Remaining 40 from normal pregnancy was the control group. The exclusion criteria included cases of Type 1 and 2 diabetes, GDM with hypertension, other toxemia s of pregnancy, chronic illness or a metabolic disorder in the mother. A writ ten informed consent was obtained. The clinical details and other investigation reports were noted from hospital case sheets. The clinicopathologic correlation for individual case was analysed. The morphologic findings were documented as per the standard proforma. The placental weight in grams and size in cms was noted. The membranes were examined for any colour change and or surface irregularity. Using swiss roll technique they were rolled with the amnion surface inward and formalin fixed The maternal surface was observed for the number of cotyledons and infarcts or any colour change. The fetal surface was looked for vascular pattern or other abnormal changes. O ne cm. serial sections were cut, formalin fixed and processed. The 5-micron thick sections were stained with haematoxylin and osin. Special stains periodic acid schiff (PAS) stain and phosphotungstic acid haematoxylin (PTAH) were done to demonstrate the trophoblast basement membrane thickening and fibrin deposition respectively. The umbilical cord length was measured in cms and observed for its position of insertion, number of vessels, knots or any other changes. It was cut 5cms away from sit e of insertion. Serially sectioned and formalin fixed The data was collected and tabulated in Microsoft excel sheet. The percentages were calculated for purpose of comparison.

## 3. Results

In the present study majority of placenta in GDM group 37(92.5%) weighed >500gms. and 02(5%) in control group with a p-value<0.001 (Table 1). The mean weight of the placenta was 629.4gms and 383.25gms. in both groups respectively.

**Table 1:** Placental weight in GDM and control group

Weight in grams	GDM (study)%	Normal (control)%	Total
>500	37(92.5)	02(5.0)	39(47.75)
≤500	03(7.5)	38(95.0)	41(51.25)
Total	40	40	80(100.0)

In the GDM group an increased mean diameter of placenta at 21.37cm. was significant with 13.51 cm. in the control group.

The mean number of cotyledons among GDM group was 21.08 and control group at 13.73. In one GDM case upto 28 cotyledons was noted. The p value < 0.001 (Table 2)

**Table 2:** Showing mean number of cotyledons in GDM and Control group

Mean number of cotyledons	
GDM(study)	21.08
Normal (control)	13.73

The eccentric insertion of umbilical cord was commonest, followed by central insertion and marginal insertion in GDM cases. Comparable finding was observed in control group (Table 3)

**Table 3:** Showing position of insertion of the umbilical cord in study groups

	Eccentric	Central	Marginal	Total
GDM (study)	25	13	2	40
Normal (control)	23	11	6	40
<b>Total</b>	<b>48</b>	<b>24</b>	<b>8</b>	<b>80</b>

Histomorphological study showed chorangiosis as the commonest lesion in GDM placenta 30 (75%) and in the control

group 01 (2.5%). Increased syncytial knots was common in 29 (72.5%) GDM cases and 1 (2.5%) case in the control group. Villous edema was noted in 28 (70%) GDM and 4 (10%) in control cases. The consistent finding of trophoblast basement membrane thickening (BMT) among GDM group was identified in 24 (60%) and in control group in 2 (5%) cases. PAS stain showed positivity for BMT. Villous stromal fibrosis was observed among 24 (60%) of GDM and 01 (2.5%) in control cases. Fibrin deposition was frequently seen in 22(55%) and 2(5%) in GDM and normal groups respectively. PTAH showed positivity in these cases. Fibrinoid necrosis noted in 10(25%) in GDM and 01(2.5%) in the study group. Increased numbers of Hofbauer cell in the intravillous stroma was found in 2 cases of GDM placenta only. (Table 4) depicting the observed findings.

Majority of GDM 15(37.5%) cases were diagnosed in the maternal age group (25-29) years and few 5(12.5%) cases in >3 5 years (Table 5).

## 4. Discussion

GDM is associated with significant histomorphologic variations in the placenta. In the present study the mean weight of placenta in GDM group was 629.4gms while in control group was 383.3gms and found to be significant. This observation was comparable with various studies (Table 6).

**Table 4:** Histomorphologic findings in present study

Histomorphologic findings	GDM ( Study group)%	Normal (Control group)%	p value
Chorangiomas	30(75)	01(2.5)	<0.001
Syncytial knots	29(72.5)	01(2.5)	<0.001
Villous edema	28(70)	04(10)	<0.001
Basement membrane thickening.	24(60)	02(5)	<0.001
Villous stromal fibrosis	24(60)	01(2.5)	<0.001
Fibrin deposition(intra & intervillous)	22(55)	02(5)	<0.01
Fibrinoid necrosis	10(25)	01(2.5)	<0.01
Increased numbers Hofbauer cell in the stroma	02	nil	

**Table 5:** Age group distribution of GDM and control groups

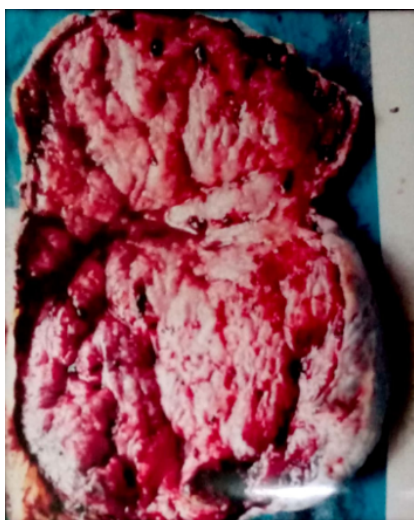Age group in years	GDM (%)(study)	Normal(%)(control)	Total
20-24	11(27.5)	29(72.5)	40(50)
25-29	15(37.5)	10(25.5)	25(31.3)
30-34	09(22.5)	01(2.5)	10(12.5)
>= 35	05(12.5)	00(0.0)	05(6.2)
Total	40	40	80

p-value <0.001

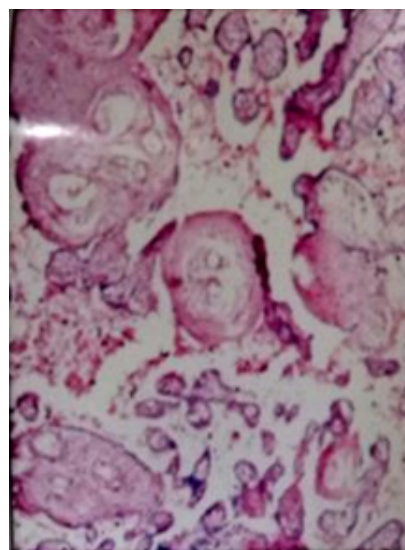
**Table 6:** Showing mean weight of placenta in GDM and Control group in various studies

S No.	Studies	Weight of placenta in gms	
		GDM	Control
1	Present study	629.4	383.3
2	Mohammad Ashfaq et. al(2005) <sup>12</sup>	656	237
3	Lal Baksh Khaskhelli et. al(2013) <sup>8</sup>	967.5	499.6
4	Mohaammad Ali Qureshi et. al(2014) <sup>13</sup>	1478.8	557.8

(p<0.001).



**Fig. 1:** Gross photograph showing maternal surface with increased number of cotyledons



**Fig. 2:** Photomicrograph showing chorangiomas (H&E stain, 10x).

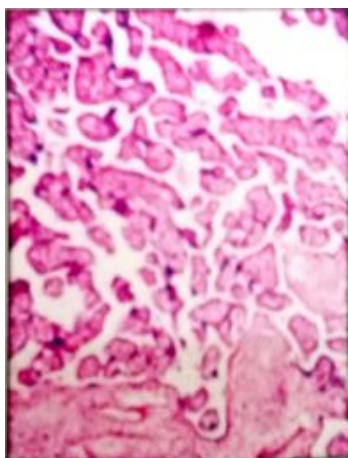
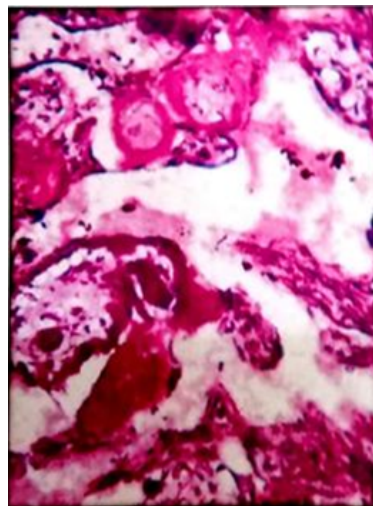
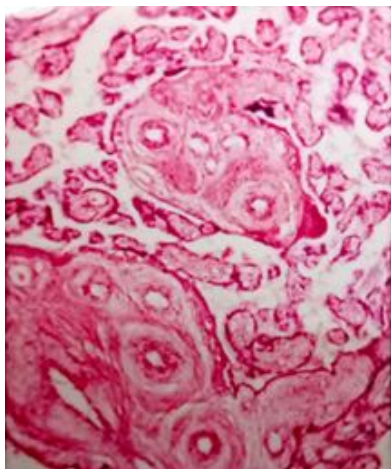
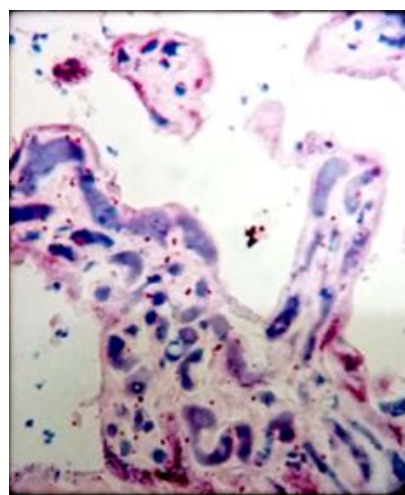
The mean number of cotyledons were increased to 21.07 in GDM cases. In one case 28 cotyledons were counted. Similar observations were reported by other authors as shown in (Table 7).

The mean diameter of placenta was calculated to be 21.37cms and 13.51cms in GDM and control group respectively. Comparative result was reported by Muhammad Ashfaq and authors with a mean diameter

**Table 7:** Comparison of mean number of cotyledons among various studies

S No.	Study	Mean number of cotyledons	
		Study	Control
1	Present study	21.07	13.72
2	Lal BhakshKhaskhelli et.al (2013) <sup>8</sup>	24.46	16.13
3	Sadafpervez Hussainet.al (2013) <sup>14</sup>	22.56	17.88
4	Pankaj Saini et.al (2015) <sup>15</sup>	18.38	16.93

(p&lt;0.001).

**Fig. 3:** Photomicrograph showing increased syncytial knots (H&E stain 10x).**Fig. 5:** Photomicrograph showing thickening of trophoblast basement membrane (PAS stain 10x)**Fig. 4:** Photomicrograph showing stromal fibrosis (H &E stain 10x).**Fig. 6:** Photomicrograph showing intravillous fibrin deposits (PTAH Stain 10x).

of 18.95cms and 14.26cms in GDM and control group respectively.<sup>14</sup> Muhammad Ali Qureshi and co-authors noted 34.5cms. mean diameter in GDM, and 21.1 cms in control group.<sup>13</sup>

Analysis with onset of GDM with reference to maternal age showed majority of cases in (25-29) (37.5%), followed by in (20-24) (30%) and (30-34) (20%) age group in yrs. respectively. The mean age was 27.43 yrs. Pankaj

**Table 8:** Comparison of various histomorphologic features among various studies

S. no	Study (year)	GDM cases in numbers	Histopathological findings observed
1	Memon S (2015) <sup>16</sup>	50	Chorangiosis, fibrinoid necrosis, villous immaturity
2	Madazli et al (2008) <sup>17</sup>	22	Chorangiosis, villous immaturity and ischaemia
3	Verma & co authors (2010) <sup>9</sup>	20	Syncytial knots, fibrinoid necrosis, villous fibrosis, & edema & capillary proliferation
4	Amal T & authors (2012) <sup>8</sup>	12	Increased syncytial knots, thickening of basement membrane & partial shedding of trophoblastic villi, increased number of Hofbauer cells & fibrinoid necrosis
5	Soma Saha & co authors (2013) <sup>15</sup>	In 130 randomly selected cases	Villous edema, fibrin deposition, calcification & congestion of blood vessels
6	Lavinia Gheorman & co-authors (2011) <sup>11</sup>	2	Basement membrane thickening, villous immaturity & edema, chorangiosis, intra & extravillous fibrinoid & deposit of glycogen.
7.	Present study (2015)	40	Chorangiosis, increased syncytial knots, villous edema, basement membrane thickening, villous stromal fibrosis, intra and inter villous fibrin deposition, fibrinoid necrosis, increased number of Hofbauer cells.

Saini and co-authors observed maximum cases of GDM in the age group (25-29) yrs. (47.5%).<sup>15</sup> An incidence of occurrence of GDM in 67.5% among multiparous and 32.% in primiparous mother's respectively was seen. Author Vijayasheela observed a comparable incidence of 72% in multiparous and 28% in primiparous women.<sup>16</sup>

In our study the commonest insertion of umbilical cord was eccentric (25 cases) followed by central (13 cases) and marginal in 2 cases with similar correlation in the control group. Soma Saha and co-authors also noted that cord insertion was commonly eccentric, then central and marginal.<sup>17</sup>

In the present study histomorphology revealed increased chorangiosis as the commonest finding in upto 30 (75%) GDM cases but only in one (2.5%) in the control group. Memon S studied 50 placenta of GDM and found significant association with chorangiosis.<sup>18</sup> Madazli and co-authors study on 22 GDM cases found chorangiosis along with villous immaturity and ischemia.<sup>19</sup>

We noted increased syncytial knots in upto 29 (72.5%) GDM group and 1 (2.5%) in the control group. Verma and co-authors in 20 GDM cases observed syncytial knots, fibrinoid necrosis, villous edema, villous fibrosis and capillary proliferation.<sup>8</sup> Amal T and authors observed increased syncytial knots in 12 cases of GDM.<sup>20</sup>

The villous edema was a consistent significant finding present in 28 (70%) GDM group and 4 (10%) in control group. In Soma Saha and co-authors study of total 130 placenta, the GDM cases showed significant changes like villous edema, fibrin deposition, calcification and congestion of blood vessels.<sup>17</sup>

We noticed a significant villous basement membrane thickening in 24 (60%) GDM and 2 (5%) in normal

placenta. PAS stain showed positivity. Lavinia Gheorman and co-authors in their study on two cases of GDM noted the presence of basement membrane thickening, villous immaturity, villous edema, chorangiosis, intra and extravillous fibrinoid and a deposit of glycogen.<sup>11</sup>

In the present study villous stromal fibrosis in 24 (60%) in GDM and 1 (2.5%) in control was noted. The p-value was significant. Verma and co-authors studied 20 GDM cases and observed significant varying lesions like villous fibrosis, syncytial knots, fibrinoid necrosis, villous edema and capillary proliferation.<sup>9</sup>

Intra and intervillous fibrin deposition in 22 (55%) of our GDM group and in 2 (5%) cases in control group and was found to be significant. PTAH showed positivity for both intravillous and intervillous fibrin deposition. Lavinia Gheorman and other authors noted intra and extravillous fibrin deposition, villous immaturity, villous edema, presence of basement membrane thickening, chorangiosis, and deposit of glycogen.<sup>10</sup>

Fibrinoid necrosis was seen in our 10 (25%) GDM placenta and 01 (2.5%) in control placenta. Authors Amal T and others also noted fibrinoid necrosis in 12 GDM cases.<sup>20</sup>

We observed increased number of Hofbauer cells in the intravillous stroma in 2 placenta from GDM. Amal T and co-authors have reported frequent increased presence of Hofbauer cells in 12 GDM cases.<sup>20</sup>

## 5. Conclusion

In our study of placenta in 40 cases diagnosed as GDM showed a significant increase in incidence of morphologic changes in comparison to term placenta from normal pregnancy. The observed gross changes in GDM

were increased weight in gms., diameter in cms., and number of cotyledons. Light microscopic changes were chorangiomas, increased syncytial knots, villous fibrosis, intra and intervillous fibrin deposition, basement membrane thickening, fibrinoid necrosis and villous edema. The above findings correlated with various studies by other authors. So an aim towards an effective euglycemic control would decrease the associated perinatal morbidity.

## 6. Source of funding

None.

## 7. Conflict of interest

None declared.

## 8. Acknowledgement

Regards to Dr. Mythrei M U & Dr Suma H V, postgraduate students of Pathology, MIMS, Mandya for the kind support.

## References

- Divakar H, Manyonda I. Battling with rising prevalence of gestational diabetes mellitus screening and diagnosis. *Int J Infertility Fetal Med*. 2011;2(3):96–100.
- Anjana RM, Mohan V. Gestational diabetes- an update from India ; 2013.
- Kumar V, Abbas AK, Fausto N, Aster JC. The endocrine system. Pathologic basis of diseases. Pennsylvania: Pennsylvania: Elsevier Inc ; 2011. p. 1137–1137. Maitra A. the endocrine system.
- Mishra CK, Kumar R, Bhushan H, Baswal D, Malhotra M, et al.. National Guidelines for Diagnosis & Management of Gestational Diabetes Mellitus. Maternal Health Division, Ministry of Health and Family Welfare. Government of India ; 2014.
- Seshiah V, Balaji V, Balaji MS, Sanjeevi CB, Green A. Gestational diabetes mellitus in India. *J Assoc Physicians India*. 2004;52:707–711.
- Kaaja R, Ronnema T. Gestational Diabetes: Pathogenesis and Consequences to Mother and Offspring. *Rev Diabet Stud*. 2008;5(4):194–202.
- Khaskhelli LB, Memon S, Goswami P, Bano S. Change in normal morphology of placenta and Its possible effects on fetal outcome in diabetic mothers as compared to non-diabetic mothers. *Jamshoro Liaquat Univ MediHealth Sci*. 2013;12(01):49–54.
- Verma R, Mishra S, Kaul JM. Cellular changes in the placenta in pregnancies complicated with diabetes. *Int J Morphol*. 2010;28(1):259–64.
- Daskalakis G, Marinopoulos S, Krielesi V, Papantoniou N, Mesogitis S. Placental pathology in women with gestational diabetes. *Acta Obstet Gynecol Scand*. 2008;87(4):403–410.
- Gheorman L, Plesea IE, Gheorman V. Histopathological considerations of placental pregnancy with diabetes. *Romanian Journal of morphology and embryology*. 2012;53(2):329–365.
- Rudge M, Lima CP, Damascen DC, Sinzato YK, Napoli G, Rudge C. histopathological placental lesions in mild gestational hyperglycemic and diabetic women. *Diabetic Metab Syndr*. 2011;3(19):1–6.
- Ashfaq M, Janjua ZM, Channa MA. Effect of gestational diabetes and maternal hypertension on gross morphology of placenta. *J Ayub Med Colle*. 2005;17(1):44–47.
- Qureshi MA, Bhurgri GR, Yousfani GM. Morphological and histological changes in placenta of hypertensive and gestational diabetic women. *Med Forum Mon*. 2014;25(10):10–14.
- Hussain SP, Islam ZU, Joy R, Sivakumar V. A prospective Study on the effect of Gestational Diabetes mellitus in India. *Pak J Med Health Sci*. 2004;7(4):707–718. Journal of Association of Physicians of India.
- Saini P, Pankaj JP, Jain A, Agarwal GC. Effect of gestational diabetes mellitus on gross morphology of placenta: A comparative study. *Int J Anat Res*. 2015;3(1):889–894.
- Sheela VP, Padmaja R, Vijayalakshmi. Maternal and perinatal outcomes in GDM: A study. *J Evidence Based Med Healthcare*. 2015;2(11):1593–1594.
- Saha S, Biswas S, Mitra D, Adhikari A, Saha C. Histologic. Histologic and morphometric study of human placenta in gestational diabetes mellitus ; 2014.
- Memon S, Goswami P, Lata H. Gross and Histological Alteration in the Placenta of Mothers suffering from Gestational Diabetes. *J Liaquat Univ Med Health Sci*. 2015;14(1):16–20.
- Madazli R, Tuten A, Calay Z, Uzun H, Uludag S, Ocak V. The Incidence of Placental Abnormalities, Maternal and Cord Plasma Malondialdehyde and Vascular Endothelial Growth Factor Levels in Women with Gestational Diabetes Mellitus and Nondiabetic Controls. *Gynaecol Obstet Invest*. 2008;65(4).
- Amal T, Elghaita A, Hoda A, Aziz A, Mahmoud FY. Histological and Immunohistochemical changes in placental chorionic villi of patients with poorly controlled gestational diabetes. *Egypt J Histol*. 2012;35(2).

## Author biography

**Malathi B G** Associate Professor

**Ashok M** Post Graduate Student

**Cite this article:** Malathi B G , Ashok M . The study on morphology of placenta in gestational diabetes mellitus. *Arch Cytol Histopathol Res* 2019;4(3):253-258.