



Original Research Article

Study of cytological pattern of pap smears and detection of cervical cancers in Gujarat, India

Darshana Patel¹, Nisarg Savjiani^{1,*}¹Dept. of Pathology, Parul Institute of Medical Science & Research, Vadodara, Gujarat, India

ARTICLE INFO

Article history:

Received 25-11-2019

Accepted 29-11-2019

Available online 07-01-2020

Keywords:

Cervical cancer

pap smear

cytology

ABSTRACT

Introduction: Cervical cancer is one of the leading causes of morbidity and mortality. It can be preventable and diagnosed early with adequate and repetitive cytological screening by pap test. The conventional cervical cytological screening is the most common technique used throughout the world.

Objective: To characterize the age and pattern of Pap smear abnormalities in a population of Gujarat, India.

Materials and Methods: A retrospective study was conducted at tertiary care hospital of Gujarat India. All previously collected pap smear from 2011 -2014 was evaluated for cytological pattern and during this duration total 1100 pap smear was evaluated.

Results: The mean age of patients with abnormal smears was 37.5 years. The mean parity was 4.34.

There were 46 (4.18%) unsatisfactory smears and 1054(95.82%) adequate smears. Atypical squamous cell of undetermined significance(ASCUS), low grade squamous intraepithelial lesion (LSIL), and high grade squamous intraepithelial lesion (HSIL) were reported in 69 (6.54%), 111(10.53%), and 55 (5.21%) women respectively. Atypical glandular cell and squamous cell carcinoma were reported in 10 (0.94%) and 5 (0.47%) respectively

Conclusion: This study emphasized the importance of Pap smears screening for early detection of premalignant and malignant lesions of cervix. Pap smear testing is a very useful, simple, economical and safe tool to detect preinvasive cervical epithelial lesions. Hence, on a routine basis, every woman above the age of 30 must be subjected to Pap smear and this must be continued even in post-menopausal period as most of patients with epithelial abnormalities in our study falls in this group.

© 2019 Published by Innovative Publication. This is an open access article under the CC BY-NC-ND license (<https://creativecommons.org/licenses/by/4.0/>)

1. Introduction

Cervical cancer occurs when the cells of the cervix grow abnormally and invade other tissues and organs of the body. When it is invasive, this cancer affects the deeper tissues of the cervix and may have spread to other parts of the body (metastasis), most notably the lungs, liver, bladder, vagina, and rectum.^{1,2}

Cervical cancer is the most common cancer related cause of death among women in developing countries. Current data from the National Cancer Registry Program indicate that the most common cancer in women in India is the breast and the cervix.^{3,4} Cancer cervix is the Fourth most

common cancer, after breast and colorectal cancer and the fourth leading cause of cancer death in women worldwide.⁵

Most women diagnosed with precancerous changes in the cervix are in their 20s and 30s, but the average age of women when they are diagnosed with cervical cancer is the mid 50s.⁶ This difference in the age at which precancerous changes are most frequently diagnosed and the age at which cancer is diagnosed highlights the slow progression of this disease and the reason why it can be prevented if adequate steps are taken.

This has been possible due to its early detection by screening for cervical cancer is one of the few cancers that can be easily detected at premalignancy phase.^{7,8} Exfoliative cervicovaginal cytology, (Pap smear) has been regarded as the gold standard for cervical cancer screening

* Corresponding author.

E-mail address: nisargsavjiani11111@gmail.com (N. Savjiani).

programs.

2. Materials and Methods

This retrospective study was conducted by the Department of Pathology, Government Medical College, Bhavnagar and attached hospital, Gujarat, India from 2011 to 2014.

After taking a history (regarding parity, menstrual history, and duration of married life) and recording the findings (healthy or unhealthy) of per vaginal examination of the patients, the Pap smear was collected with the help of a Ayer spatula and cytobrush under aseptic method.

The smear was immediately fixed in alcohol for 30 minutes.

Then Pap staining was done followed by light microscopy and slide interpretation.

A total of 1100 slides were examined.

Specimen adequacy as well as reporting was assessed according to the revised 2001 Bethesda system. Unsatisfactory smears were repeated.

All patients with epithelial cell abnormalities were referred for colposcopy according to the standard procedure and recommendations.

2.1. Exclusion criteria

Previously diagnosed cases with any kind of cervical lesions benign, premalignant, or malignant lesions were excluded from the study.

3. Results

A total of 1100 cases of cervical Pap smears were retrieved from the archives of the laboratory during the study period.

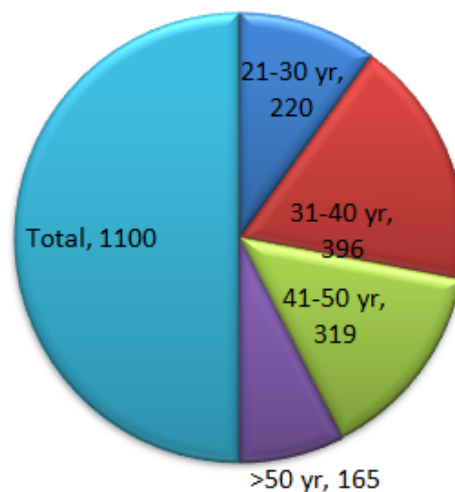
All collected pap smears were classified in different age group (Table 1). Majority of pap smear of age group 31-40 year (n=396, 36%) followed by 41-50 year (n=319, 29%).

Table 1: Age wise distribution of participants

Age Group(year)	Number(n)	Percentage(%)
21-30	220	20
31-40	396	36
41-50	319	29
>50	165	15
Total	1100	100

Table 2: Number of parity among the patients with abnormal Pap smear

Parity	Number of patients with abnormal smear(n=603)	Percentage (%)
0-2	111	18.50
3-4	396	36.40
≥5	319	45.27



Graph 1: Graphical representation of age group of participants

The mean parity was 4.34 and the parity of a majority (45.32%) of patients was ≥ 5 (Table 2)

Table 3: Common findings in all the Pap smears

Different cytological findings	Number	percentage
Unsatisfactory smears	46	4.18
NILM	515	46.81
Abnormal smear	603	54.81
Total	1100	100

(NILM: Negative for intraepithelial malignancy)

The findings of pap smears were broadly classified into two groups such as unsatisfactory smears and satisfactory/adequate smears. There were 46 (4.18%) unsatisfactory smears and 1054 (95.82%) adequate smears.

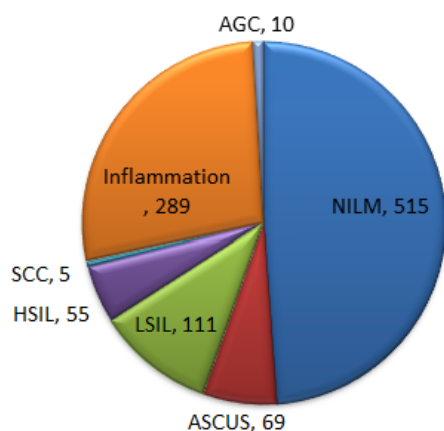
The unsatisfactory or inadequate smears were due to either paucity of squamous cells, excess blood, or heavy inflammatory obscuring squamous cells.

Table 4: Number and percentage of the specific findings in the abnormal Pap smears

	No of pap smear(n)	Percentage(%)
NILM	515	46.81
ASCUS	69	6.54
LSIL	111	10.53
HSIL	55	5.21
SCC	5	0.47
Inflammation	289	27.41
AGC	10	0.94
Total	1054	100

NILM: Negative for intraepithelial malignancy, AGC: Atypical glandular cell carcinoma, LSIL: Low squamous

intraepithelial lesion, HSIL: High squamous intraepithelial lesion, SCC: Squamous cell Carcinoma, ASCUS: Atypical squamous cells of undetermined significance.



Graph 2: Showing graphical presentation of abnormal smear

Inflammatory Pap smear results increased across all age groups (27.41%).

Atypical squamous cell of undetermined significance (ASCUS), low grade squamous intraepithelial lesion (LSIL), and high grade squamous intraepithelial lesion (HSIL) were reported in 69 (6.54%), 111 (10.53%), and 55 (5.21%) women respectively. Atypical glandular cell and squamous cell carcinoma were reported in 10 (0.94%) and 5 (0.47%) respectively.

4. Discussion

Carcinoma of the uterine cervix is a major health problem faced by the Indian women, and every year, approximately 120,000 women develop this disease.⁹ India accounts for 15.2 per cent of the total cervical cancer deaths in the world.¹ Although the incidence of carcinoma cervix has declined in the urban population, in the rural areas it continues to be highly prevalent. The usual 10-20 years of natural history of progression from mild dysplasia to carcinoma cervix makes this cancer as relatively early preventable disease and provides the rationale for screening.¹⁰

In our study, the mean age of patients with abnormal smears was 37.5 years. Similar finding was detected by other studies.^{11,12} Vaginal discharge was the most common presenting complaint in our study. Other studies also reported similar findings. In a study conducted by Herbert and Smith (1999) cervical premalignant lesions peak in the late 20s. Human papillomavirus (HPV) the causative organism of cervical cancer is mainly sexually transmitted, it follows that peak incidence of HPV infection like any other sexually transmitted infection will be shortly after commencement of sexual intercourse and CIN the precursor

lesions of cervical cancer also peaks about a decade after the peak incidence of HPV infection and a decade earlier than invasive cervical cancer. That is one of the reasons why screening for cervical cancer is recommended to start in the early 20s. This is the age that screening is most likely to be successful in preventing cervical cancer. Screening beyond this age will detect more advanced lesions or invasive cancer.¹³

We have studied a total of 1100 smears during the duration between June 2011 to 2014; out of these, 46 smears were inadequate or unsatisfactory due to blood/mucus. Proportion of inadequate samples were 4.18% in our set up while two separate studies done by Rawat K et al (16.1%) and Gupta S et al reports similar findings.^{14,15} The unsatisfactory rate is an important quality assurance indicator in cervical cytology as it identifies women who are being inadequately screened.

Sampling technique skills, storage or transportation could be the reason for higher inadequate smear proportion. Regular training of healthcare personnel about proper preparation of pap smears and feedback is necessary, in our setup.

In our study we found that Inflammatory Pap smear results increased across all age groups (27.41%). Atypical squamous cell of undetermined significance (ASCUS) low grade squamous intraepithelial lesion (LSIL), and high grade squamous intraepithelial lesion (HSIL) were reported in 69 (6.54%), 111 (10.53%), and 55 (5.21%) women respectively. Atypical glandular cell and squamous cell carcinoma were reported in 10 (0.94%) and 5 (0.47%) respectively. Similar finding was obtained in study done by Bamanikar *et al* 1995.¹⁶

5. Conclusion

This study emphasized the importance of Pap smears screening for early detection of premalignant and malignant lesions of cervix. Pap smear testing is a very useful, simple, economical and safe tool to detect preinvasive cervical epithelial lesions. Hence on a routine basis, every woman above the age of 30 must be subjected to Pap smear and this must be continued even in post-menopausal period as most of patients with epithelial abnormalities in our study falls in this group.

6. Acknowledgements

We acknowledge the whole department of Pathology and Gynaecology of our institute.

7. Source of funding

None.

8. Conflict of interest

None

References

1. Parkin M, Bray F, Ferlay J, Pisani P. Global Cancer Statistics. *CA Cancer J Clin.* 2005;p. 74–108.
2. Valdespino VM, Valdespino VE. Cervical cancer screening: State of the art. *Curr Opin Obstet Gynecol.* 2006;18:35–40.
3. International Agency for Research on Cancer and World Health Organization [Internet]. GLOBOCAN 2012: Estimated cancer Incidence, mortality and prevalence worldwide in 2012 .; p. 2012. Internet.
4. Denny L. The prevention of cervical cancer in developing countries. *BJOG.* 2005;112:1204–1212.
5. A J, Center MM, Desantis C, Ward EM. Global patterns of cancer incidence and mortality rates and trends. *Cancer Epidemiol Biomarkers Prev.* 2010;19:1893–1907.
6. . Available from: <https://www.who.int/cancer/prevention/diagnosis-screening/cervical-cancer/en>.
7. Papanicolaou GN. A new procedure for staining vaginal smears. *Sci.* 1942;95:438–439.
8. Haider G, Parveen Z, Anjum F, Munir A. Pap smear, an important screening tool to detect precancerous stage of carcinoma of cervix. *JAMC.* 2013;25:26–27.
9. Tailor H, Patel RD, Patel PR, Bhagat VM. Study of cervical Pap smears in a tertiary care hospital of South Gujarat, India. *Int J Res Med Sci.* 2016;4:286–288.
10. Patel MM, Pandya AN, Modi J. Cervical pap smear study and its utility in cancer screening, to specify the strategy for cervical cancer control. *Natl J Community Med.* 2011;2(1).
11. Jonathan SB. Berek and Novak's Gynaecology. — 14th ed. Philadelphia: Lippincott William Wilkins ; 2006,.
12. Roland KB, Soman A, Benard VB, Saraiya M. Human Papilloma virus and papanicolaou tests screening interval recommendations in the United States. *Am J Obstet Gynecol.* 2011;205(5):447–448.
13. Saha D, Ghosh S, Nath S, Islam H. Utility of Pap smear screening for prevention of cervical cancer- A 3yrs study from rural Tripura - Anortheastern state of India. *Int J Med Dent Sci.* 2017;6(2):1456–1461.
14. Herbert A, Smith JA. Cervical intraepithelial neoplasia grade III (CIN III) and invasive cervical carcinoma: The yawning gap revisited and the treatment of risk. *Cytopathology.* 1999;10:161–170.
15. Rawat K. A study of cytological pattern of cervical papanicolaou smears in western Rajasthan. *India Int J Reprod Contracept Obstet Gynecol.* 2016;5(9):3186–3190.
16. Bamanikar SA, Baravkar DS, Chandanwale SS, Dapkekar P. Study of Cervical Pap smears in a Tertiary Hospital. *Indian Med Gazette.* 2014;p. 250–254.

Author biography

Darshana Patel Assistant Professor

Nisarg Savjiani Associate Professor

Cite this article: Patel D, Savjiani N. Study of cytological pattern of pap smears and detection of cervical cancers in Gujarat, India. *Arch Cytol Histopathol Res* 2019;4(4):293-296.