



## Case Report

# Kikuchi disease masquerading under a deviant presentation

Abilash Sasidharannair Chandrakumari<sup>1,\*</sup>, Hemalatha AL<sup>2</sup>

<sup>1</sup>Dept. of Pathology, Sri Sathya Sai Medical College & Research Institute, Nellikuppam, Tamil Nadu, India

<sup>2</sup>Dept. of Pathology, DM Wayanad Institute of Medical Sciences, Meppadi, Kerala, India



### ARTICLE INFO

#### Article history:

Received 24-11-2019

Accepted 05-12-2019

Available online 07-01-2020

#### Keywords:

Kikuchi disease

Histiocytic necrotizing lymphadenitis

Benign

Selflimiting

### ABSTRACT

Kikuchi disease also known as histiocytic necrotizing lymphadenitis, is a benign and self-limited disease mainly affecting women.

Clinically and histologically, the disease is mistaken for lymphoma or systemic lupus erythematosus. It merits recognition and importance since it almost always runs a benign course and resolves in several weeks to months. Complications are rare and the prognosis is excellent. We report a case of Kikuchi Disease in a male patient with a deviant presentation.

© 2019 Published by Innovative Publication. This is an open access article under the CC BY-NC-ND license (<https://creativecommons.org/licenses/by/4.0/>)

## 1. Introduction

Kikuchi disease was first described by Dr Masahiro Kikuchi in 1972.<sup>1</sup> Fujimoto and colleagues independently described kikuchi disease in the same year.<sup>2</sup> Clinically and histologically, the disease is mistaken for lymphoma or Systemic Lupus Erythematosus.<sup>3</sup> It occurs commonly in young women.<sup>4</sup> It most commonly presents with localized lymphadenopathy in the cervical region.<sup>5</sup> It is associated with fever and leukopenia upto 50% of cases.

Etiology of kikuchi disease is unknown. Certain causative organisms like Epstein-Barr virus (EBV), Human T-cell Lymphotropic virus type I (HTLV-1), Human Herpes Virus 6 (HHV-6), Parvovirus B19, Cytomegalovirus (CMV), Brucella, Yersinia enterocolitica and parainfluenza virus have been implicated.<sup>6</sup>

This case is presented in view of its deviant presentation with clinical suspicion of multiple pyogenic abscess.

## 2. Case Summary

A 37 year old male patient presented with generalized lymphadenopathy of one month's duration. The patient initially developed a painless swelling over left infraclavicular region and subsequently developed another swelling over right inguinal region, which was associated with fever and pain. He also complained of decreased appetite for two weeks. Patient was a known case of type 2 diabetes mellitus under treatment since two years.

### 2.1. Ultrasonography

Revealed left infraclavicular, bilateral axillary and right inguinal lymphadenopathy associated with necrosis. A provisional clinical diagnosis of multiple pyogenic abscess was offered.

### 2.2. Fine Needle Aspiration

Of left infraclavicular and right inguinal lymph nodes yielded pus-like material. Smears studied were scantily cellular and showed degenerating neutrophils against a background of dense karyorrhectic debris. A cytological diagnosis of Acute Suppurative inflammation was arrived

\* Corresponding author.

E-mail address: [abey4aris@gmail.com](mailto:abey4aris@gmail.com) (A. Sasidharannair Chandrakumari).

at (Figure 1). Ziehl – Neelson stain for Acid Fast bacillus was negative Culture of pus yielded Methicillin Resistant Staphylococcus aureus. The left infraclavicular and right inguinal lymph nodes were excised and submitted for histopathological examination.

### 2.3. Gross examination findings

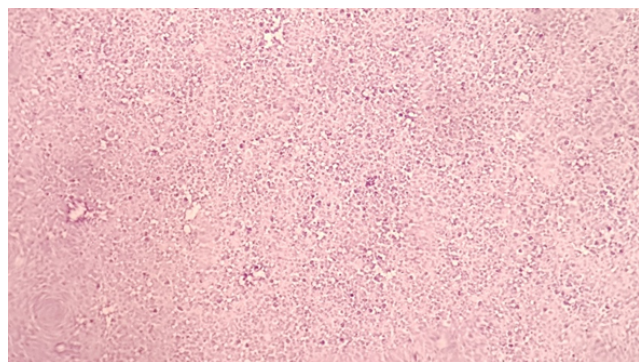
Received three lymph nodes, largest measuring 3×2×1.5 cm. Cut section was grey white.

### 2.4. Microscopic findings

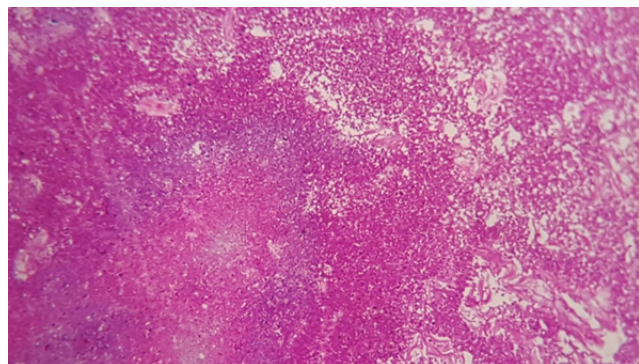
Revealed effacement of nodal architecture and replacement by abundant karyorrhectic debris admixed with mononuclear cells showing the predominance of histiocytes and scattered fibrin. (Figure 2)

### 2.5. Final diagnosis

Kikuchi Disease



**Fig. 1:** FNA smears showing degenerating neutrophils against dense necrotic background



**Fig. 2:** HP section showing effaced nodal architecture, replacement by dense necrosis with mononuclear cells

## 3. Discussion

Kikuchi disease, also known as histiocytic necrotizing lymphadenitis was originally described in young women. It is a rare benign condition of unknown etiology and it is characterized by cervical lymphadenopathy and fever.<sup>7,8</sup> It resolves in several weeks to months. Disease recurrence is rare. Fatalities though rare, have been reported.<sup>9</sup>

Histopathological examination of involved lymph nodes helps in differentiating Kikuchi Disease from several other conditions like T tuberculosis or Lymphoma. Hence, recognition of two conditions are crucial and awareness of this disorder helps prevent misdiagnosis and inappropriate treatment.<sup>10</sup>

While pathogenesis of Kikuchi Disease is unknown, the clinical presentation, course and histopathological changes suggest the possibility of an autoimmune response by T cell and histiocytes to an infectious agent. Several viruses like Epstein-Barr virus (EBV),<sup>11,12</sup> Human T-cell Lymphotropic virus type I (HTLV-1), Human Herpes Virus 6 (HHV-6), Human Herpes Virus 8 (HHV-8),<sup>13</sup> Parvovirus B19,<sup>14</sup> Paramyxovirus and Parainfluenza virus have been implicated. Apoptotic cell death mediated by cytotoxic CD8 positive T lymphocytes is the principal mechanism of cellular destruction.<sup>15–17</sup> A possible role of Interferon  $\gamma$  and Interleukin (IL-6) is suggested in the pathogenesis of this disease.<sup>18</sup>

The most common clinical presentation is with fever and cervical lymphadenopathy as seen in the present case. Fever is the primary symptom in 30% to 50% of patients and is typically of low grade, persisting for about a week.<sup>19</sup> The common clinicopathological findings include lymphadenopathy in all cases, leukopenia in 43%, increased ESR in 40%, anemia in 23% skin rash in 10%, arthritis in 7% and hepatosplenomegaly 3% of cases.<sup>20</sup>

Kikuchi disease is most often associated with localized involvement of lymph nodes, the cervical lymph nodes being the most frequently involved group. There may be extensive nodal involvement of other sites including axilla, epitrochlear, mediastinal, inguinal, intraparotid, iliac, retroocular, peri-pancreatic nodes.<sup>21</sup>

Histopathology plays a crucial role in the diagnosis and management of Kikuchi Disease.

## 4. Conclusion

Kikuchi Disease is a rare, benign, self-limiting disease of unknown etiology and needs to be differentiated from other close mimics like Tuberculosis or Lymphoma. Histopathological examination of the lymph node plays a crucial role in the prompt diagnosis and effective management of this condition.

## 5. Conflict of interest

None

## 6. Source of funding

None

## References

- Kikuchi M. Lymphadenitis showing focal reticulum cell hyperplasia with nuclear debris and phagocytes. *Acta Hematol Jpn.* 1972;35:379–380.
- Bosch X, Guilabert A, Miquel R, Campo E. Enigmatic Kikuchi-Fujimoto disease: a comprehensive review. *Am J Clin Pathol.* 2004;122(1):141–152.
- Kuo TT. Kikuchi's disease (histiocytic necrotizing lymphadenitis). A clinicopathologic study of 79 cases with an analysis of histologic subtypes, immunohistology, and DNA ploidy. *Am J Surg Pathol.* 1995;19(7):798–809.
- Lopez C, Oliver M, Olavarria R, Sarabia MA, Chopite M. Kikuchi-Fujimoto necrotizing lymphadenitis associated with cutaneous lupus erythematosus: a case report. *Am J Dermatopathol.* 2000;22(4):328–333.
- Kaur S, Thami GP, Kanwar AJ. Kikuchis disease, skin and systemic lupus erythematosus. *Br J Dermatol.* 2002;146(1):167–168.
- Menasce LP, Banerjee SS, Edmondson D, Harris M. Histiocytic necrotizing lymphadenitis (Kikuchi-Fujimoto disease): continuing diagnostic difficulties. *Histopathology.* 1998;33(3):248–254.
- Bosch X, Guilabert A. Kikuchi Fujimoto disease. *Orphanet J Rare Dis.* 2006;1:18.
- Bosch X, Guilabert A, Miquel R, Campo E. Enigmatic Kikuchi Fujimoto disease: a comprehensive review. *Am J Clin Pathol.* 2004;122(1):141–152.
- Hutchinson CB, E W. Kikuchi-Fujimoto Disease. *Arch Pathol Lab Med.* 2010;134(2):289–293.
- Rammohan A, Cherukuri SD, Manimaran AB, Manohar RR, Naidu RM. Kikuchi Fujimoto Disease: A Sheep in Wolf's Clothing. *J Otolaryngol Head Neck Surg.* 2012;41(3):222–226.
- Yen A, Fearneyhough P, Raimer SS, Hudnall SD. EB Vassociated Kikuchi's histiocytic necrotizing lymphadenitis with cutaneous manifestations. *J Am Acad Dermatol.* 1997;36:342.
- Hudnall SD, Chen T, Amr S. Detection of human herpesvirus DNA in Kikuchi Fujimoto disease and reactive lymphoid hyperplasia. *Int J Clin Exp Pathol.* 2008;1:362.
- Huh J, Kang GH, Gong G. Kaposi's sarcoma-associated herpesvirus in Kikuchi's disease. *Hum Pathol.* 1998;29:1091.
- Yufu Y, Matsumoto M, Miyamura T. Parvovirus B19 associated haemophagocytic syndrome with lymphadenopathy resembling histiocytic necrotizing lymphadenitis (Kikuchi's disease). *Br J Haematol.* 1997;96:868.
- Iguchi H, Sunami K, Yamane H. Apoptotic cell death in Kikuchi's disease: a TEM study. *Acta Otolaryngol Suppl.* 1998;538:250.
- Ohshima K, Shimazaki K, Kume T. Perforin and Fas pathways of cytotoxic T cells in histiocytic necrotizing lymphadenitis. *Histopathology.* 1998;33:471.
- Ura H, Yamada N, Torii H. Histiocytic necrotizing lymphadenitis (Kikuchi's disease): the necrotic appearance of the lymph node cells is caused by apoptosis. *J Dermatol.* 1999;26:385.
- Kubota M, Tsukamoto R, Kurokawa K. Elevated serum interferon gamma and interleukin6 in patients with necrotizing lymphadenitis (Kikuchi's disease). *Br J Haematol.* 1996;95:613.
- Dorfman RF, Berry GJ. Kikuchi's histiocytic necrotizing lymphadenitis: an analysis of 108 cases with emphasis on differential diagnosis. *Semin Diagn Pathol.* 1988;5:329.
- Kuo TT. Cutaneous manifestation of Kikuchi's histiocytic necrotizing lymphadenitis. *Am J Surg Pathol.* 1990;14:872.
- Kuo TT. Kikuchi's disease (histiocytic necrotizing lymphadenitis). A clinicopathologic study of 79 cases with an analysis of histologic subtypes, immunohistology, and DNA ploidy. *Am J Surg Pathol.* 1995;19:798.

## Author biography

**Abilash Sasidharannair Chandrakumari** Associate Professor

**Hemalatha AL** Professor

**Cite this article:** Sasidharannair Chandrakumari A, AL H. Kikuchi disease masquerading under a deviant presentation. *Arch Cytol Histopathol Res* 2019;4(4):345-347.