



Case Report

Dual ectopic thyroid – A rare case report

Ranjana Hawaldar^{1,*}, Varsha Sodani¹, R K Sodani¹, Sadhna Sodani¹

¹Sampurna Sodani Diagnostic Clinic, Indore, Madhya Pradesh, India



ARTICLE INFO

Article history:

Received 30-11-2019

Accepted 02-12-2019

Available online 07-01-2020

Keywords:

Dual ectopic thyroid

ETT

CT scan

FNAC

DET

TDC

ABSTRACT

Introduction: Congenital anomalies are very uncommon in thyroid gland and dual ectopic thyroid (DET) is even more rare entity. Till date only about 30 cases of DET have been reported in the world literature, majority of them being in the anterior midline neck region.

Case Report: Here we report a case of a seven year old male child with dual ectopic thyroid in lingual and subhyoid regions with mild hypothyroidism. The diagnosis of DET was based on CT scan findings and FNAC of the subhyoid swelling. The normal thyroid gland was not visualized in the neck on CT scan. The microscopy of the aspirate revealed abundant thick and thin colloid with normal thyroid follicular cells arranged in small sheets and clusters along with cyst macrophages confirming the swelling to be of thyroid origin.

Conclusion: Ectopic thyroid tissue is a rare entity and dual ectopic thyroid with absence of thyroid gland in its normal location is extremely rare. Clinical, radiological and cytological analysis helps in arriving at a diagnosis.

© 2019 Published by Innovative Publication. This is an open access article under the CC BY-NC-ND license (<https://creativecommons.org/licenses/by/4.0/>)

1. Introduction

Ectopic thyroid tissue (ETT) is a rare entity which occurs due to a developmental disorder in embryonal life in which the thyroid tissue fails to migrate completely from the midline plane of the floor of the pharyngeal gut to its usual pretracheal location in the third week of foetal life. The prevalence of ETT is estimated to be 1 in 100000 to 300000 in the world.¹ The entity ETT was first described by Hickman in 1869 in a newborn who was suffocated due to upper airway obstruction 16 hours after birth due to ectopic thyroid tissue.² ETT may be located in the lingual (at the base of the tongue), sublingual (below tongue), prelaryngeal (subhyoid) or substernal (mediastinal) region. However, a dual ectopic thyroid (DET) is a very rare entity. Till date only about 30 cases of DET have been reported in the world literature, majority of them being in the anterior midline neck region.³ Most of these cases presented in the

adolescent period and lingual and sublingual thyroid was the most common location with subhyoid region being the most common second ectopic location for the thyroid tissue.

Here we report a case of a seven year old male child with dual ectopic thyroid in lingual and subhyoid regions with mild hypothyroidism. The diagnosis of DET was based on CT scan findings and FNAC of the subhyoid swelling.

2. Case Report

A seven year old male child presented to our diagnostic centre with complaints of anterior neck swelling since one year. On examination, the swelling was diffuse, in the region of the thyroid gland and moved with deglutition. A presumptive diagnosis of a thyroid swelling was made clinically. There was no dyspnoea, change in voice or swallowing difficulty or any pressure symptoms due to the swelling. The detailed history did not indicate any thyroid hormone abnormality such as tiredness, constipation, cold intolerance etc. On examination the swelling was well defined, firm in consistency and moving with deglutition

* Corresponding author.

E-mail address: drranjana@sampurnadiagnostics.com (R. Hawaldar).

approximately measuring 2.3 x 1.3 cm in size. There was no cervical lymphadenopathy. The thyroid function tests revealed a mild hypothyroidism with T3 value - 1.61 ng/ml (Normal range 0.9-2.4), T4 value - 8.8 ug/dl (normal range 5.5 -12.8) and TSH value 11.3 uIU/ml (0.35-5.5).

A non-contrast CT of neck was performed. The normal thyroid gland was not visualized in the neck.

There was evidence of a well defined rounded hyperdense soft tissue structure in the midline anterior to the larynx just below the hyoid bone measuring approximately 2.3 x 1.3 x 1.5 cm. (Figure 4). A similar smaller hyperdense nodular structure was also seen in the midline at base of tongue which measured approx. 1.2 x 1.0 x 1.2 cm (Figure 3). The naso, oropharynx and the larynx appeared unremarkable. The salivary glands were unremarkable. The normal thyroid gland was not visualized in the neck. (Figure 2). A provisional diagnosis of dual ectopic thyroid tissue (lingual and pre-laryngeal) was made and a fine needle aspiration cytology was advised. FNAC was performed with a 23 gauge needle and a blood mixed fluid was aspirated. The microscopy revealed abundant thick and thin colloid with normal thyroid follicular cells arranged in small sheets and clusters along with cyst macrophages confirming the swelling to be of thyroid origin (Figure 1).

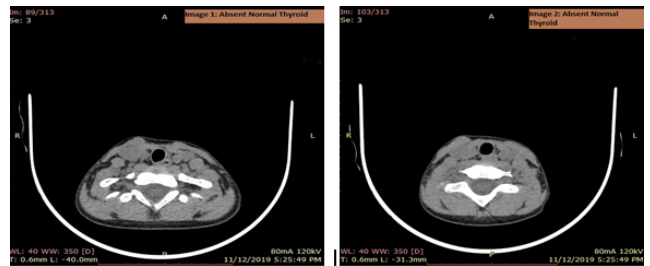


Fig. 2: Showing absent thyroid gland on CT scan

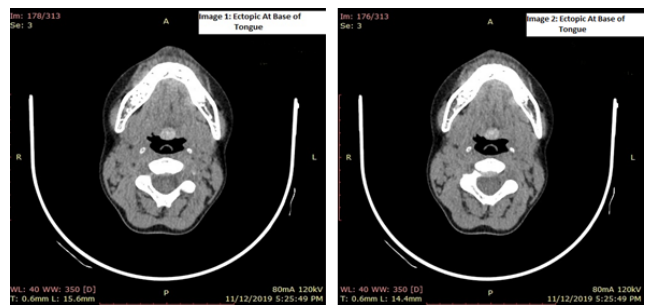


Fig. 3: Showing ectopic thyroid at base of tongue

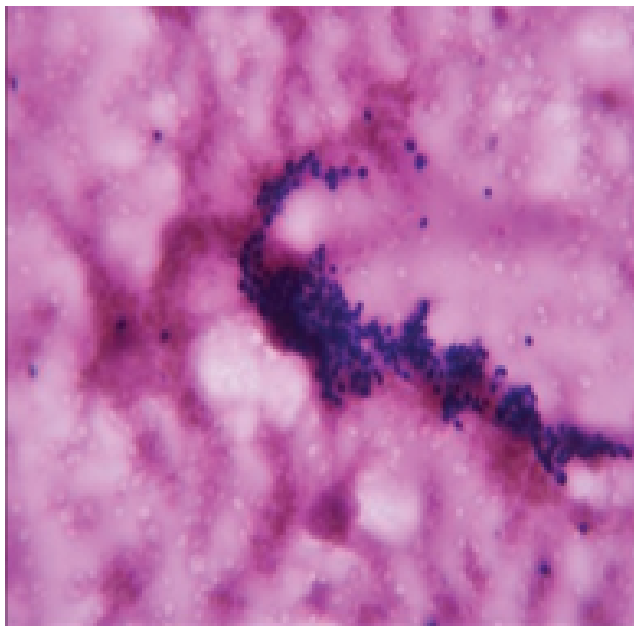


Fig. 1: Cytology showing benign follicular cells and colloid

3. Discussion

Congenital anomalies are very uncommon in thyroid gland and dual ectopic thyroid (DET) is even more rare entity. The ectopic thyroid tissue (ETT) may be located anywhere in the neck in suprahyoid, subhyoid, laryngeal region as well as in

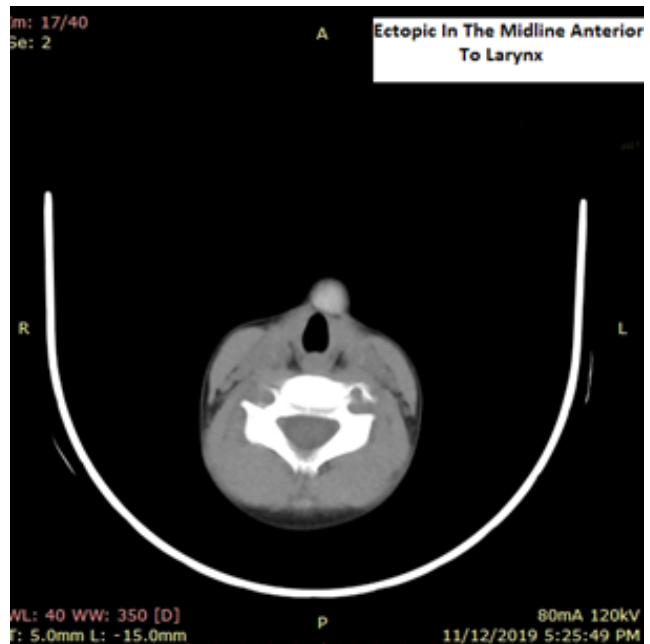

Fig. 4: Showing ectopic thyroid in the midline neck anterior to larynx

trachea, oesophagus, pericardial, diaphragm, branchial cysts etc. It can also be found in rare locations like parathyroid region, lymph nodes in the cervical region and even in the mesentery, adrenals and along the bifurcation of the Carotid. ETT to be present in two locations is very rare and at more than two sites is extremely rare finding. Only two cases of ETT in three locations have been reported in literature till date.³

The cause of DET is still unclear but one theory proposes that the antithyroid antibodies of the mother may cause arrest of descent of the thyroid gland in its normal location and cause thyroid hormone abnormalities later in the life of the affected child.⁴ In about 90% of the patients, lingual thyroid is the most common site and normal thyroid tissue is absent in about 75% of these patients.⁵ In DET, it is extremely rare to find thyroid gland in its normal location. Kuehn et al in 1966 reported the first case of dual ectopic thyroid with normal pretracheal thyroid gland.⁶ Clinically an ectopic thyroid gland becomes evident during adolescence or during pregnancy because of increased requirement of thyroid hormone during this period. It is estimated that about 55% of the patients present with clinical signs and symptoms of thyroid dysfunction during this period.⁷ However, in our case, although the child did not have any symptoms of thyroid hormone dysfunction, but his TSH was raised. Hormone production by ETT is insufficient or very little causing subclinical or clinically significant hypothyroidism. The negative feedback mechanism of the hypothalamic pituitary axis causes increased secretion of TSH thereby stimulating the thyroid follicular cells hyperplasia resulting in a clinically visible swelling of the ectopic thyroid gland. The TSH stimulation may cause a disproportionate growth of ectopic thyroid tissue in a different location as the effect of TSH may be different in different locations.⁸ Adolescents and young adults may show signs of bradycardia, chronic tiredness, easy fatigability constipation, cold intolerance etc.⁹

About 30 cases of dual ectopic thyroid have been reported in literature so far with a female to male ratio of 1.5:1 and age range of 4-71 years.¹⁰⁻¹² Ashutosh Kansal et al in 2014 described a case of DET.¹³ A recent case of DET was reported in 2018 by Shigenori N et al in a 15 year old girl.¹⁴ The most important diagnostic modality for diagnosing ectopic thyroid is an ultrasound examination or a CT scan/MRI followed by fine needle aspiration cytology.¹⁵

An ETT in the midline of neck should be differentiated from a thyroglossal duct cyst (TDC) which is also a developmental anomaly most commonly manifesting in early childhood. It moves with deglutition and on protrusion of tongue. The diagnosis is usually based on clinical, radiological and FNAC findings. A TDC is usually a result of failure of obliteration of the thyroglossal duct after the descent of the thyroid gland in embryonic life.¹⁶ However, only 1%-2% of ETT is found in a

TDC.¹⁷ Infection or abscess formation is very common in a thyroglossal duct cyst due to communication between the cyst and floor of the mouth causing oral flora to contaminate the cyst. FNAC of a thyroglossal duct cyst usually yields a cystic, turbid fluid. In our case the diagnosis was established by a CT scan followed by FNAC.

Asymptomatic or euthyroid patients do not require any treatment or surgical intervention. Hypothyroid patients require replacement therapy which may cause a reduction of the swelling. Surgery is considered only when patient complains of obstructive symptoms or there is evidence of a haemorrhage in the gland or a suspicion of malignant transformation in the ectopic thyroid gland.

4. Conclusion

Ectopic thyroid tissue is a rare entity and dual ectopic thyroid with absence of thyroid gland in its normal location is extremely rare. Clinical, radiological and cytological analysis helps in arriving at a diagnosis.

5. Source of Funding

None.

6. Conflict of Interest

None.

References

1. Madhurkar R, Acharya D, Ravichandra G, Vasu CK, Haris A. Dual thyroid ectopia: A rare case report. *J Evol Med Dent Sci*. 2013;2:5601–5604.
2. Hickman W. Congenital tumour of the base of the tongue pressing down the epiglottis on the larynx and causing death suffocation sixteen hours after birth. *Trans Pathol Soc Lond*. 1869;20:160–161.
3. Sood A, Seam RK, Gupta M, Sharma DR, Bhardwaj P. Dual ectopic thyroid: A case report with review of literature. *Iran J Radiol*. 2011;8:29–32.
4. Grossman A, Olonovski D, Barenboim E. Hypothyroidism caused by a nonvisible lingual thyroid. *Head Neck*. 2004;26:995–1003.
5. Guerra G, Cinelli M, Mesolella M, Tafuri D, Rocca A, et al. Morphological, diagnostic and surgical features of ectopic thyroid gland: a review of literature. *Int J Surg*. 2014;12:S3–S11. Supplement 1) S3-.
6. Kuehn PG, Newell RC, Reed JF. Exophthalmos in a woman with lingual, subhyoid and lateral-lobe thyroid glands. *Engl J Med*. 1966;274:652–654.
7. Meng Z, Lou S, Tan J, Jia Q, Zheng R, et al. Scintigraphic detection of dual ectopic thyroid tissue: experience of a Chinese tertiary hospital. *PLoS ONE*. 2014;9:95686.
8. Pintar JE, Allerand CDT. Normal development of the hypothalamic-pituitary-thyroid axis. In: Braverman LE, Utiger RD, editors. *Werner and Ingbar's the thyroid: a fundamental and clinical text*. Philadelphia: Lippincott Williams & Wilkins; 1991. p. 11–14.
9. Dalla JS, Foley TP. Hypothyroidism. In: Sperling MA, editor. *Pediatric Endocrinology*. WB Saunders Co; 1996. p. 391–400. 3rd ed.
10. Sood A, Sood V, Sharma DR, Seam RK, Kumar R. Thyroid scintigraphy in detecting dual thyroid: a review. *Eur J Nucl Med Mol Imaging*. 2008;35(4):843–846.

11. Kwon HJ, Jin SN, Lee SH, Kim DH. Adenomatous hyperplasia arising from dual ectopic thyroid. *Clin Exp Otorhinolaryngol.* 2009;2(3):155–163.
12. Galiana PA, Gómez RC, Alborg VC, Sánchez AR. Dual ectopic thyroid: subclinical hypothyroidism after extirpation of a submaxillary mass. *Rev Esp Med Nucl.* 2009;28(1):26–29.
13. Kansal A, Aggarwal S. Two are not always better than one' - Dual Ectopic Thyroid: A rare anomaly. *Thyroid Res Pract.* 2014;11:113–115.
14. S N, Masuda, M I. Dual ectopic thyroid associated with thyroid hemiagenesis Shigenori Nakamura, Masuda, and Masatoshi Ishimori *Endocrinol Diabetes Metab Case Rep.* 2018;2018:18–0026.
15. Abdallah-Matta MP, Dubarry PH, Pessey JJ, Caron P. Lingual thyroid and hyperthyroidism: a new case and review of the literature. *J Endocrinological Invest.* 2002;25(3):264–267.
16. Cheng CY, Chang YL, Hsiao JK, Wang CP, Kaohsiung. Metachronous thyroglossal duct cyst and inferior parathyroid cyst: a case report. *J Med Sci.* 2008;24(9):487–491.
17. Mohan PS, Chokshi RA, Moser RL, Razvi SA. Razvi SA Thyroglossal duct cysts: a consideration in adults. *Am Surg.* 2005;71(6):508–511.

Author biography

Ranjana Hawaldar Consultant Pathologist

Varsha Sodani Consultant Sonologist

R K Sodani Consultant Sonologist

Sadhna Sodani Associate Professor Microbiology

<p>Cite this article: Hawaldar R, Sodani V, Sodani RK, Sodani S. Dual ectopic thyroid – A rare case report. <i>Arch Cytol Histopathol Res</i> 2019;4(4):355-358.</p>
