



Case Report

Cutaneous metastasis of breast carcinoma on forearm-Classic FNAC finding

Pragati Upasham¹, Surabhi Vidhale^{1,*}

¹Dept. of Pathology, Dr. D. Y. Patil Medical College, Hospital & Research Centre, Maharashtra, India



ARTICLE INFO

Article history:

Received 19-11-2019

Accepted 30-11-2019

Available online 07-01-2020

Keywords:

FNAC

Cutaneous metastasis

Infiltrating Duct Carcinoma(IDC)

Cytology

ABSTRACT

Cutaneous metastasis from internal malignancies are significant from diagnostic point of view considering their variable clinical presentation. Although, carcinoma breast is a common primary cancer in females producing skin metastasis, it is rather an uncommon site as common metastatic sites include lymph node, bone, lung, liver etc. Here we present a case of cutaneous metastasis in a 54 years old female who presented with complaints of a nodular swelling for three years. The skin over the swelling showed discoloration. Patient was a known case of carcinoma breast for which she had been operated on and had received treatment eight years back. FNAC done from the swelling showed typical metastatic foci of infiltrating duct carcinoma. The case is being reported in view of its classical cytological picture and its uncommon site of presentation.

© 2019 Published by Innovative Publication. This is an open access article under the CC BY-NC-ND license (<https://creativecommons.org/licenses/by/4.0/>)

1. Introduction

Cutaneous metastases are significant from clinical point of view as these lesions can deceptively resemble primary skin tumors.¹

The incidence of skin metastasis varies but is somewhere between 3-10% in patients with a primary malignant tumor. Most common ones are melanoma (45%), breast cancer (30%), nasal sinus cancers (20%), cancer of the larynx and cancer of the oral cavity (12%) cases.²

Carcinoma en cuirasse is a term used for metastatic breast malignancy, occurring most commonly on the chest as a recurrence of breast cancer. However, it can also be the primary presentation.³

FNAC is a rapid technique which can be used to get the primary diagnosis in such lesions.

2. Case Report

A 54 years old female had presented with complaints of a nodular swelling along with lymphedema on the left forearm since 3 years, which had turned painful. It was a

single nodular swelling measuring around 3x2 cm. The skin over the swelling showed discoloration.

Past history: the patient was a known case of carcinoma breast for which she had been operated on and had received treatment eight years back.

The patient had reported to the hospital and had undergone FNAC procedure of the nodular swelling on the left forearm.

2.1. Cytological Findings

The cytology smears were stained with Papanicolau and Giemsa stains. Smears studied showed high cellularity with cohesive clusters and sheets of malignant cells, individual tumor cells were pleomorphic, round to oval with increased N :C ratio, vesicular nuclei and prominent nucleoli and moderate cytoplasm. Features were typical of metastatic foci of infiltrating duct carcinoma. [Figures 1 and 2]

3. Discussion

1. Lookingbill et al conducted a retrospective study on cutaneous metastases from different internal malignancies to determine the overall frequency of

* Corresponding author.

E-mail address: surabhividhale93@gmail.com (S. Vidhale).

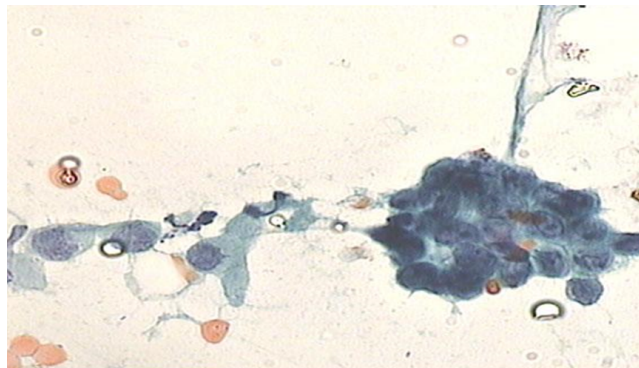


Fig. 1: FNAC smear 40x (Pap stain) showing cytomorphology of metastasis of IDC

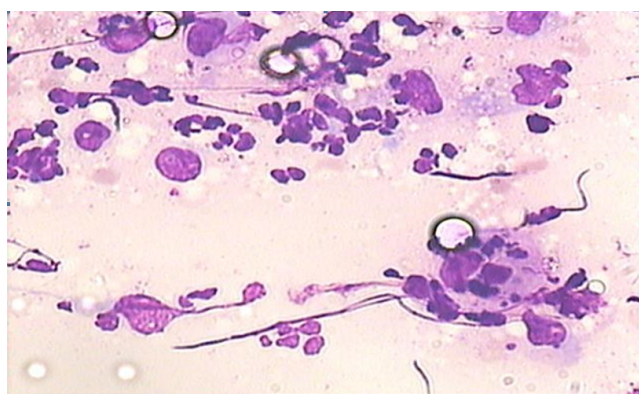


Fig. 2: FNAC smear 40x (Giemsa stain) showing cytomorphology of metastasis of IDC

cutaneous metastases and noted that breast cancer and melanoma were the most common primary malignancies. In this study the authors analysed the data of ten years from tumor registry files and observed that out of 4020 patients with metastatic disease 10% presented with cutaneous secondaries.⁴ There are many studies in the medical science literature documenting the significant role played by FNAC in detecting primary lesions in cutaneous metastases, it is useful in both scenarios, such as when the primary is unknown and where the clinical details locating the primary are available.

- Using FNAC as primary technique Handa U et al studied 138 cases of cutaneous and subcutaneous metastases from visceral malignancies and observed that out of 101 cases with known primary, majority were from breast carcinoma (24 cases). The common site for location of metastatic foci of breast carcinoma were found to be chest wall (22 cases) followed by single case of metastatic deposits on the arm and thigh

respectively. In our case, the patient presented with lymphedema and nodular lesion on forearm.⁵

- Mahore et al have also reported a case of ‘*Carcinoma en cuirasse*’ in a 50 years old female, where pathological evaluation was based mainly on cytology.⁶

4. Conclusion

Thus, in conclusion we state that in spite of limitations of this technique, having complete clinical details of the patient combined with cytopathologist’s efforts in applying accurate skills to get clear cytomorphological picture on FNAC smears will help the clinicians in determining the treatment and follow-up protocol and ultimately giving maximum benefit of this technique to the patient.

5. Source of Funding

None.

6. Conflict of Interest

None.

References

- Gupta B, Mallya V, Jain S, Agarwal PN. Utility of FNAC in Dermatological Manifestations of Metastatic Cancer with the Review of the Literature. *J Cytol.* 2018;35(4):237–241. Available from: 10.4103/JOC.JOC.158.17.
- Madabhavi I, Kadakol N, Chavan C, Sarkar M. Multiple Subcutaneous Nodules Leading to Diagnosis of Colon Cancer. *Middle East J Dig Dis.* 2018;10(3):188–191. Available from: 10.15171/mejdd.2018.109.
- Mullinax K, Cohen JB. Carcinoma en cuirasse presenting as keloid of the chest. *Dermatol Surg.* 2004;30:226–228. PUBMED] [FULLTEXT.
- Lookingbill DP, Spangler N, Helm KF. Cutaneous metastases in patients with metastatic carcinoma: A retrospective study of 4020 patients. *J Am Acad Dermatol.* 1993;29(2):228–236.
- Handa U, Kundu R, Dimri K. Cutaneous Metastasis: A Study of 138 Cases Diagnosed by Fine-Needle Aspiration Cytology. *Acta Cytologica.* 2017;61:47–54. Available from: 10.1159/000453252.
- Mahore SD, Bothale KA, Patrikar AD, Joshi AM. Carcinoma en cuirasse: A rare presentation of breast cancer. *Indian J Pathol Microbiol.* 2010;53:351–358.

Author biography

Pragati Upasham Professor

Surabhi Vidhale Resident

Cite this article: Upasham P, Vidhale S. Cutaneous metastasis of breast carcinoma on forearm—Classic FNAC finding. *Arch Cytol Histopathol Res* 2019;4(4):359-360.