



Original Research Article

A histomorphological study of lesions of tonsil in tertiary care hospital

B Nikethan¹, Neethu G V^{1,*}, Rashmi P¹, Dipti Anu¹¹Dept. of Pathology, J.J.M Medical College, Davangere, Karnataka, India

ARTICLE INFO

Article history:

Received 28-01-2020

Accepted 12-02-2020

Available online 18-03-2020

Keywords:

Chronic tonsillitis

Tonsillectomy

Histopathology.

ABSTRACT

Introduction: Palatine tonsils are paired masses of lymphoid tissue which act as immunologic barrier against the entry of pathogenic agents into the respiratory and digestive tracts. Despite their protective function, tonsils are prone to infection. Tonsillitis is a common disease especially among the children. Chronic tonsillitis is a disease with repeated attacks of acute tonsillitis or a sub-clinic form of a resistant or poorly treated infection.

Aim: To study the histomorphological findings of various lesions of tonsils.

Materials and Methods: A cross sectional study was carried out at a department of pathology in a tertiary care hospital for a period of two years. A total 160 cases of the histomorphologically identified tonsillectomy specimens were included and stained by Hematoxylin & Eosin .

Results: We studied histopathology of 160 cases, out of which 156 were tonsillectomy specimens, 4 were tonsillar biopsies. The age of patients ranged from 1 to 60 years. In our study the histomorphological diagnosis showed 45(28.1%) cases showed chronic tonsillitis, 62(38.7%) cases of follicular tonsillitis, 5(3.2%) cases of chronic tonsillitis showed actinomycotic colonies, with no tissue reaction, 2(1.2%) cases of acute on chronic tonsillitis, and 40(25%) cases of reactive lymphoid hyperplasia and 5(3.2%) cases of Acute suppurative tonsillitis 1(0.6%) cases and 1(0.6%) case of moderately differentiated squamous cell carcinoma were seen.

Conclusion: Routine histomorphological study of tonsillectomy specimens has a low cost-benefit rate, and most diagnostic tool for early screening and follow-up of malignancy.

© 2020 Published by Innovative Publication. This is an open access article under the CC BY-NC-ND license (<https://creativecommons.org/licenses/by/4.0/>)

1. Introduction

Tonsillar diseases are the most common encountered health-related issues in ear, nose and throat (ENT) diseases in children and adults.¹Waldeyer's ring is a lymphatic aggregate located at the wall of pharynx. It consists of six elements according to their site: palatine, lingual, nasopharyngeal (adenoids) and tubal tonsils, in addition to lateral pharyngeal bands and lymphatic aggregates at posterior pharyngeal wall. The definitive function of Waldeyer's ring is unknown but it is thought to have important role in the body's immune system where coming antigens may be aspirated or ingested.²

The palatine tonsils are two ovoid masses of lymphoid tissue situated on either side of the oropharynx. They are coated by non-keratinized stratified squamous epithelium as an extension of the oropharyngeal mucosa, including 15 deep crypts that invaginate into the parenchyma, in which B – lymphocyte are found.²

Tonsillitis is one of the commonest infectious diseases seen commonly in the young age group. Various organisms including viruses like Reo virus, Adenovirus, Influenza virus and Echo virus, and bacteria like Group Beta-hemolytic Streptococcus are implicated in causation of tonsillitis. Rarely, it can be caused by Fungi or Parasites.³ Tonsillectomy is generally indicated when there are frequent attacks of acute tonsillitis. Other indications of tonsillectomy include obstructive sleep apnea, quinsy, tonsillar cysts and suspicious of malignancy.⁴

* Corresponding author.

E-mail address: neethugv@gmail.com (Neethu G V).

The purpose of the study was histomorphological findings of various lesions of tonsil in a tertiary care hospital.

2. Materials and Methods

This is a cross-sectional study carried out at the Department of Pathology, JJM medical college from January 2017 to December 2018. A total of 160 cases received, out of which 156 were tonsillectomy specimens, 4 were tonsillar biopsies and were evaluated. All the patient with excised tonsillectomy and tonsillar biopsy specimens were included and patient taking treatment for primary neoplasm in tonsil were excluded. Patients age, sex, duration and complete clinical examination were noted from case sheet. The tonsillectomy specimens were fixed in 10% buffered formalin, 3 to 5 microns thick sections were made from formalin fixed, paraffin-embedded blocks and stained with H&E and examined under microscope.

3. Results

A total of 160 cases were studied with 86(53.75%) male and 74(46.25%) female patients with age ranged from 5 to 60 years with a mean age of 20.2 years. The majority of cases falling in the range between 10-20 years (110 cases, 68.75%), followed by 20-30 years (30 cases, 18.75%) and 5 cases (6.25%) in the range of 0-6 years. The most common clinical presentation was recurrent intermittent episodes of throat pain, recurrent tonsillitis associated with hypertrophy of tonsil and tonsillar mass or ulcer (Table 1).

In our study of 160 cases, histomorphological examination showed various non-neoplastic and neoplastic lesions. (Table 2) 45(28.1%) cases showed chronic tonsillitis, 62(38.7%) cases of follicular tonsillitis, 5 (3.2%) cases of chronic tonsillitis showed actinomycotic colonies, with no tissue reaction. Two (1.2%) cases of acute on chronic tonsillitis, and 40(25%) cases of reactive lymphoid hyperplasia and 5(3.2%) cases of Acute suppurative tonsillitis were seen. Malignancy was observed in 1(0.6%) cases and diagnosed as moderately differentiated squamous cell carcinoma.

4. Discussion

Palatine and nasopharyngeal tonsils are the lymphatic clusters of the respiratory and digestive tract epithelium. The tonsils are enclosed by fibrous and dense capsule, separating them from a deeper connectivetissue.^{5,6} Tonsils arises from the second pair of pharyngeal pouches, where endoderm bears the covering epithelium and mesenchymal structure giving origin to the lymphoid tissue.⁷ In younger age group recurrent and chronic tonsillitis is very common. Malignancy of tonsils is also not very uncommon.

Recurrent and chronic tonsillitis leads to hyperplasia of the tissue and the treatment given is surgical removal

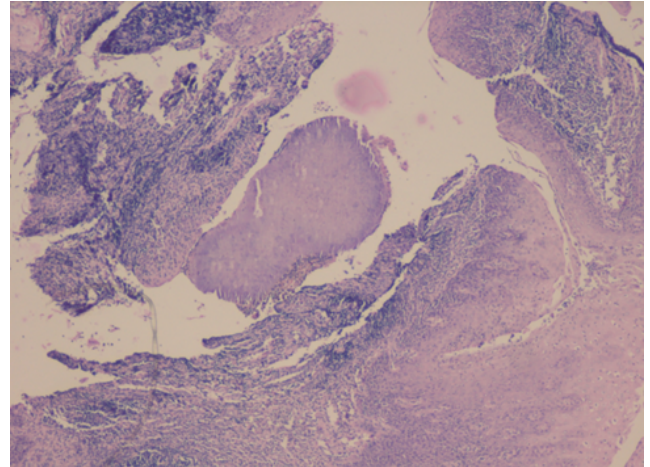


Fig. 1: Photograph showing actinomycotic colonies with in tonsillar crypt (H & E x100)

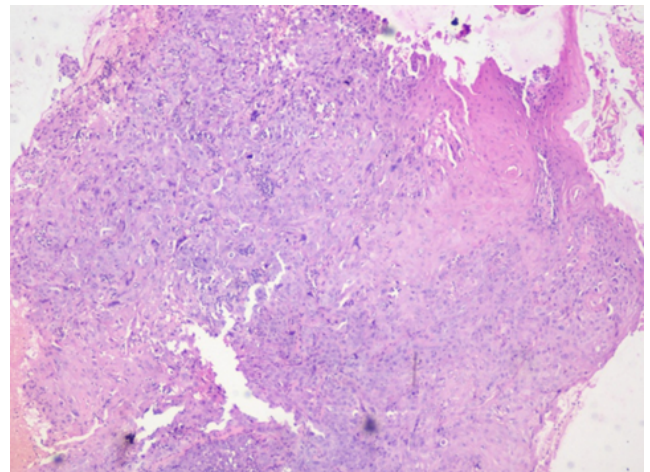


Fig. 2: Photograph showing Squamous cell carcinoma (H & E x100)

of tonsils, but there is little information about the histopathological findings in a tonsillectomy specimen both in the textbooks and in the literature.⁸

Chronic tonsillitis most often affects children, but can be seen in adults, probably due to a local dysfunction of the epithelium. The recurrent chances of acute tonsillitis is attributed due to the bacteria survived intracellularly, thus evading antibiotic killing and causing re-infection. Repeated attacks of tonsillitis can lead to tonsillar hypertrophy causing airway obstruction, thus leading to excision. Many studies stated that though chronic inflammation is present in both tonsillitis and tonsillar hypertrophy, it is more marked in tonsillitis patients. Fibrosis can only be seen in cases of tonsillitis. However, high bacterial load and elevation of immunologically active cell population in the tonsils are observed in both groups of patients.⁹

Table 1: Most common clinical presentation (symptoms)

Symptoms	Percentage (%)
Throat pain	91.2
Previous history of fever	72.5
Snoring	69.9
Foreign body sensation	63.4
Cough	55.3
Apneic spells	18.7

Table 2: Distribution of Cases on the based on histopathology diagnosis.

Histopathological diagnosis	No. of specimens (n)	Percentage (%)
Chronic tonsillitis	45	28.1
Follicular tonsillitis	62	38.7
Chronic tonsillitis showed actinomycotic colonies	5	3.2
Acute on chronic tonsillitis	2	1.2
Reactive lymphoid hyperplasia	40	25
Acute suppurative tonsillitis	5	3.2
Moderately differentiated squamous cell carcinoma.	1	0.6
Total	160	100

Tonsillectomy is the most commonly performed surgical procedure in pediatric patients. The ages of the patients in this study coincide with the age group where hypertrophy and tonsillitis are more intense and frequent.^{10,11}

In our study patients' age group ranged from 5 - 60years, majority of the patients (68.75%) were less than 20 years of age. However one patients with tonsillar malignancy were of higher age group. Among 160 cases, a slight predominance of male (53.75%) over female (46.25%) was observed. The majority of the cases were children (94%) presenting recurrent tonsillitis due to hypertrophy of palatopharyngeal tonsils (66,8%), which is in accordance with the literature worldwide, which may be consistent, with microorganisms growth could stimulate proliferation of lymphoid elements.¹²

In our study histological diagnoses were chronic tonsillitis in 45(28.1%), follicular tonsillitis in 62(38.7%), chronic suppurative tonsillitis (quinsy) in 5(3.2%), Chronic tonsillitis showed actinomycotic colonies in 5(3.2%), lymphoid hyperplasia in 40(25%) and scc in 1(0.6%) respectively. This is similar to the findings of Ikram M et al.¹³ except that the proportion varies

Ugras et al¹⁴ introduced eight histopathologic criteria in all palatine tonsils which includes: 1- Presence of slight-moderate lymphocyte infiltration in the surface epithelium, 2 - Presence of abscess leading to the defect in the surface epithelium (Ugras's abscess), 3- Presence of extensive lymphocyte infiltration leading to the defect in the surface epithelium, 4- Presence of polymorphonuclear leukocytes in the surface epithelium and in the sub epithelial area, 5- Presence of lymphoid hyperplasia, 6- Increase in the plasma cells number in the sub epithelial area and in the interfollicular area, 7- Presence of fibrosis and 8- Presence of atrophy. Seven out of eight criteria they studied

were more closely associated with chronic tonsillitis, only one criteria (the presence of lymphoid hyperplasia) was foremost in chronic tonsillar hypertrophy compared with chronic tonsillitis. In our study the presence of mild - moderate lymphocyte infiltration in the surface epithelium seen in 102(88.1%) cases, the presence of Ugras's abscess and/or diffuse lymphocyte infiltration leading to the defect in the surface epithelium was seen in 90(77.2%) cases, increase in the plasma cells number in the subepithelial area and in the interfollicular area in 65 cases (58.5%), the presence of polymorphonuclear leukocytes in the surface epithelium and in the subepithelial area in 32 cases (26%), the presence of lymphoid hyperplasia in 01 cases (0.75%), the presence of fibrosis in 03 cases (3.2%) and the presence of atrophy was present in 01cases(0.75%).

Actinomycetes are filamentous bacteria and present as oral cavity commensal organisms. When present in the tonsils, they are associated with recurrent tonsillitis along with complaints of sore throat, fever. Human actinomycosis is mainly caused by *A.israelii*.¹⁵ Van Lierop et al¹⁶ found no tissue reaction due to actinomyces colonies and hence reported no correlation between tonsillar actinomycosis and recurrent tonsillitis. In our study, five cases of chronic tonsillitis showed actinomycotic colonies, without tissue reaction.

Carcinoma arising from tonsils are usually is squamous in origin and is related strongly to smoking, HPV infection and, to a lesser degree, alcohol ingestion.¹⁷ However, during the past 2 decades, numerous studies have shown that human papillomaviruses (HPV) are a risk factor for the development of oropharyngeal carcinoma.¹⁸ Squamous cell carcinoma (SCC) is the most common malignancy followed by Non-Hodgkin's lymphomas (NHL) in the tonsil. In our study, we observed one case of SCC which correlates Babu

et al¹⁹ reported a total of 5 cases of tonsillar malignancy which includes two undifferentiated carcinomas, two NHLs, and one SCC.

5. Conclusion

In conclusion, chronic tonsillitis is the most common lesion diagnosed in tonsil. However the histomorphology play important role of in evaluation of a patient with chronic tonsillitis for earlier surgical intervention and hence reduction in associated morbidity.

6. Source of funding

None.

7. Conflict of Interest

None.

References

- Guerra MM, Garcia E, Pilan RR, Rapoport PB, Campanholo CB, et al. Antibiotic use in post-adenotonsillectomy morbidity: a randomized prospective study. *Braz J Otorhinolaryngol.* 2008;74(3):337–341.
- Dell’Arima AR, Juarez AJ, d Mello C, Nardi JC, Kobari K, et al. Histological analysis of tonsillectomy and adenoidectomy specimens - January 2001 to May 2003. *Braz J Otorhinolaryngol.* 2005;71(1):18–22.
- Alnori HA, Mahmud KA, Mohammed AM. Bacteriological, Serological and Histopathological Study on Tonsillectomy Specimens. *Iraqi Postgraduate Med J.* 2014;13:219–225.
- Gozal D, Jr DWP. Snoring During Early Childhood and Academic Performance at Ages Thirteen to Fourteen Years. *Pediatr.* 2001;107:1394–1399.
- Junqueira LC. Carneiro J *Histologia Básica*. vol. 1999. Guanabara Koogan: Rio de Janeiro ; p. 242–243.
- Alves AL, Scala W, Barros MD, Dolci J. Histological analysis of 24 pharyngeal tonsils of patients undergoing adenoidectomy or adenotonsillectomy. *Rev Bras Otorrinolaringol.* 2002;68(5):615–618.
- L MK. *Embriologia Clínica*. In: 4th edn, et al., editors. *Embriologia Clínica*. Rio de Janeiro: Guanabara Koogan ; 1996., p. 259–262.
- Erkiliç S, Aydın A, Koçer NE. Histological features in routine tonsillectomy specimens: the presence and the proportion of mesenchymal tissues and seromucinous glands. *J Laryngol Otol.* 2002;116(11):911–913.
- Mal RK, Oluwasanmi AF, Mitchard JR. Tonsillar crypts and bacterial invasion of tonsils. *Clin Otolaryngol.* 2008;33(3):293–295.
- Casselbrant ML. What is wrong in chronic adenoiditis/tonsillitis anatomical considerations. *Int J Pediatr Otorhinolaryngol.* 1999;49:S133–S135.
- Fontes MJF, Bottrel FB, Fonseca MTM, Lasmar LB, Diamante R, et al. Early diagnosis of streptococcal pharyngotonsillitis: assessment by latex particle agglutination test. *J Pediatr.* 2007;83(5):465–470.
- Costa FN, Santos O, Weckx L, Pignatari SN. Microbiological study of the core and surface of the palatine tonsils in children with recurrent pharyngotonsillitis and adenotonsillar hypertrophy. *Rev Bras Otorrinolaringol.* 2003;69(2):181–184.
- Ikram M, Khan MAA, Ahmed M, Siddiqui T, Mian MY. The Histopathology of Routine Tonsillectomy Specimens: Results of a Study and Review of Literature. *Ear Nose Throat J.* 2000;79(11):880–882.
- Uğraş S, Kutluhan A. Chronic tonsillitis can be diagnosed with Histopathological findings. *Eur J Gen Med.* 2008;5(2):95–103.
- Khatib KW, Jagtap SV, Patel PM, Bisht TV, Shukla DB. Tonsillar Actinomycosis - A Case Report. *Int J Health Sci Res.* 2014;6(15):28–32.
- AC VL, Prescott CA, Sinclair-Smith CC. An investigation of the significance of Actinomycosis in tonsil disease. *Int J Pediatr Otorhinolaryngol.* 2007;71(12):1883–1888.
- Johansen LV, Overgaard J, Overgaard M, Birkler N, Fisker A. Squamous cell carcinoma of the oropharynx: an analysis of 213 consecutive patients scheduled for primary radiotherapy. *Laryngoscope.* 1990;100(9):985–990.
- Näsman A, Attner P, Hammarstedt L, Du J, Eriksson M, et al. Incidence of human papillomavirus (HPV) positive tonsillar carcinoma in Stockholm, Sweden: An epidemic of viral-induced carcinoma? *Int J Cancer.* 2009;125(2):362–366.
- PBabu A, Mallik P, Pradhan S, Sobita P, Sudhiranjan TH, et al. Tonsillar malignancy - Review of clinico-pathological presentation, diagnosis, and current treatment modalities: A case series. *J Med Soc.* 2013;27(2):147–150.

Author biography

B Nikethan Associate Professor

Neethu G V Assistant Professor

Rashmi P Post Graduate

Dipti Anu Post Graduate

Cite this article: Nikethan B, Neethu G V, Rashmi P, Anu D. **A histomorphological study of lesions of tonsil in tertiary care hospital.** *IP Arch Cytol Histopathology Res* 2020;5(1):14-17.