



## Original Research Article

## Histopathologic study of Mucinous lesions of the appendix

Ch. Geetha<sup>1,\*</sup>, Asra Farheen<sup>2</sup>, A K Deshpande<sup>2</sup><sup>1</sup>Dept. of Pathology, Govt. Medical College, Nalgonda, Telangana, India<sup>2</sup>Dept. of Pathology, Kamineni Academy of Medical Sciences and Research Centre, Hyderabad, Telangana, India

## ARTICLE INFO

## Article history:

Received 02-01-2020

Accepted 30-01-2020

Available online 18-03-2020

## Keywords:

Appendiceal mucinous tumors

Cystadenoma

Cystadenocarcinoma

Mucocele

Histopathology

## ABSTRACT

**Introduction:** Mucinous lesions of appendix are rare with an incidence of about 0.2 to 0.7% of all the appendicectomy specimens. The mucinous lesions of appendix range from simple retention cyst to malignant mucinous adenocarcinoma. Majority of mucinous appendiceal neoplasia are epithelial type (70%) with circumferential involvement of mucosa. Peritoneal seeding and pseudomyxoma peritonei can occur with both frankly malignant as well as low-grade appendiceal neoplasms. Nearly 50% of appendiceal malignancies present clinically as acute appendicitis and can be detected by imaging modalities. Aim of this study is to analyse the incidence, age and sex predilection, clinical presentation and histopathology of mucinous lesions of appendix.

**Materials and Methods:** It is a retrospective study of all the mucinous lesions of appendix diagnosed at Dept. of Pathology, Kamineni Academy of Medical Sciences and Research Centre (KAMSRC) from 2013-2017. Clinical details and relevant radiological investigations are noted from case sheets. Microscopic examination is done on slides stained with routine H & E and AB-PAS. Diagnosis and classification is based on WHO 2010 and recommendations in the AJCC 8th edition.

**Results:** Mucinous lesions accounted for 0.8% (10/1200) of all appendicectomy specimens. The study included 10 cases of mucinous lesions of appendix (10 cases): Simple mucocele (2 cases), Benign mucinous adenomas (3 cases), Low grade Appendiceal Mucinous Neoplasm (LAMN) with pseudomyxoma peritonei (PMP) (1 case), Mucinous cystadenocarcinomas (4 cases). Benign lesions are seen in females and at a younger age as compared to malignancies which are common in males and at a older age. Most common presentation is abdominal pain followed by appendicitis. Mucosal hyperplasia and high grade appendiceal mucinous neoplasms (HAMN) are not seen in our study.

**Conclusion:** Mucinous lesions of appendix are rare. They are more common in females and associated with non-specific clinical features. Histopathology is critical for establishing diagnosis, further management and prognostication of all the mucinous lesions of appendix.

© 2020 Published by Innovative Publication. This is an open access article under the CC BY-NC-ND license (<https://creativecommons.org/licenses/by/4.0/>)

## 1. Introduction

Mucinous lesions of appendix are rare and account for 0.2 – 0.7% of all appendicectomy surgeries.<sup>1–5</sup> They are complex, diverse group of epithelial neoplasms ranging from simple mucoceles to complex pseudomyxoma peritonei. In 1842, Rokitsky first described mucocele as a dilatation of the appendiceal lumen by an abnormal mucus accumulation.<sup>6</sup> Morphologically mucocele refers to cystic dilatation of

appendix due to accumulation of gelatinous material.

Mucoceles of appendix are divided into four types based on histology: (1) simple retention cysts, (2) mucosal hyperplasia, (3) mucinous adenoma, and (4) mucinous adenocarcinoma.<sup>1</sup> The clinical presentation is nonspecific abdominal pain and sometimes as acute appendicitis because of localised inflammation. Mostly clinical presentation is rather non-specific making preoperative diagnosis rare. Histopathology is very crucial for diagnosis and categorisation of mucinous lesions.

\* Corresponding author.

E-mail address: [drgeetha\\_nims@yahoo.com](mailto:drgeetha_nims@yahoo.com) (Ch. Geetha).

In this study, we evaluated clinical, radiological and histopathological findings of all the mucinous lesions of appendix.

## 2. Materials and Methods

It is a retrospective study carried out at KAMSRC from 2013 to 2017 over a period of five years. It included ten cases of mucinous lesions of appendix. Clinical details and radiological findings were retrieved from case sheets.

All the specimens are collected in 10% neutral buffered formalin (NBF). Gross examination findings are noted in all the cases and the sections are taken accordingly. Sections are stained with Hematoxylin & Eosin (H&E). Special stain for mucin was done with AB-PAS as and when required. Diagnosis and classification is based on WHO 2010<sup>7</sup> and recommendations in the AJCC 8th edition.<sup>8</sup>

## 3. Results

Mucinous lesions of appendix are rare and accounted for 0.8% of all the appendectomy specimens. Benign lesions include simple mucoceles or retention cysts and benign neoplastic adenomas. Malignant lesions include invasive adenocarcinomas.

Benign lesions are more common than malignant lesions and account for 50% of all lesions. All the benign lesions are seen in females at a younger age in contrast to malignant lesions which are seen in males at an older age.

All the patients presented with clinical features of appendicitis (4 cases), pain abdomen (4 cases), abdominal pain and mass (2 cases)

Simple Mucocele (Retention cyst) are seen in 2/10 cases. One case was seen in 26 years female who presented with chronic appendicitis and underwent interval appendectomy. Other case is seen in 35 years female with dilated appendix. Gross examination revealed dilated appendix filled with mucoid material. Histopathology showed dilated lumen filled with mucinous material, lined by single layered, flattened epithelium. There is no proliferation or atypia of the lining epithelium.

The 2010 WHO classification recognizes 3 main categories of mucinous neoplasms: mucinous adenoma, LAMN and appendiceal adenocarcinoma.<sup>7</sup>

Benign mucinous adenomas accounted for 33% (3/10) cases (Figure 1). All the cases are seen in females with mean age of 44 year. Two cases clinically presented as appendicitis and one case presented with abdominal pain. Imaging revealed dilated appendix in two cases. One case was diagnosed as mucocele on ultrasonography. Gross examination revealed dilated appendix filled with mucin. Microscopy shows appendiceal mucosa thrown into villous architecture, composed of benign columnar cells with stratification and abundant mucin and is confined to mucosa with no evidence of invasion beyond muscularis

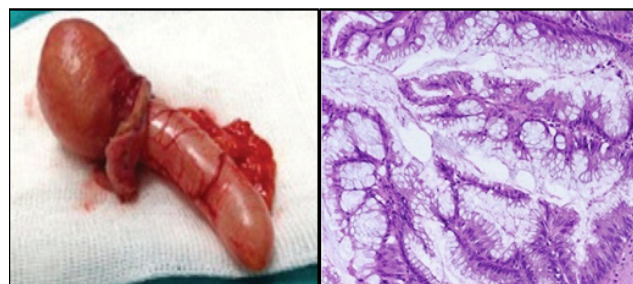mucosa.

Low grade appendiceal mucinous neoplasm (LAMN); One case 1/10 of LAMN is seen in our study. It is seen in 36 years female who presented with abdominal pain and mass and ultrasound revealed dilated appendix. Gross examination revealed dilated appendix of 6x7cm. filled with mucin. Histopathology revealed well differentiated adenoma with acellular mucin dissecting the muscularis propria of appendix. There is flattened epithelial growth with loss of muscularis mucosae and mild fibrosis of submucosa. In our study, LAMN is associated with low grade pseudomyxoma peritonei (PMP) with pools of mucin and scattered epithelial cells showing low grade cytological atypia in separately received omental biopsy

Mucinous cystadenocarcinoma is seen in 4 cases accounting for 40 % cases (Figure 2). All are males with a mean age of 60 yrs. Abdominal pain is the most common symptom. Imaging findings showed perforated appendix in two cases and growth at the base of the appendix in other case, Grossly the appendix is markedly enlarged with serosal congestion in all cases and two cases revealed perforation. Microscopy is characterised by invasive neoplastic glands with high grade cellular atypia and nuclear pleomorphism and mitotic activity extending into muscularis propria.

Mucinous hyperplasia and High grade appendiceal mucinous neoplasm (HAMN) are not encountered in our study

Summary of all the cases:



**Fig. 1:** Mucinous adenoma (A) Dilated appendix with dilated lumen obliterated by mucinous material (B) Appendiceal mucosa is lined by papillary folds composed of benign columnar cells with stratification and abundant mucin (H&E 200x)

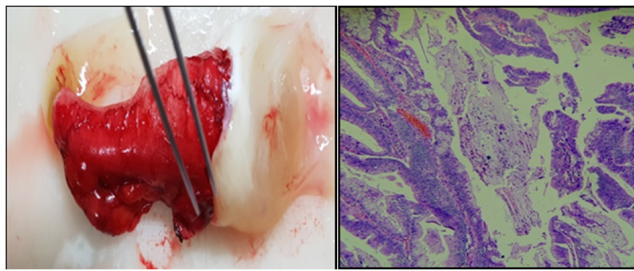
## 4. Discussion;

Primary tumors of the appendix are rare and represent less than 2% of surgical appendectomy specimens<sup>9</sup> They include epithelial tumors, carcinoid tumors, mesenchymal tumors, lymphomas. Mucinous neoplasms of the appendix are still rare and second only to carcinoids<sup>10</sup>

Mucocele of the appendix can result from obstruction of appendiceal ostium due to mucus, mucous hyperplasia, benign and malignant lesions. Other causes include fecal

**Table 1:**

S. No	Age	Gender	Clinical Diagnosis	Radiology findings	Histopathology
1	32	F	Abdominal pain-Appendicitis	Dilated appendix	Benign Mucinous Adenoma
2	50	F	Abdominal pain	Dilated appendix	Benign Mucinous Adenoma
3	36	F	Abdominal pain and mass	Dilated appendix	LAMN with pseudomyxoma peritonei
4	46	M	Abdominal pain and mass	USG;Dilated appendix CT-growth at the base of appendix	Mucinous Adenocarcinoma
5	60	M	Abdominal pain	Dilated appendix	Mucinous Adenocarcinoma
6	60	M	Abdominal pain	Perforated appendix	Mucinous Adenocarcinoma
7	61	M	Appendicitis	Perforated appendix	Mucinous Adenocarcinoma
8	26	F	Appendicitis	Interval appendicectomy	Retention cyst (Simple mucocele)
9	50	F	Appendicitis	Dilated appendix	Benign Mucinous Adenoma
10	48	F	Pain abdomen	Dilated appendix	Retention cyst (Simple mucocele)



**Fig. 2:** Mucinous adenocarcinoma (A) Dilated appendix with mucinous material at the base (B) Appendiceal mucosa is lined by papillary neoplastic glands infiltrating muscularis (H&E 200x)

impaction or polyps of the cecum, inflammation from surrounding tissues<sup>1</sup> and rare causes found in the literature are endometriosis and metastatic melanoma.<sup>11,12</sup> Presently the term mucocele is only used for the macroscopic description or for imaging and as a clinical term, never as a definitive diagnosis

Mucoceles of appendix are divided into four types based on histology: (1) simple retention cysts, (2) mucosal hyperplasia, (3) mucinous cystadenoma, and (4) mucinous cystadenocarcinoma.<sup>1</sup>

Simple mucoceles are retention cysts, characterised by accumulation of mucus with normal epithelial lining and rarely exceed 2 cm.<sup>13,14</sup> They result from an obstructing fecolith, extrinsic compression or inflammatory conditions and rarely endometriosis.

Mucinous neoplasms of appendix include Mucinous adenoma, Low-grade appendiceal mucinous neoplasm and Mucinous adenocarcinoma. Salient features of these three entities is summarised in Table 2

There are no cases of Mucinous hyperplasia and High grade appendiceal mucinous neoplasm in our study.

Mucinous lesions of appendix are rare and accounted for 0.8% (10/1200) of all the appendicectomy specimens in our study. This is in comparison to other studies where they represented 0.2 – 0.7% of all appendicectomy surgeries<sup>1-5</sup>

Benign mucinous lesions are more common than malignant lesions similar to studies by Morano et al and Higa et al<sup>1,20</sup>

In our study, Male to female ratio is 2:3. This is in contrast to other studies by Carr NJ et al.<sup>16</sup> which showed a male predominance (5 : 2). But in comparison to a retrospective study of 135 patients by Omari et al.<sup>10</sup> where 55% were females

Benign and mucinous lesions as a whole are more common in females as comparable to study by Morano WF.<sup>20</sup> Higa et al<sup>1</sup>

Mucoceles and mucinous cystadenomas are seen in females and all the mucinous adeno carcinomas are seen in males. However, AM are considered to occur more frequently in women.<sup>21</sup> Mucinous cystadenomas have high frequency in women compared to men with a ratio of 4:1, and it tends to affect patients over 50 years of age.<sup>6</sup> Other tumors of the gastro intestinal tract, ovary, breast and kidney can be associated in up to one-third of the patients.<sup>21</sup> Omari et al. recommend surveillance colonoscopy in patients with diagnosis of neoplastic mucinous lesions of appendix.<sup>21</sup>

All the cases of adeno cacinoma are seen in males and in the sixth decade similar to study to Tirumani et al.<sup>17</sup> They have an increased association with other colonic neoplasia and chronic ulcerative colitis but such association is not seen in our study.

Mean age of presentation of mucinous cystadenoma is 44 years, mucinous cystadeno carcinoma is 56.7 years. Cystadenocarcinomas are seen at a later age than cystadenomas similar to other studies

The most common clinical presentation is nonspecific abdominal pain as seen in 60% of cases similar to study

**Table 2:** Salient features of mucinous appendiceal neoplasms<sup>7,13–17</sup>

Mucinous adenoma	Low-grade appendiceal mucinous neoplasm (LAMN)	Mucinous adenocarcinoma
Confined to appendiceal mucosa	Non-invasive glands with mucin dissecting beyond the appendix	Invasive glands extending beyond the appendix
No extra-appendiceal mucin	Acellular or cellular extra- appendiceal mucin	Invasive epithelium in the extra-appendiceal mucin
Not associated with PMP	Associated with low-grade PMP	Associated with high-grade PMP
PMP Benign, no recurrences	Frequent recurrences	< 10% 10-year survival

**Table 3:** Mucinous adenocarcinoma

Parameter	Cerame MA <sup>18</sup>	Nitecki SS <sup>19</sup>	Present Study
Age	57.1	56.5	60
M:F	1.4:1	1.2:1	All are males
Presentation as Acute appendicitis	68%	50%	50%
Perforation	50%	-	50%

by Emre et al.<sup>22</sup> Abdominal pain is associated with mass in two cases. Appendicitis as clinical presentation is seen in 40% of all the cases in contrast to other studies by Omari et al<sup>21</sup> where only 8% to 14% of the cases presented as acute appendicitis.<sup>3,21</sup> Ruiz-Tovar et al.<sup>3</sup> reported 14% of their patients had an intraoperative diagnosis of appendicitis with AM. Other features can be weight loss, nausea and vomiting, obstipation, and change in bowel habits. They can also present as intestinal strangulation, appendiceal intussusception, or generalised abdominal pain<sup>5</sup>

Mostly clinical presentation is rather non-specific making preoperative diagnosis difficult. Preoperative diagnosis is possible with the help of radiological investigations (abdominal USG, CT, or MRI) when there is cystic dilation of the appendix, mural calcification of the appendix wall, luminal diameter greater than 15mm. Macroscopic appearance of the appendix examined intraoperatively gives a clue to the diagnosis. Histopathological examination of the specimen.<sup>23–25</sup> enables the establishment of final diagnosis. In our study, USG was done in all the cases which revealed a dilated appendix. CT scan was done in one case of adenocarcinoma which showed growth at the base of appendix.

Simple retention cyst of appendix is non-neoplastic dilated appendix filled with mucin. There are two cases in our study.

Histopathology showed flattened lining epithelium with no atypia. Most of the benign mucocoeles are asymptomatic. These are mostly detected incidentally during ultrasonography, computed tomography and other radiographic examinations of gastrointestinal tract, or during a laparotomy.<sup>5</sup> Simple appendectomy is the treatment of choice for simple mucocoeles.

#### 4.1. Mucinous adenomas

Adenomas show female predominance and typically occur in fifth decade but the age range is wide. Abdominal pain that mimics acute appendicitis is the most common clinical presentation. It can also present as an abdominal mass or as intussusception of the appendix or can be asymptomatic.

Grossly, appendix is dilated and filled with mucin. The serosa is smooth with absent mucin.

Microscopic examination reveals tumors limited to mucosa with intact muscularis mucosae. There is no mucin dissecting into the wall or mucin extrusion outside the appendix. The tumor consists of a proliferation of mucinous epithelial cells thrown into villi.

Appendiceal adenomas are benign and are treated by appendectomy alone.

#### 4.2. LAMN with pseudomyxoma peritonei

Low-grade appendiceal mucinous neoplasm (LAMN) is a rare malignancy accounting for 1% of gastrointestinal neoplasms and is found in less than 0.3% of appendectomy specimens.<sup>26,27</sup> In our study only one case is seen accounting to 0.1% of all appendectomy specimens.

They are commonly seen in men, particularly in the sixth decade in contrast in our study where LAMN is seen in 36 years female who presented with abdominal pain and mass. Other symptoms include abdominal pain, intussusception, and obstruction and some times asymptomatic.

Complications of LAMN include intussusception, ureteral obstruction, volvulus, small bowel obstruction (SBO), rupture, and PMP<sup>26,27</sup> In our case, it is associated with low grade PMP. PMP refers to the accumulation of mucin within the peritoneal cavity secondary to mucinous epithelial neoplasia. This most often occurs because of peritoneal spread of a mucinous neoplasm from the appendix but has been described with mucinous tumors from other sites, including colon, ovary, gallbladder,

pancreas, and urachus.

Imaging modalities for diagnosis include ultrasound (USG) and CT. In our case, USG was done which showed dilated appendix and CT scan revealed PMP.

Grossly, LAMN shows markedly dilated appendix filled with mucin. There is hyalinization and fibrosis of the appendiceal wall.<sup>26–28</sup> LAMNs less than two centimeters (cm) are rarely malignant. Masses larger than 6 cm have higher risk of malignant cells, a higher risk of appendiceal perforation, and development of PMP.<sup>27</sup>

Histopathology shows low grade atypical glandular cells and epithelial cells with “pushing invasion” of atypical cells creeping into the appendiceal wall with possible diverticular formation.<sup>28</sup> In our case, histopathology showed mucin pools and strips of cells on the serosal surface.

Management of LAMN includes the prevention of rupture, seeding, and development of PMP.<sup>27</sup> Right hemicolectomy with or without omentectomy is recommended when there is infiltration of malignancy into submucosa or with the presence of lymph node metastasis.<sup>29</sup>

#### 4.3. Mucinous adeno carcinoma

Adenocarcinomas of the appendix are rare entities, representing <0.5% of all gastrointestinal malignancies and 4–6% over lesions of the appendix neoplasm.<sup>9</sup> Collins et al<sup>30</sup> found an incidence of 0.082% among 50 000 appendectomy specimens. There is an increased incidence among men in some series<sup>8,18</sup> but not in others.<sup>19,31</sup> Patients usually present in fifth to seventh decade of life<sup>18,31</sup> and usually as acute appendicitis. Other less common modes of presentation include a palpable mass, obstruction, gastrointestinal bleeding, or symptoms.

Appendiceal adenocarcinomas are classified as adenocarcinoma not otherwise specified, mucinous adenocarcinoma, signet ring cell adenocarcinoma, and undifferentiated carcinoma. Only Mucinous adenocarcinoma are included in our study.

Invasive adenocarcinoma of the appendix is surgically treated by right hemicolectomy and lymph node dissection, in order to stage the tumor and ensure complete resection.<sup>19</sup>

In our study all the cases are diagnosed on histopathology of appendectomy specimens. Right hemicolectomy was advised in all the cases. Further follow-up details are not available.

Comparative study of age, M:F ratio, clinical presentation of mucinous adeno carcinoma with other studies is summarised in Table 3.

## 5. Conclusion

Mucinous lesions of appendix are rare. Mucinous lesions range from simple mucocele to mucinous adenocarcinomas. They are more common in females. Most of them present with non-specific abdominal pain making pre-operative clinical diagnosis difficult. Imaging shows dilated

appendix. Intra operative gross examination gives us a clue to diagnosis. Final diagnosis is established by histopathological study of the excised specimen. Neoplasms confined to the mucosa of the appendix are adenomas, whereas neoplasms extending beyond the appendix can be LAMNs or adenocarcinomas. The treatment for simple mucocele is appendectomy. Right hemicolectomy is advised for intermediate /malignant lesions depending on the size and location. Maximum care should be taken to avoid intraperitoneal rupture of a mucocele because of the risk of PMP. Risk of developing adenocarcinoma in colon, ovary, endometrium, breast, kidney is greater in patients with a mucocele than in the general population, warranting regular cancer surveillance and monitoring in these cases. Clear communication between the radiologist, pathologist and surgeon is essential for optimal patient management.

## 6. Source of funding

None.

## 7. Conflict of interest

None.

## References

- Rosai EJ, Pizzimbono CA, Wise L. Mucosal hyperplasia, mucinous cystadenoma, and mucinous cystadenocarcinoma of the appendix. A re-evaluation of appendiceal mucocele. *Cancer*. 1973;32(6):1525–1541.
- Marudanayagam R, Williams GT, Rees BI. Review of the pathological results of 2660 appendectomy specimens. *J Gastroenterol*. 2006;41(8):745–749.
- Ruiz-Tovar J, Teruel DG, Castiñeiras VM, Dehesa AS, Quindós PL, et al. Mucocele of the Appendix. *World J Surg*. 2007;31(3):542–548.
- Smeenk RM, van Velthuysen MLF, Verwaal VJ, Zoetmulder FAN. Appendiceal neoplasms and pseudomyxoma peritonei: A population based study. *Eur J Surg Oncol (EJSO)*. 2008;34(2):196–201.
- Yakan S, Caliskan C, Uguz A, Korkut MA, Çoker A. A retrospective study on mucocele of the appendix presented with acute abdomen or acute appendicitis. *Hong Kong J Emerg Med*. 2011;18(3):144–149.
- Rokitansky C. A Manual of Pathological Anatomy. *A Manual of Pathological Anatomy*;2:1855.
- Carr N, Sobin L, Carneiro F. Tumors of the appendix. In: Bosman FT, Carneiro F, Hruban RH, Theise ND, editors. World Health Organization classification of tumours. Lyon, France: IARC Press; 2010. p. 122–125.
- Carr NJ, Cecil TD, Mohamed F. Peritoneal Surface Oncology Group International. A consensus for classification and pathologic reporting of pseudomyxoma peritonei and associated appendiceal neoplasia: the results of the Peritoneal Surface Oncology Group International (PSOGI) Modified Delphi Process. *Am J Surg Pathol*. 2016;40(1):14–26.
- Connor SJ, Hanna GB, Frizelle FA. Appendiceal tumors: retrospective clinicopathologic analysis of appendiceal tumors from 7,970 appendectomies. *Dis Colon Rectum*. 1998;41:75–80.
- Pickhardt PJ, Levy AD, Rohrmann CA, Kende AI. Primary Neoplasms of the Appendix: Radiologic Spectrum of Disease with Pathologic Correlation. *Radio Graphics*. 2003;23(3):645–662.
- Alduaij AA, Resnick MB, Kawata M, Pricolo VE. Metastatic malignant melanoma presenting as an appendiceal. *J Oncol*. 2011;2011:4.

12. Driman DK, Melega DE, Vilos GA, Plewes EA. Mucocele of the appendix secondary to endometriosis: report Case Reports in Oncological Medicine 5 of two cases, one with localized pseudomyxoma peritonei. *Am J Clin Pathol*. 2000;113(6):860–864.
13. Pai RK, Longacre TA. Appendiceal mucinous tumors and pseudomyxoma peritonei: histologic features, diagnostic problems, and proposed classification. *Adv Anat Pathol*. 2005;12:291–311.
14. Pai RK, Beck AH, Norton JA, Longacre TA. Appendiceal mucinous neoplasms: clinicopathologic study of 116 cases with analysis of factors predicting recurrence. *Am J Surg Pathol*. 2009;33:1425–1439.
15. Misdraji J. Appendiceal mucinous neoplasms: controversial issues. *Arch Pathol Lab Med*. 2010;134:864–870.
16. Carr NJ, McCarthy WF, Sobin LH. Epithelial noncarcinoid tumors and tumor-like lesions of the appendix. A clinicopathologic study of 184 patients with a multivariate analysis of prognostic factors. *Cancer*. 1995;75:757–768.
17. Tirumania SH, Hill MF, Auer R. Mucinous neoplasms of the appendix: a current comprehensive clinicopathologic and imaging review. *Cancer Imaging*. 2013;13(1):14–25.
18. Cerame MA. A 25-year review of adenocarcinoma of the appendix. A frequently perforating carcinoma. *Dis Colon Rectum*. 1988;31:145–150.
19. Nitecki SS, Wolff BG, Schlinkert R, Sarr MG. The Natural History of Surgically Treated Primary Adenocarcinoma of the Appendix. *Ann Surg*. 1994;219(1):51–57.
20. Morano F, Gleeson. Clinicopathological features and management of appendiceal mucocoeles; a systemic review. *Am surg*. 2018;84(2):273–281.
21. Omari AH, Khamash MR, Qasaimah GR, Shammari AK, Yaseen MKB, et al. Acute appendicitis in the elderly: risk factors for perforation. *World J Emerg Surg*. 2014;9(1).
22. Emre A, Sertkaya M, Kale IT. Clinicopathological analysis of appendiceal mucinous tumors: A single-center experience. *Turk J Surg*. 2017;33:274–278.
23. Kilic MO, Inan A, Bozer M. Four mucinous cystadenoma of the appendix treated by different approaches. *Turk J Surg*. 2014;30(2):97–99.
24. Malya FU, Hasbahceci M, Serter A, Cipe G, Karatepe O, et al. Appendiceal mucocoele: clinical and imaging features of 14 cases. *Chirurgia (Bucur)*. 2014;109:788–793.
25. Stocchi L, Wolff BG, Larson DR, Harrington JR. Surgical Treatment of Appendiceal Mucocoele. *Arch Surg*. 2003;138:585–590.
26. Ramaswamy V. Pathology of mucinous appendiceal tumors and pseudomyxoma peritonei. *Indian J Surg Oncol*. 2016;7:258–267.
27. Padmanaban V, Morano WF, Gleeson E, Aggarwal A, Mapow BL, et al. Incidentally discovered low-grade appendiceal mucinous neoplasm: a precursor to pseudomyxoma peritonei. *Clin Case Rep*. 2016;4:1112–1116.
28. Misdraji J, Young RH. Primary epithelial neoplasms and other epithelial lesions of the appendix (excluding carcinoid tumors). *Seminars Diagn Pathol*. 2004;21(2):120–133.
29. Kelly KJ. Management of appendix cancer. *Clin Colon Rectal Surg*. 2015;28:247–255.
30. Collins DC. Adenomatous polyps of the vermiform appendix. *Surg Clin North Am*. 1932;12:1063–1067.
31. Proulx GM, Willett CG, Daley W. Appendiceal carcinoma: patterns of failure following surgery and implications for adjuvant therapy. *J Surg Oncol*. 1997;66:51–53.

### Author biography

**Ch. Geetha** Associate Professor

**Asra Farheen** Post Graduate

**A K Deshpande** Professor and HOD

**Cite this article:** Ch. Geetha, Farheen A, Deshpande AK. **Histopathologic study of Mucinous lesions of the appendix.** *IP Arch Cytol Histopathology Res* 2020;5(1):41-46.