



Original Research Article

Critical analysis of head and neck swelling with respect to cytomorphological diagnosis: A retrospective study

Nilam Bhasker^{1,*}, Meeta Pathak¹

¹Dept. of Pathology, Career Institute of Medical Sciences and Hospital, Lucknow, Uttar Pradesh, India



ARTICLE INFO

Article history:

Received 21-01-2020

Accepted 06-02-2020

Available online 18-03-2020

Keywords:

Cervical Lymph nodes

FNAC

thyroid

head and neck swellings

ABSTRACT

Introduction: Head and neck lesions are common as compared to other body lesions. In head and neck swellings- cervical lymph node swellings, thyroid swellings and salivary gland enlargement are included. Fine needle aspiration cytology (FNAC) is less invasive, cost effective, safe and satisfactory OPD procedure.

Aims and objective: To study the spectrum of lesions in head and neck in our semi urban area. And also assess the role of fine needle aspiration cytology in diagnosing the palpable head and neck swelling.

Materials and Method s: This retrospective study was conducted in department of pathology over a duration of 6 months on all age group patients in both sex male, female. This study had included total number of 392 patients with neck swelling in both kind of patients either indoor or outdoor. The fine needle aspiration cytology (FNAC) procedure was done in these patients with using 23 gauge needle and 20 ml disposable syringe for aspiration.

Results: The study included total number of 392 cases. FNAC revealed 247 cases (63.01%) of cervical lymph node in which non neoplastic lesions were in 146(59.11%) and malignant lesions were in 85(34.41%) cases in which metastatic carcinoma was common.

Conclusion: Fine needle aspiration cytology will be more helpful in neck swelling because of safe, cost effective and less painful comparatively biopsy. It can be easily performed in children and old age patients without giving anaesthesia.

© 2020 Published by Innovative Publication. This is an open access article under the CC BY-NC-ND license (<https://creativecommons.org/licenses/by/4.0/>)

1. Introduction

Head and neck swellings are very common in our country due to multiple etiological factors. The etiological factors of neck swellings are poor oral hygiene, hot spicy food, tobacco chewing, smoking, viral infections and due to metastasis also.¹⁻³

Palpable head and neck swelling include neoplastic / non-neoplastic lesions were categorised according to site with causes- (1) cervical lymph node swelling - granulomatous, reactive, lymphoma and metastasis. (2) thyroid swelling presents as goitre, cystic degeneration, thyroiditis, neoplasm or malignancy. (3) salivary gland lesions present as pleomorphic adenoma, benign lesion or

malignant lesion.⁴⁻⁶ Other than above soft tissue swelling- parasitic or cystic lesion are also common. FNAC is suitable for debilitated patients. We can also assess deeper lesion if image guided FNAC is available. it is non traumatic, inexpensive and also helpful to differentiate non-neoplastic from neoplastic lesions and avoid surgical intervention.

Non neoplastic lesions of head and neck swelling are very common compare to neoplastic. Clinically it is difficult to diagnosed head and neck swelling without applying any procedure- open biopsy or fine needle aspiration cytology.

Histopathology examination is a biopsy procedure under guidance of anaesthetist⁵ and performed only in operation theatre (OT). It is painful, costly, time taking procedure. Histopathology examination always have an upper hand on evaluation of any swelling and also no doubt it has diagnostic and therapeutic importance.⁷⁻⁹

* Corresponding author.

E-mail address: nilam2711@gmail.com (N. Bhasker).

On the other hand fine needle aspiration cytology (FNAC) is quick, safe, reliable, less painful, cost effective procedure and convenient bed side procedure and virtually no contraindication.^{10,11} Clinicians can also easily correlate their diagnosis.^{3,4} There are also drawback of FNAC-improper technique, inadequate material or less material to diagnose the case and occasionally micro metastasis also.¹²⁻¹⁴

2. Aims and Objectives

1. To study the spectrum of lesions in head and neck in our semiurban area.
2. To assess the role of fine needle aspiration cytology in diagnosing the palpable head and neck swelling.

3. Materials and Methods

This retrospective study was conducted in department of pathology. Patients of all age group were included in this study. This study included total number of 392 patients with neck swelling in both presented in either indoor or outdoor.

In head and neck swelling we included cervical lymph nodes, salivary glands, thyroid lesions and other neck swelling. Related to the patients swelling we noted down clinical details including age, occupation, fever, weight loss, pain on swallowing, duration occupation, history of chewing pan, gutkha, smoking etc.

We applied fine needle aspiration (FNA) procedure in all patients. We used 23 gauge needle and 20 ml disposable syringe for aspiration. After fixing the swelling with fixatives, we applied 2 to 3 passes with the help of needle. The smears were prepared and fixed in isopropanol. After the procedure, we fixed the smear and stained with haematoxylin and eosin (H&E).

A repeat procedure FNAC was applied in scanty or inadequate material.

Smears were evaluated for cellularity and morphology with background material.

4. Results

This retrospective study of head and neck swellings included total 392 cases and they were categorised according to their sex, age and origin. Head and neck lesions included inflammatory, benign, malignant, cystic and also paucicellular cases. Female patients(52.55%) were more in number compared to male patients (47.45%). (Table 1)

Table 1: Sex wise distribution of neck swellings

Sex	No. of cases	%
Male	186	47.45
Female	206	52.55
Total	392	

Table 2: Age wise distribution of neck swelling

Age	No. of cases	%
<10 years	20	5.1
10-30	134	34.18
30-50	121	30.86
50-70	98	25.0
>70	19	4.84
Total	392	

Table 2 Total number of 392 cases were distributed according to age wise. This study showed 10-30 years of age group patients were larger in number (34.18%) and >70 years and <10 years age group patients were lesser in number.

Table 3: Spectrum of cervical lymph node masses (N=247)

Lesions	No. of cases	%	
Reactive lymphoid hyperplasia	88	35.63	
Inflammatory	Non specific / Suppurative	04	1.62
	Granulomatous	54	21.86
Malignant	Lymphoma	07	2.83
	Metastasis	78	31.58
Paucicellular		16	6.48
Total	247	100	

Table 3 This retrospective study of head and neck swelling categorised cervical lymph node masses 247 according to lesions. Reactive lymphoid hyperplasia cases were highest in number 88(35.63%) followed by malignant lymph node lesions. In malignancy of cervical lymph node metastasis cases were 78(31.58%) followed by granulomatous inflammatory lesion 54(21.86%).

Table 4: Spectrum of thyroid lesions (N=113)

Lesions	No. of cases	%	
Benign nodular goitre(colloid goitre)	80	70.80	
Thyroiditis	08	7.08	
Hyperplastic nodule	11	9.74	
Follicular neoplasm	07	6.20	
Malignancy	Medullary carcinoma	03	2.65
	Metastasis	03	2.65
Paucicellular		01	0.88
Total	113	100	

Table 4 In this retrospective study, thyroid lesions 113 were categorised. Benign nodular goitre (colloid goitre) cases 80 (70.80%) were highest in number comparatively other thyroid lesions. Lesser number of cases are of follicular neoplasm 07(6.20%) and also paucicellular 01 (0.88%).

Table 5 This study also categorised cervical salivary glands lesions 12. There were large number of cases

Table 5: Spectrum of cervical salivary gland lesions (N=12)

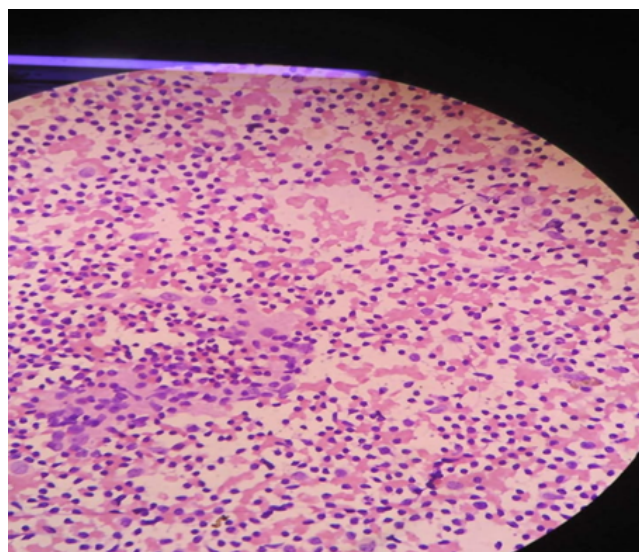
Lesions	No. of cases	%
Chronic sialadenitis	01	8.33
Non specific inflammation	02	16.67
Cystic lesions	02	16.67
Pleomorphic adenoma	06	50.0
In conclusive	01	8.33
Total	12	100

of pleomorphic adenoma with 06 cases (50.0%) followed by nonspecific lesions 02 (16.67%) and cystic lesions 02(16.67%).

Table 6: Spectrum of other neck lesions (N=20)

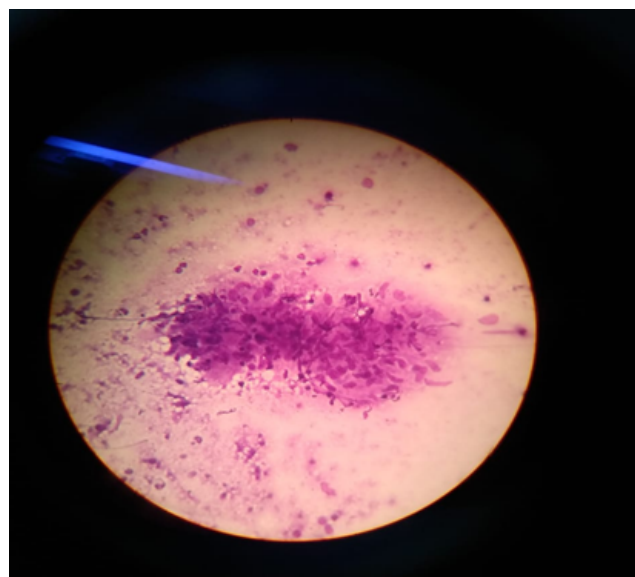
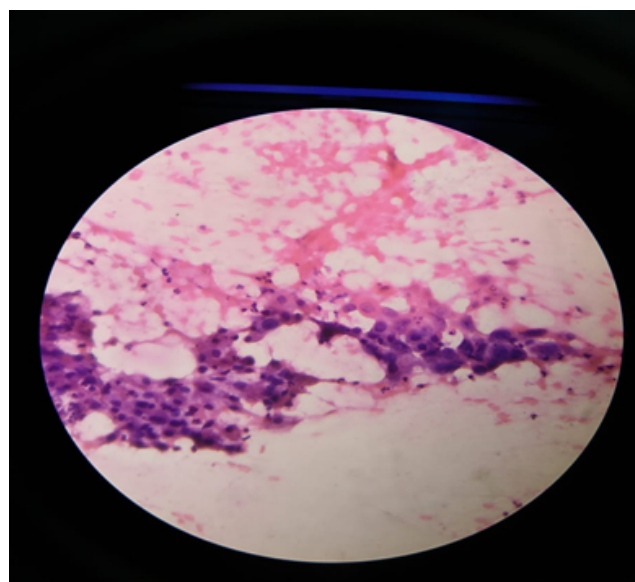
Lesions	No. of cases	%
Cyst hygroma	01	5.0
Non specific inflammation	09	45.0
Benign cystic lesions	08	40.0
Mucocoele	02	10.0
Total	20	100

Table 6 This study also included other than above head and neck lesions which were 20 in number. Non specific inflammatory lesions 09(45%) were highest in number followed by benign cystic lesions 08(40%).

**Fig. 1:** High power view (40x)-reactive lymphadenitis-cellular smear shows reactive population of lymphoid cells.

5. Discussion

This retrospective study was conducted in our centre. The research had included total number of 392 cases of neck swelling irrespective of the age group. Neck swelling is very common presentation in our centre. Fine needle

**Fig. 2:** High power view (40x)-granulomatous inflammation-cellular smear shows cluster of epithelioid cell granuloma in a background of mature lymphocytes.**Fig. 3:** High power view (40x)- metastatic squamous cell carcinoma- cluster of atypical cells having high nucleocytoplasmic ratio with abundant cytoplasm in a background of mature lymphocytes.

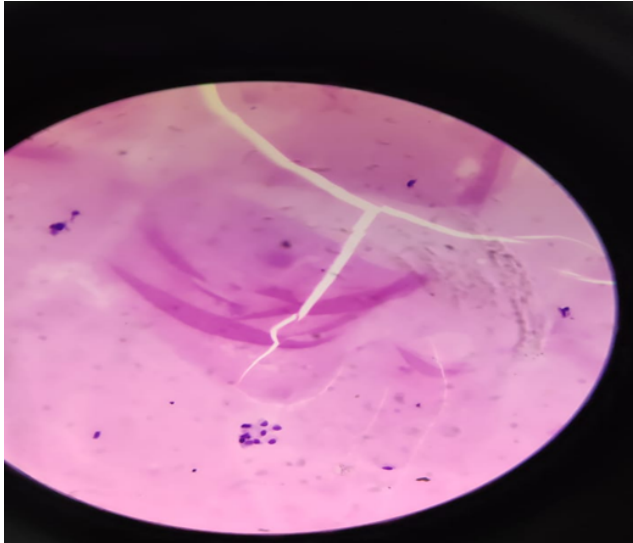


Fig. 4: High power view(40x)-colloid goitre- scattered follicular epithelial cells in a background of colloid.

aspiration cytology procedure was performed in all the cases by applying aspiration and non aspiration both kinds of technique.

Comparing to Jasmin H et al study in which 54 % were male, this study showed 52.5% female patients.¹⁵ N.Agarwal and Rathod GB study also noticed increased number of female patients.^{16,17}

The study included all age group patients in which between 10-30 years of age group patients were maximum (34.18%) and >70 years were lesser (4.84%). This results were almost same as N. Agrawal et al study.¹⁷

In this study we had taken total 392 cases in which 63% means 247 cases were of cervical lymph node swellings. Which included sub mandibular and submental lymph nodes, post auricular lymph node. Lymph node size were variable from 1 to 5 cm.

The study was compared to Ahmad T et al, Hag IA et al and Kamal F et al researches and we concluded that reactive lymphadenitis was commonest lesion in cervical lymph node swelling Figure 1.^{18–20} Lawrence et al found 59% cases and N. Agrawal found 28.57% cases of reactive lymphadenitis followed by granulomatous lymphadenitis^{17,21} because of various infections and poor hygiene. Many studies were done on granulomatous lymphadenitis.^{17,22} N.Agrawal study found 70 cases (25%) and Saira Fatima got 13.4% cases of tuberculous lymphadenitis. So our study was in between Saira and Agrawal study because the study found 54 cases of granulomatous lymphadenitis Figure 2 (21.86%). Comparing to the other study our findings were slightly different because 88 cases were of reactive lymphadenitis (35.6%) which was commonest lesion but second common lesion was metastatic carcinoma-78 cases Fig-3 (31.57%). N.Agrawal study found only 60 metastatic

carcinoma cases (21.43%).¹⁷ In another study of Jasani et al, metastasis constituted 11.3% of cases.¹⁵ In primary tumors of lymph node was lymphoma (malignancy) which was only 07(2.8%) cases comparatively to N.Agrawal study because they found 25 cases (8.93%) of lymphoma.¹⁷ So reactive lymphadenitis was commonest lesion in all study that was analyzed.

Next common site of neck swelling after lymph node is thyroid lesions in this study with 113(28.8%) cases. In our study nodular goitre was commonest lesion in 80(70.79%) cases of thyroid, in which colloid goitre findings was most common in 68(60.17%) cases Figure 4. N. Agrawal study of thyroid findings was very close to our findings (71.54%).¹⁷ Many of the study was performed in thyroid swelling and result showed some kind of variation.^{23,24} Another study detected 56.9% cases of nodular goitre²⁴ and that was almost same to Klemi et al findings that showed 57%cases of multinodular goitre.²⁴

Second common lesion was hyperplastic nodule in 11 cases of thyroid (9.73%) lesion while in other study lymphocytic thyroiditis was second common finding that encountered 16 cases (12.31%).¹⁷ Lymphocytic thyroiditis was third common finding in our study that included 08 cases (7.07%). Only 7 cases of follicular neoplasm was found in our study (6.19%) which was in contrast with the Tariq N et al research,²⁵ they detected 23.08 % cases of follicular neoplasm and close to other study of 7.69% cases.¹⁷ In this study primary malignancy and metastatic in 03-03 cases means malignancy (2.65%) and metastasis (2.65%) present in equal number of cases i.e. (3,3) that was to another study and they also searched out only 4 cases of malignancy (3.08%).¹⁷ So there are too much variation in thyroid lesions, may be because of dietary habit or in female patients or late investigation in low socioeconomic patients. But one thing is common in all study that colloid goitre was the commonest lesion in thyroid swelling.

In salivary gland lesions 12 cases (3.06%) were of pleomorphic adenoma (most common lesion) followed by cystic lesions and then sialadenitis. 06(50%) cases of pleomorphic adenoma was diagnosed and 02(16.76%) cases of cystic lesion followed by 01(8.3%) case of sialadenitis. Comparing to N.Agrawal study, in which sialadenitis was commonest lesion comprising (53.84%) in salivary gland lesion followed by pleomorphic adenoma (15.38%)¹⁷ while Evan RW study was in favour of our study.²⁶

Miscellaneous lesions of neck swelling comprising 20 cases (5.1%) which is least common lesion. Nonspecific lesion was commonest comprising of 09 cases (7.96%) followed by benign cystic lesion of 08 cases (7.07%). Our study is in contrast with N.Agrawal study, in their miscellaneous neck lesion benign cystic lesion was common in 26 cases (50%).¹⁷

6. Conclusion

From our study we came to know about the distribution and nature of various head and neck lesions. Most of the swellings occurring in the head and neck region are inflammatory in nature and affect females more commonly than males. Reactive lymphadenitis was the commonest inflammatory lesion; metastatic carcinoma was the most common malignancy whereas colloid goitre was the most common benign pathology observed in our study.

However, advanced studies are required for establishing a more accurate trend of occurrence of head and neck swellings.

Fine needle aspiration cytology will be more helpful in neck swelling because of safe, cost effective and less painful comparatively biopsy. It can be easily performed in children and old age patients without giving anaesthesia.

7. Source of funding

None.

8. Conflict of interest

None.

References

1. Popat CV, Vora D, Shah H. Clinico-pathological correlation of neck lesion - A study of 103 cases. *Int J Head Neck Sur.* 2010;4(2). doi:10.5580/450..
2. Mehrotra R, Singh M, Kumar D, Pandey AN, Gupta RK, et al. Age specific incidence rate and pathological spectrum of oral cancer in Allahabad. *Indian J Med Sci.* 2003;57:400–404.
3. Rahman MA, Biswas MMA, Sikder AM. Scenario of Fine Needle Aspiration Cytology of Neck Masses in a Tertiary Care Hospital. *J Enam Med Coll.* 2012;1(1):8–14.
4. Advani SK, Dahar A, Aqil S. Role of fine needle aspiration cytology (FNAC) in neck masses/ cervical lymphadenopathy. *Pak J Chest Med.* 2008;14(3):9–14.
5. Soni S, Pippal SK, Yashveer B, Srivastava P. Efficacy of fine needle aspiration cytology in diagnosis of neck masses ; 2010..
6. Slaughter DP, Majarakis JD, Southwick HW. Clinical Evaluation of Swellings in the Neck. *Surg Clin North Am.* 1956;36:3–9.
7. Khan AH, Hayat AS, Baloch GH, Jaffery MH, Soomro MA. Study on the role of fine needle aspiration cytology in cervical lymphadenopathy. *World Appl Sci J.* 2011;12:1951–1954.
8. Steel BL, Schwartz MR, Ramzy I. Fine needle aspiration biopsy in diagnosis of lymphadenopathy in 1,103 patients. Role, limitations and analysis of diagnostic pitfalls. *Acta Cytol.* 1995;39:76–81.
9. Hafez NH, Tahoun NS. Reliability of fine needle aspiration cytology (FNAC) as a diagnostic tool in cases of cervical lymphadenopathy. *J Egypt Natl Cancer Inst.* 2011;23(3):105–114.
10. Amedee RG, Dhurandhar NR. Fine-Needle Aspiration Biopsy. *Laryngoscope.* 2001;111:1551–1557.
11. Frable WJ, Frable MA. Thin-needle aspiration biopsy in the diagnosis of head and neck tumour. *Laryngoscope.* 1974;84:1069–1077.
12. Khajuria R, Goswami KC, Singh K, Dubey VK. Pattern of Lymphadenopathy on FNAC in Jammu. *JK Sci.* 2006;8:157–159.
13. Bibbo M, Nodes L. *Comprehensive Cytopathology.* USA: Saunders Company ; 1996.. p. 703–729.
14. Orell SR, Sterrett GF, Whitaker D. *Lymph Nodes, Fine Needle Aspiration Cytology.* India: Churchill Livingstone: Elsevier ; 1999.. p. 83–124.
15. Jasani JH, Vaishnani HV, Vekaria PN, Patel D, Shah YD, et al. RETROSPECTIVE STUDY OF FINE NEEDLE ASPIRATION CYTOLOGY OF HEAD AND NECK LESION IN TERTIARY CARE HOSPITAL. *Int J Biomed Adv Res.* 2013;4(4):253–253.
16. Rathod G, Parmar P. Fine needle aspiration cytology of swellings of head and neck region. *Indian Journal of Medical Sciences.* 2012;66(3):49–49. Available from: <https://dx.doi.org/10.4103/0019-5359.110896>. doi:10.4103/0019-5359.110896.
17. Agrawal N, Sharma HS, Hansrajani V. Study of Cervical Neck Masses and Role of Fine Needle Aspiration Cytology in Central India. *Ann Int Med Dental Res.* 2017;3(3):EN19–EN22.
18. Ahmad T, Naeem M, Ahmad S, Samad A, Nasir A. Fine Needle Aspiration Cytology and Neck Swellings in the Surgical Outpatients. *J Ayub Coll Abbottabad.* 2008;20:30–32.
19. Hag IA, Chiedozi LC, Reyess A, Kollur SM. Fine Needle Aspiration Cytology of Head and Neck Masses. Seven years experience in a secondary care hospital. *Acta Cytol.* 2003;47:387–392.
20. Kamal F, Niazl S, Nagi AH, Jaradi MA, Naveed IA. Fine Needle Aspiration Cytology (FNAC): An experience at King Edward Medical College. *Lahore Pak J Pathol.* 1996;7:33–39.
21. Lawrence C, Shara N. Study of Fine Needle Aspiration of Head and Neck Masses. *Acta Cytol;*47:387–392.
22. Fatima S. Spectrum of Cytological Findings in Patients with Neck Lymphadenopathy- Experience in a Tertiary Care Hospital in Pakistan. *Asian Pacific J Cancer Prev;*12:1873–1875.
23. Accurso A, Rocco N, Palumbo A, Leone F. Usefulness of Ultrasound-Guided Fine-Needle Aspiration Cytology in the Diagnosis of Non-Palpable Small Thyroid Nodules. *Tumori J.* 2005;91(4):355–357.
24. Klemi PJ, Nylamo JH, E. Fine Needle Aspiration Biopsy in the diagnosis of Thyroid Nodules. *Acta Cytol.* 1991;35:35–43.
25. Tariq N, Kher S, Sadiq S. Fine Needle Aspiration Cytology of Head and Neck lesions- An experience at the Jinnah Post Graduate Medical Centre. *J Otolaryngol.* 2007;23:3–65.
26. Evans RW, Cruickshank A. *Epithelial Tumours of the Salivary Gland.* vol. 1. Philadelphia; WBSaunders ; 1970..

Author biography

Nilam Bhasker Assistant Professor

Meeta Pathak Professor

Cite this article: Bhasker N, Pathak M. **Critical analysis of head and neck swelling with respect to cytomorphological diagnosis: A retrospective study.** *IP Arch Cytol Histopathology Res* 2020;5(1):58-62.