



## Original Research Article

## Diagnostic challenges of a spectrum of cases of Phaeohyphomycosis - A histopathological approach of rare dematiaceous (Melanized / pigmented) fungi

G Barathi<sup>1,\*</sup>, J Thanka<sup>1</sup>, Sai Shalini<sup>1</sup><sup>1</sup>Dept. of Pathology, Sri Ramachandra Institute of Higher Education and Research, Chennai, Tamil Nadu, India

## ARTICLE INFO

*Article history:*

Received 25-05-2020

Accepted 28-05-2020

Available online 11-06-2020

*Keywords:*

Chromoblastomycosis

Melanized fungi

Mycetoma

Phaeohyphomycosis

## ABSTRACT

**Background:** Dematiaceous fungi are a group of melanized fungi which imparts light to dark golden brown colour to the cell wall of these fungi on histopathological tissue sections (HPE). Due to lack of clinical suspicion and varied clinico-pathological presentation they are easily mistaken for any chronic swelling. The three common melanized fungi are phaeohyphomycosis, mycetoma, and chromoblastomycosis.

**Aim:** Our study aims at deriving an algorithm for diagnosing these fungi on HPE.

**Materials and Methods:** This is a retrospective study conducted on paraffin blocks of histopathology proven phaeohyphomycosis and mycetoma retrieved from the surgical pathology case files. Special stains for fungus were done for confirmation.

**Results:** Out of 34 cases 29 were phaeohyphomycosis and 5 were mycetoma which included both immunocompromised and immunocompetent patients. Interestingly it was observed that most of the cases presented with a trivial penetrating injury or a minor trauma. These melanized fungi were further distinguished on their clinical presentation and morphological features.

**Conclusion:** Because of their chronicity and localized lesion, most of the cases undergo surgical excision which itself is curative. Clinically and radiologically undiagnosed cases are primarily diagnosed on HPE after surgical excision in many cases. Hence a diagnosis of these melanized fungi on HPE needs an approach which would be beneficial to all practicing pathologists if they come across such rare cases.

© 2020 Published by Innovative Publication. This is an open access article under the CC BY-NC license (<https://creativecommons.org/licenses/by-nc/4.0/>)

### 1. Introduction

Dematiaceous fungi are a heterogeneous group of melanized fungi found ubiquitously in the environment. There are more than 60 genus and 100 species found worldwide.<sup>1</sup> Majority of the filamentous forms (moulds), and few yeast forms are pathogenic to humans. One common pathogenic factor is the presence of melanin pigment on their cell wall, which imparts light to dark golden brown colour to these fungi on HPE which is a characteristic distinguishing feature from other groups.<sup>2</sup> Hence the term melanized fungi are now preferred to dematiaceous fungi.<sup>3</sup> The three common melanized fungi are phaeohyphomycosis, chromoblastomycosis and mycetoma.<sup>4</sup> Unlike the other fungal infections, these dematiaceous fungi have an indolent

course and asymptomatic in their presentation. Clinically fungal infection was not thought as primary diagnosis in all these cases and hence in this article we tried to evaluate a simple algorithm of diagnostic approach which would be beneficial to all practicing pathologists if they come across such rare cases.

### 2. Materials and Methods

We could retrieve 34 cases of these rare fungi diagnosed in our department from 2011 to 2018. As a routine protocol for any suppurative lesion on H&E sections, we performed special stains for fungus like Periodic Acid Schiff (PAS), PAS-Diastase (PAS-D), Grocott's Methanamine Silver (GMS) and Acid fast Bacilli (AFB) for mycobacterium to demonstrate the microorganisms. Though we could diagnose pigmented fungi on H&E in many cases, we

\* Corresponding author.

E-mail address: [gbharathi@gmail.com](mailto:gbharathi@gmail.com) (G. Barathi).

did the above mentioned fungal stains for all the cases as per our standard operating procedure (SOP). Clinical data was obtained from the medical records department and lab investigation reports obtained from the local area network system in place.

### 3. Results

In this study there were 34 cases of dematiaceous fungi diagnosed on HPE. 29/34 is phaeohyphomycosis and 5 were mycetoma and we did not come across chromoblastomycosis in our study. Out of 34 patients there were 24 males and 10 females, age ranging between 13 and 75, predominantly seen in patients above 50 years of age. Ten of them were known diabetic. Six of them were post renal transplant patients. The various clinico-pathological presentations of the patients revealed the indolent course of the disease process, except for one case with cerebellar abscess and another case with suspected parietal SOL who presented to the emergency with vomiting, severe headache and difficulty in walking. All other patients presented to the surgical outpatient department for a chronic painless swelling or chronic sinusitis. Even in post transplant cases three had fungal sinusitis and the other 3 had cutaneous / subcutaneous lesions of the extremities requiring surgical excision only. Summary of clinico-pathological data of all 34 cases is given in Table 1.

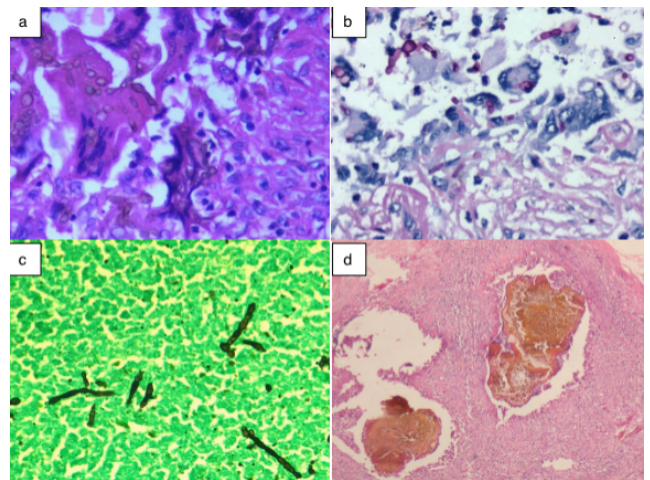
In patient with cerebellar abscess since they drained more pus, material was sent for AFB and fungal culture along with the HPE. Turnaround time for reporting for routine small biopsy specimen in our department is 2 days, so a critical alert was made when we saw these melanized fungi on H&E. Timely diagnosis helped the clinician to start an appropriate anti fungal regimen which saved the life of that patient. Mycology culture report after 2 weeks confirmed the growth of *Cladophialophora* species.

In our study we found subcutaneous and cutaneous as predominant presentation [23 cases], followed by 9 cases of sinusitis and 2 systemic cases in the form of cerebellar and cerebral abscess.<sup>5-7</sup> Except for couple of cases, fungal infection was not suspected clinically as was evident from the clinical diagnosis mentioned in the HPE request form.<sup>8</sup> Fourteen patients were immunocompromised and 20 were immunocompetent.

One common histopathological feature under microscopy that we observed in all cases of phaeohyphomycosis was a dense necroinflammatory tissue reaction comprising of aggregates of histiocytes lining the cyst wall in a palisading pattern along with numerous giant cells. Variably pigmented melanized fungi were seen lying freely and also within the giant cells lining the tissue. The characteristic morphological features of these fungi were, short hyphal forms [2-6µm] of varying length with infrequent branching and narrow band of constriction at the site of septations giving a beaded

appearance.<sup>9,10</sup> Some of them showed bulbous spores [globose or vesicular] at the end of the hyphae which is termed as terminal or intercalated vesicles by many authors. In all cases special stains confirmed the presence of fungi. [Figure 1]

In 5 cases of mycetoma, subcutaneous tissue showed multiple microabscesses with brown colour pigmented fungal colonies with Splendore Hoeppli phenomenon [deposition of amorphous, eosinophilic hyaline material around the fungal colonies]. The filamentous fungal hyphae showed vesicular bulbous ends [chlamydoconidia].<sup>11</sup> Focal giant cell reaction with reactive fibrosis and chronic inflammatory response surrounding the micro abscess was also seen.<sup>12</sup> In addition to the clinico-pathological data given in table 1 we also analyzed total count and differential count of all the patients. Clinical pathology reports were available for only 19 cases and 12 of that showed leukocytosis and Neutrophilia.



**Fig. 1:** a: - Brown coloured fungal spores and hyphae of phaeohyphomycosis within the giant cells H&E 400, b: - PAS stain showing bulbous spores X 400, c: - Silver stain highlighting the characteristic beaded appearance of hyphae X 400, d: - Fungal colonies of mycetoma H&E X40.

### 4. Discussion

Dematiaceous fungi otherwise called as ‘phaeoid molds’ are a heterogeneous group of melanized fungi, which are ubiquitous in nature and found worldwide in dust, soil, wood splinters and decaying vegetations.<sup>13</sup> Phaeohyphomycosis, chromoblastomycosis, and eumycotic mycetoma are some of the relatively common pathogenic melanized fungi. The term phaeohyphomycosis was proposed by Ajello et al in 1974.<sup>14</sup> The disease caused by this group of fungi is uncommon in clinical setting, but because of their ubiquitous nature and constant exposure to these fungi in the environment, there is an increased risk of acquiring this disease in both immunocompetent host and

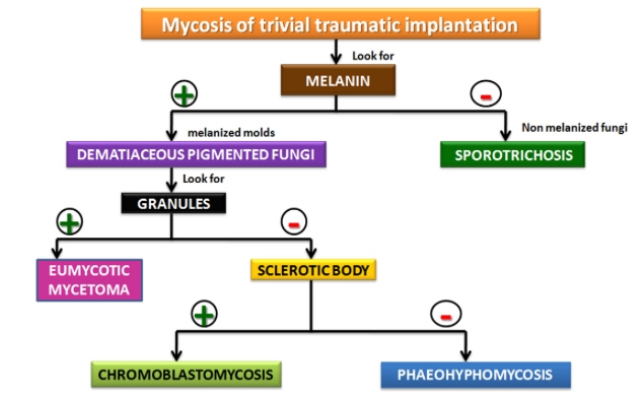
**Table 1:** Summary of Clinico-pathological data from 34 cases of dematiaceous fungi.

S.No	Age/ Sex	Clinical	Risk Factors	Presentation	Anatomical site of Lesion	Clinical Diagnosis	
1.	60/M			Difficulty in walking	DM	Left Cerebellum	Abscess
2.	54/M			Nasal Block	RT/DM	Maxillary Sinus	Sinusitis
3.	65/M			Bursitis	DM	Right ankle	Dermoid cyst
4.	65/M			Ulcer	DM	Left leg	Venous ulcer
5.	55/F			Swelling	NIL	Left Lower Limb	Lipoma
6.	50/F			Swelling	DM	Leg	Dermoid cyst
7.	51/F			Nasal bleed	RT	Maxillary sinus	Papilloma
8.	50/F			Nasal mass	RT	Left Maxillary sinus	Sinusitis
9.	52/M			Skin wart	RT	Finger	Verruca vulgaris
10.	55/M			Swelling	RT	Dorsum of foot	Histoplasmosis
11.	35/M			Chronic Ulcer	RT	Left foot	Non healing ulcer
12.	45/F			Skin lesion	NIL	Skin nodule	Topical eczema
13.	54/M			Nasal mass	NIL	Left nasal mass	Allergic polyp
14.	40/M			Swelling	NIL	Right foot	Ganglion cyst
15.	45/F			Lump	NIL	Right Toe	Bunion
16.	59/M			Swelling	NIL	Left wrist	Ganglion
17.	31/M			Sinusitis	NIL	Right maxilla	Osteomyelitis
18.	24/M			Sinonasal mass	NIL	Left maxilla	?Growth
19.	24/M			Nasal mass	NIL	Left maxilla	?Growth
20.	62/M			Pressure sore	NIL	Left Trochanter	Pseudo tumor
21.	58/F			Swelling	NIL	Left thigh	Abscess
22.	68/F			Swelling	DM	Left foot	Abscess
23.	53/F			Ulcer	NIL	Right foot	Venous ulcer
24.	75/M			Bursitis	NIL	Left Bursa	Bursitis
25.	52/M			Nasal mass	DM	Left maxilla	Sinusitis
26.	26/M			Swelling	NIL	Right Hip region	Sarcoma
27.	13/M			Vomiting	NIL	Right Parietal	SOL
28.	62/M			Swelling	DM	Right Ankle	Bursitis
29.	60/M			Swelling	DM	Left Leg and Hand	Sebaceous cyst
30.	41/F			Ulcer	NIL	Foot	Dermoid
31.	64/M			Swelling	NIL	Right foot	Non healing ulcer
32.	60/M			Swelling	NIL	Left Great Toe	Gout
33.	33/M			Swelling	DM	Right foot	? Madura foot
34.	60/M			Swelling	DM	Foot	Cellulites

S.NO 1 to 29 cases were diagnosed as Phaeohyphomycosis and 30 to 34 were diagnosed as Mycetoma on HPE. DM – Diabetes Mellitus, RT – Renal Transplant.

**Table 2:** Histological differences between the three key dematiaceous fungi.

Histological Feature	Phaeohyphomycosis	Eumycotic mycetoma	Chromoblastomycosis
<b>Macroscopy</b>	No granules	Black granules or grains [sulphur granules]	No granules
<b>Microscopy</b>			
• Pattern	Stellate abscess with palisading epithelioid histiocytes and giant cells.	Multiple abscesses extensive fibrosis, and formation of sinus tracts.	Mixed suppurative and granulomatous lesion
• Cells	Moniliform cells	Multicellular grains	Muriform cells
• Hyphae	Short closely septate hyphae [2-6 $\mu$ m] and budding yeasts	Broad septate fungal hyphae [2-6 $\mu$ m] or more	Round, thick walled, nonseptate hyphae [Sclerotic bodies] [5-12 $\mu$ m]
• Others	Characteristic constriction at the site of septation giving a beaded appearance to the fungi	Splendore Hoespli material borders the granules	Pseudoepitheliomatous hyperplasia of the overlying epidermis may be seen
• Melanin	Present [Light to dark golden brown]	Present [brown]	Present [Dark brown]



**Fig. 2:** Algorithm of histopathological approach to melanized fungi.

immunosuppressed patients.<sup>15,16</sup> Because of increasing immunosuppression either due to lifestyle diseases like diabetes or any other chronic infections and increased medical therapy, there are new species detected on culture by many referral mycology labs.<sup>17</sup>

Moreover depending on host susceptibility the clinical presentation may be varied and a common mode of infection in most of the cases would be a trivial penetrating injury or a minor trauma which may not be remembered by the patient. As the lesion is localized and chronic in nature, recalling the event by the patient is difficult to elicit in the history.<sup>18</sup> Because of their chronicity and insidious enlargement of swelling there is no clinical suspicion of these fungi, and most of the cases undergo surgical excision which itself is curative.<sup>19</sup> Since the excised specimen is sent in formalin for HPE, there would be no residual material for culture examination most of the time. Both clinically and radiologically undiagnosed cases are primarily diagnosed on HPE. In our study 32 out of 34 cases presented like a chronic swelling or sinusitis with a need of surgical excision as the first line of treatment. Hence it is the HPE which clinched the diagnosis and there was no material available for microbiology culture.

Melanized fungi are heterogeneous group of organism having in common melanin pigment on their wall. Since all of them have melanin on their wall the histomorphological differences between each other is important in distinguishing them on H & E sections. In our study we mainly had phaeohyphomycosis and few cases of mycetoma and did not come across chromoblastomycosis. We observed that most of our cases had lesion that is localized to the subcutaneous tissue commonly involving the exposed parts like feet, toes, fingers etc..., which are prone for injurious agents like splinters and thorns. A trivial injury triggers a granulomatous response in the host which is superadded with an acute suppurative reaction to the fungal antigen. Histological differences between the three dematiaceous fungi are given in the Table 2.

Melanin is the antigenic factor expressed by these fungi as a protective mechanism against the host immune system. Melanin is thought to offer protection from environmental stress such as radiation, extremes of temperature and hydrolytic enzymes thus enhancing the virulence and pathogenicity of some fungi. Presence of melanin may be the reason for their ubiquitous nature helping them to survive in the extraneous environment.<sup>20</sup>

Fungal melanin is dihydroxy-naphthalene [DHN] melanin which is located in the fungal cell wall synthesized via the pentaketide pathway. The difference between fungal melanin and the mammalian melanin is the presence of nitrogen in the later due to the DOPA [Dihydroxy phenylalanine] precursor. Dematiaceous fungi differ from some melanin containing fungal genera [e.g. Cryptococcus] in that they have DHN melanin whereas the later has mammalian type of melanin on their wall. Melanin binds to the hydrolytic enzymes preventing their action on fungal plasma membrane and also acts as a scavenger of free radicals, thus protecting fungi against U-V radiation. Hence melanized fungi are less susceptible than non-melanized fungi to killing by hypochlorite and oxygen and nitrogen derived radicals, thus melanin acting as a virulence factor.<sup>21</sup>

Another important concern about the presence of melanin in the fungal cell wall is that melanin reduces the effectiveness of certain antifungal agents by directly binding to them or by reducing the porosity by the closely spaced melanin granules, which prevents the larger molecules of drug particles from reaching their target sites. Though this group of fungi are subtle in their clinical presentation, this property of the fungal melanin against the antifungal agents especially in immunocompromised host may be lethal. Hence an HPE diagnosis of melanized fungi would help the clinician in choosing appropriate antifungal like azoles, that doesn't bind to the melanin so that these fungi are susceptible to this group of drugs.<sup>22</sup>

We know in general immunocompromised patients are more susceptible to opportunistic fungal infections. But there are certain host factors that allow immunocompetent persons to become victim of fungal infections. Some of the host factors responsible are extremes of age, burns, chronic respiratory diseases where there is a breach in the mucosal/cutaneous barrier mechanism, dialysis, diabetes [Neutropenia] and traumatic injury, suppression of humoral or cellular immune mechanism by any agents/drugs, Genetic polymorphism causing changes in innate immunity etc.<sup>23</sup> Leucopenia or neutrophil / monocyte phagocytic dysfunction may also contribute to the disturbance in host defence mechanism. Antibiotics may reduce even normal bacterial flora of the body that normally inhibit fungal overgrowth. Whenever there is an imbalance in this immune mechanism the fungal antigens easily gain entry into the host tissue and elicit granulomatous / suppurative reaction depending on the site of involvement. According to Folder

and McGinnis there are four groups of phaeohyphomycosis - Cutaneous / corneal [Keratitis], Subcutaneous, Sinusitis, and Systemic forms based on their location. In our study we came across all the four groups of these fungi.<sup>24,25</sup>

Why we emphasise on HPE as an important tool in diagnosis of this group of melanized fungi is, most of the lesions are misdiagnosed as chronic swelling and hence surgical excision is done completely without any residual material for microbiological culture.<sup>26</sup> Biochemical tests like nitrate and carbohydrate assimilation tests are nowadays done in some labs for certain group of fungi. Even molecular techniques using Polymerase Chain Reaction [PCR] and DNA hybridization are also available in some laboratories for specific genera, but not as a routine for dematiaceous fungi. But there is no simple diagnostic tests like routine serological examination or PCR methods available to identify infections due to these fungi in clinical laboratory partly due to their diversity and due to cross reactions with other fungal antigens like aspergillous galactomannan.

Fungal culture should be done for species identification whenever possible. We know that culture is more specific for species isolation, but HPE provides indisputable evidence of tissue invasion and therefore can confirm the pathogenic significance of a cultural isolate that belongs to the normal body flora or that is usually encountered as an environmental contaminant in culture. But HPE shows tissue invasion as hallmark of pathogenic fungi. HPE also confirms the coexistence of other fungi or protozoa/viruses [cytopathic effect or inclusions], so that appropriate therapy and management can be decided by the clinician especially in immunocompromised patients. The advantage of HPE over culture is the time taken for identification. Though we rely on culture only for species categorization a KOH mount would help in genus identification. Because management of one mycosis may be entirely different from that of another, clinician cannot wait for 2-6 weeks time for growth of fungi on culture media to confirm. With the help of HPE the pathologist must often play a key role in recognizing these melanized fungi and alert the clinician for commencement of appropriate antifungal treatment.<sup>27</sup>

Unless there is a strong suspicion of fungal infection during surgery the material is usually not sent to microbiology laboratory for KOH mount or mycology culture. If sent for culture the material is kept for up to 10 weeks before being discarded as negative. HPE shows 85% sensitivity on H&E sections and with GMS [silver stains] 100% sensitivity.<sup>28,29</sup> The role of HPE in this rare group of fungi is highlighted in this article and hence to make an awareness amongst the pathologist to carefully look into these subtle features on H&E in any microscopic suppurative lesion.

## 5. Conclusion

We discussed in this article in detail the varied clinical presentation, important host factors, histomorphological appearance and a diagnostic approach to this rare group of melanized fungi. Since these fungal infections are subclinical in presentation and was not suspected by clinician in most of the cases, and because of their subtle nature on histological examination, a careful search for these organisms by pathologist on HPE would help the treating physician in achieving appropriate treatment and prevent recurrence.

## 6. Source of Funding

None.

## 7. Conflict of Interest

None.

## References

1. Elias JA, Michael RM, Michael AP. Clinical mycology. New York: Churchill Livingstone Elsevier; 2009.
2. Reiss E, Shadomy HJ, Lyon GM. Fundamental Medical Mycology. Wiley-Blackwell; 2012.
3. Revankar SG. Dematiaceous fungi. *Mycoses*. 2007;50(2):91–101.
4. Revankar SG, Sutton DA. Melanized Fungi in Human Disease. *Clin Microbiol Rev*. 2010;23(4):884–28.
5. Baradkar VP, Mathur M, Kumar S. Phaeohyphomycosis of subcutaneous tissue caused by *Phaeoacremonium parasiticum*. *Indian J Med Microbiol*. 2009;27:66–9.
6. Kumar GN, Nair SP. Phaeohyphomycosis presenting as a solitary nodulocystic lesion in a renal transplant patient. *Indian Dermatol Online J*. 2015;6:359–61.
7. Revankar SG, Sutton DA, Rinaldi MG. Primary Central Nervous System Phaeohyphomycosis: A Review of 101 Cases. *Clin Infect Dis*. 2004;38(2):206–216.
8. Ziefer A, Connor DH. Phaeomycotic cyst. A clinicopathologic study of twenty-five patients. *Am J Trop Med Hyg*. 1980;29:901–11.
9. Tamboli S, Agashe S, Patil P. Phaeomycotic Cyst - A Case Report. *Indian Med Gazette*. 2011;p. 419–20.
10. Balamurugan S, Rajsekar, Rao R. Subcutaneous phaeohyphomycosis. *Indian J Pathol Microbiol*. 2009;52(3):454–5.
11. Manoharan NM, Shanmugam S, Veeriyar. A rare case of a subcutaneous Phaeomycotic cyst with a brief review of literature. *Malaysian J Med Sci*. 2011;18:78–81.
12. Shivamurthy A, Bhat ST, Jaiprakash P. Subcutaneous phaeomycotic cyst: a case report. *Our Dermatol Online*. 2014;5(3):273–5.
13. Fader RC, McGinnis MR. Infections caused by dematiaceous fungi: Chromoblastomycosis and phaeohyphomycosis. *Infect Dis Clin North Am*;2:925–38.
14. Ajello L, Georg LK, Steigbigel RT, Wang CJ. A case of phaeohyphomycosis caused by a new species of *Phialophora*. *Mycologia*. 1974;66:490–8.
15. Sheikh SS, Amr SS. Mycotic cysts: report of 21 cases including eight phaeomycotic cysts from Saudi Arabia. *Int J Dermatol*. 2007;46(4):388–92.
16. Garnica M, Nucci M, Queiroz-Telles F. Difficult mycoses of the skin: advances in the epidemiology and management of eumycetoma, phaeohyphomycosis and chromoblastomycosis. *Curr Opin Infect Dis*. 2009;22(6):559–63.
17. Radhakrishnan D, Jayalakshmi G, Madhumathy A, Banu S, Geethalakshmi S, Sumathi G, et al. Subcutaneous phaeohyphomycosis due to *Exophiala spinifera* in an immunocompromised host. *Indian J Med Microbiol*. 2010;28(4):396–9.

18. O'Donnell PJ, Hutt MS. Subcutaneous phaeohyphomycosis: a histopathological study of nine cases from Malawi. *J Clin Pathol* . 1985;38(3):288–92.
19. Kumar K, Hallikeri K. Phaeohyphomycosis. *Indian J Pathol Microbiol* . 2008;51(4):556–8.
20. Langfelder K, Streibel M, Jahn B, Haase G, Brakhage AA. Biosynthesis of fungal melanins and their importance for human pathogenic fungi. *Fungal Genet Biol*. 2003;38(2):143–58.
21. Nosanchuk JD, Casadevall A. Impact of Melanin on Microbial Virulence and Clinical Resistance to Antimicrobial Compounds. *Antimicrob Agents Chemother*. 2006;50:3519–28.
22. Revankar SG. Dematiaceous fungi: Chromoblastomycosis, Mycetoma, Phaeohyphomycosis. Antimicrobe, Infectious diseases and Antimicrobial agents. 2009;.
23. Ben-Ami R, Lewis RE, Raad II, Kontoyiannis DP. Phaeohyphomycosis in a Tertiary Care Cancer Center. *Clin Infect Dis*. 2009;48(8):1033–41.
24. Aranegui B, Feal C, García CP, Batalla A, Abalde T, Martínez AM, et al. Subcutaneous phaeohyphomycosis caused by *Exophiala jeanselmei* treated with wide surgical excision and posaconazole: Case report. *Int J Dermatol*. 2013;52:255–6.
25. Sutton DA, Rinaldi MG, Sanche SE, Dematiaceous, Elias JA, Michael RM, et al. Clinical mycology. New York: Churchill Livingstone Elsevier; 2009. p. 346–50.
26. Kimura M, Goto A, Furuta T, Satou T, Hashimoto S, Nishimura K, et al. Multifocal Subcutaneous Phaeohyphomycosis Caused by *Phialophora verrucosa*. *Arch Pathol Lab Med*. 2003;127:91–3.
27. Sharma NL, Mahajan V, Sharma RC, Sharma A. Subcutaneous phaeohyphomycosis in India - a case report and review. *Int J Dermatol* . 2002;41:16–20.
28. Kumar YS, Kurian N, Lawrence M, Vimal K, Teerthanath S. Rare Case of Fungal Osteoarthritis Caused by Phaeohyphomycosis. *J Clin Diagn Res*. 2012;6:888–9.
29. Vasoo S, Yong LK, Sultania-Dudani P, Scorza ML, Sekosan M, Beavis KG, et al. Phaeomycotic cysts caused by *Phoma* species. *Diagn Microbiol Infect Dis* . 2011;70:531–533.

### Author biography

**G Barathi** Assistant Professor

**J Thanka** Professor

**Sai Shalini** Associate Professor

**Cite this article:** Barathi G, Thanka J, Shalini S. **Diagnostic challenges of a spectrum of cases of Phaeohyphomycosis - A histopathological approach of rare dematiaceous (Melanized / pigmented) fungi.** *IP Arch Cytol Histopathology Res* 2020;5(2):120-125.