



Case Report

Somatic malignancy arising in growing teratoma syndrome – A case report

Jasmin Scaria¹, Geethu G Nair^{1,*}, Shali A S¹, Sathi P P¹

¹Dept. of Pathology, Govt. Medical College, Kozhikode, Kerala, India



ARTICLE INFO

Article history:

Received 07-05-2020

Accepted 30-05-2020

Available online 11-06-2020

Keywords:

Growing teratoma syndrome

Somatic malignancy

Squamous cell carcinoma

ABSTRACT

Growing teratoma syndrome (GTS) is a rare entity which presents as metastasizing large masses of mature teratoma during or after the course of chemotherapy of non seminomatous germ cell tumours of testis or ovary. Somatic malignancy arising in growing teratoma syndrome is much rarer. Patients with growing teratoma syndrome require close follow up as there is a risk for somatic malignancy. We report a case of squamous cell carcinoma arising in growing teratoma syndrome in her second recurrence. There is no documented such cases in the literature until now.

© 2020 Published by Innovative Publication. This is an open access article under the CC BY-NC license (<https://creativecommons.org/licenses/by-nc/4.0/>)

1. Introduction

Growing teratoma syndrome (GTS) is a rare entity which presents as metastasizing large masses of mature teratoma during or after the course of chemotherapy of non seminomatous germ cell tumours of testis or ovary. This clinical entity was first described by Carr et al in 1981 in testicular teratocarcinoma and the term GTS was coined by Logothetis et al in 1982.¹ Incidence of GTS vary from 1.9 to 7.6% of teratoma cases. 1-2% teratomas can undergo malignant transformation, commonest of which is squamous cell carcinoma (80%).² Malignancies have also been reported in 3% of GTS cases.³

2. Case Report

A 37-year-old unmarried female presented to our hospital in 2019 with complaints of dyspnoea on exertion, abdominal distension, loss of appetite and loss of weight for four months. On examination, patient had pallor and elevated JVP and a 15 x 12cm mass was noted in right hypochondrium, firm to hard with irregular borders. Also noted 2 x 2 cm soft mass lateral to left sternoclavicular joint. On ultrasound abdomen, it was a heteroechoic solid

and cystic lesion in relation to the right lobe of liver.

She had undergone total hysterectomy with bilateral salpingo-oophorectomy in 2001 and diagnosed histologically as immature teratoma ovary of right ovary, grade I with peritoneal gliomatosis. After the procedure, she received 2 cycles of chemotherapy with bleomycin, etoposide and paclitaxel. Later in 2009 she turned up with mature cystic teratoma of mediastinum for which excision was done. No significant biochemical abnormalities were noted at that time.

Current CECT showed metastatic mature cystic teratoma in right subdiaphragmatic region involving right hemidiaphragm and right lobe of liver with features of rupture of cyst into inferior aspect of right lobe of liver. Recurrent lesions were also noted involving bilateral adnexae, right costal pleura and right anterior chest wall (T2- T3 intercostal space). Possibility of growing teratoma syndrome was raised from these features.

Her blood investigations showed Hb: 8.1g/dl, Total count: 16000/mm³, Platelet: 7.46 lakhs/mm³. Her Liver function test was normal except for mild rise in ALP: 168 IU/L (20- 140). Other biochemical values were normal [LDH:525 IU/L (140 – 280), AFP: 0.8 ng/ml(10), β hCG : 7.4mIU/mL and CA 19.9 : 9.9U/ml].

* Corresponding author.

E-mail address: drgnair573@gmail.com (G. G. Nair).

Fine needle aspiration (FNA) of chest wall swelling was done. Studied smears showed sheets of benign epithelial cells, squamous cells, histiocytes and columnar cells in a background of keratinous material. Occasional foreign body giant cells were also noted. These features were consistent with that of mature cystic teratoma. FNA was attempted in liver lesion too, but was inconclusive. For confirmation, needle biopsy performed from the liver lesion. Sections studied showed an infiltrative neoplasm with squamous differentiation, which was p63 positive and TTF negative immunohistochemically. IHC for p53 was also done to confirm the malignant nature which was strongly positive. Thus diagnosis of squamous cell carcinoma arising from teratoma was confirmed. Since the lesion was inoperable, patient was offered palliative chemotherapy.

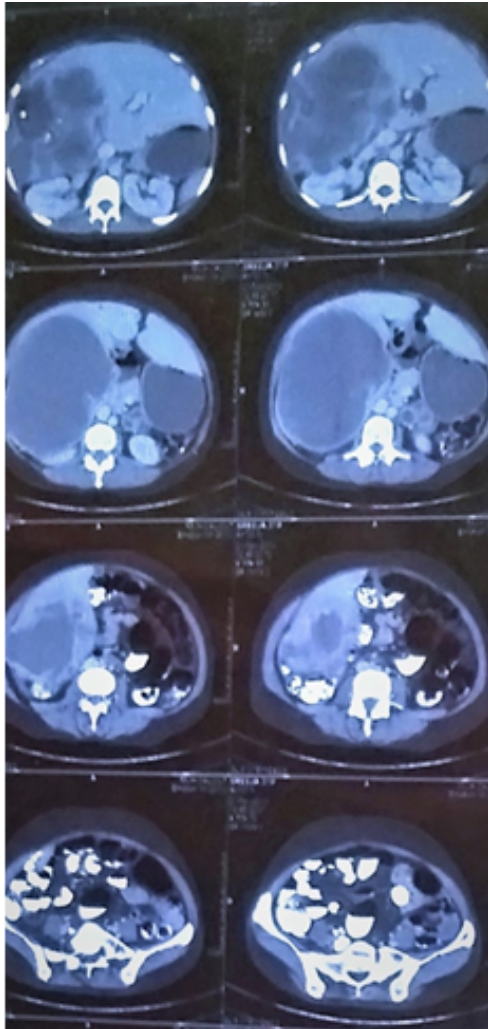


Fig. 1: CT abdomen showing heterogeneously enhancing lesion in liver

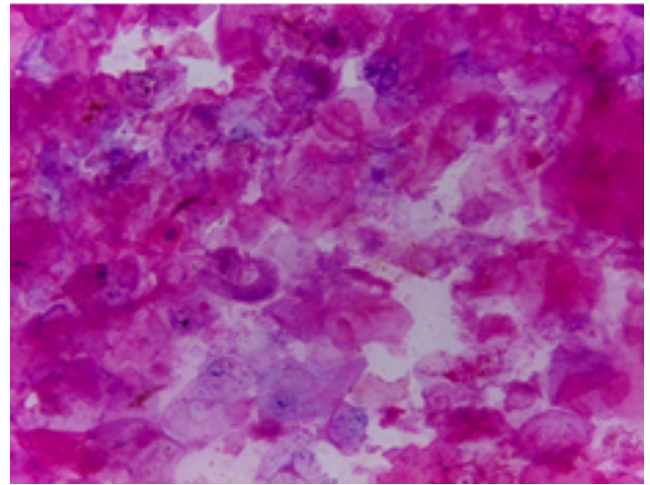


Fig. 2: Photomicrograph of FNA - chest wall swelling showing anucleate squamous cells (Papanicolaou stain: X 40)

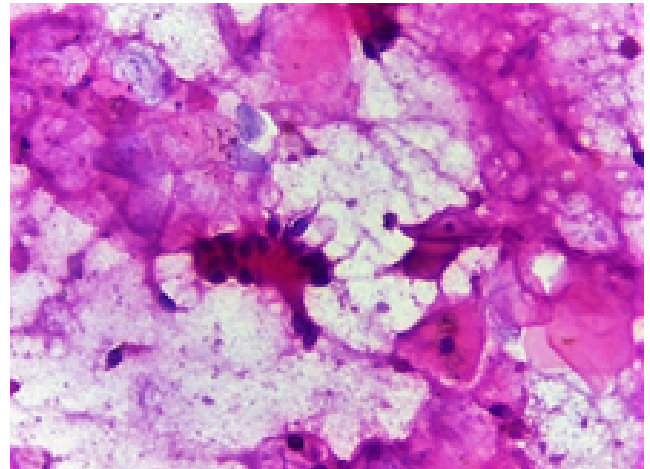


Fig. 3: Photomicrograph of FNA- chest wall showing columnar cells (Papanicolaou stain: X 40)

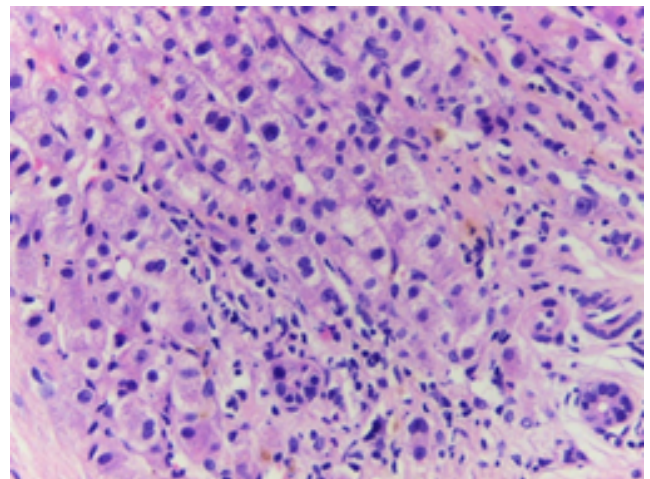


Fig. 4: Photomicrograph of liver biopsy showing normal hepatocytes (H & E: X 40)

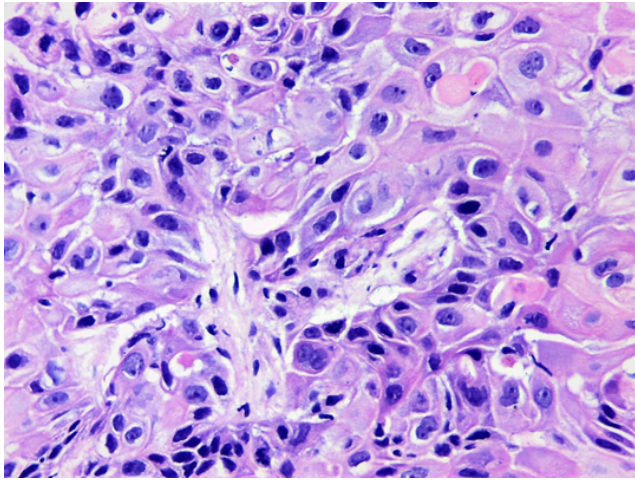


Fig. 5: Photomicrograph of liver biopsy showing infiltrating atypical squamous cells with keratinization (H & E: X 40)

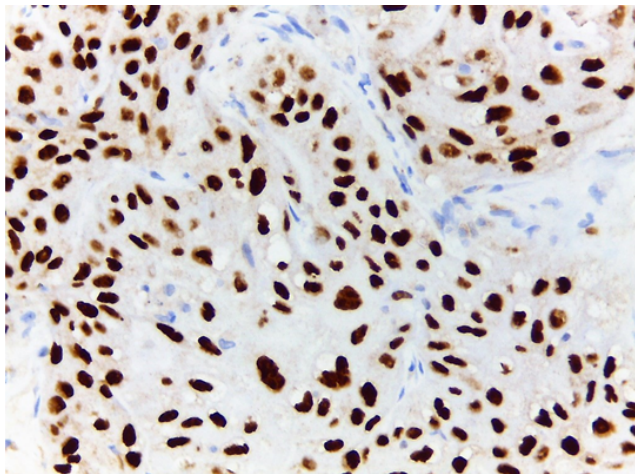


Fig. 6: Photomicrograph of liver biopsy showing nuclear positivity for p63 (IHC: X 40)

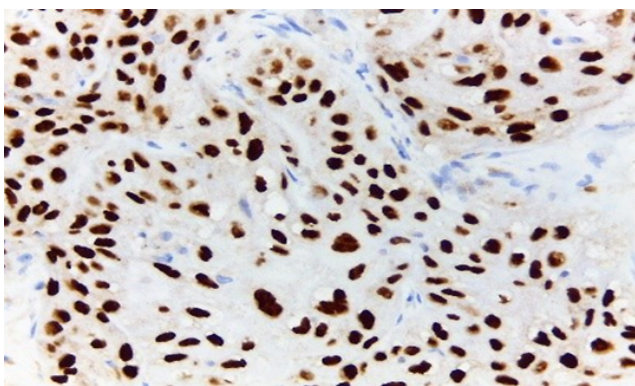


Fig. 7: Photomicrograph of liver biopsy showing nuclear positivity for p53 (IHC: X 40)

3. Discussion

The diagnosis of GTS should meet following 3 criteria which were evident in our case too:

1. History of definite diagnosis of non seminomatous germ cell tumour.
2. Normal tumour markers (AFP and HCG).
3. Radiological evidence of growing lesions during or after chemotherapy.

The diagnosis is confirmed by evidence of mature teratoma and absence of malignant germ cells in surgical pathology.⁴

Though the exact aetiology of GTS is not well understood, there are several postulations seen in several studies which are as follows:

1. Chemotherapy induced selective elimination of malignant cells with sparing of mature elements that eventually grow as migrating mature teratoma.
2. Chemotherapy induced evolution of malignant cells to benign tissues.
3. Spontaneous evolution of malignant cells to benign ones.¹

Development of GTS had been reported as early as 3 months and, in some cases, delayed till 12 years. Median time period is 26 months after chemotherapy. Median tumour size for developing GTS is 8.6cm. Retroperitoneum is the most common site. Also are pelvis, lung, inguinal lymph node, forearm, mesentery, brain and liver.¹ The initial histopathology is usually immature teratoma grade 2 or 3.³ A larger primary tumour (>10cm) also predispose to subsequent GTS.⁵

Somatic type tumours are rarely seen in, mature cystic teratoma. It accounts for approximately 2% of all cases. Only 7 cases are reported to have developed in immature teratoma. Squamous cell carcinoma accounts for 80% of cases of malignant transformation. Adenocarcinoma accounts for 7% of cases which arises from respiratory or gastrointestinal epithelium. Melanoma, carcinoid and neuroectodermal tumours were also reported. Risk factors for developing somatic malignancy in teratoma are age above 45 years, tumour size > 10cm, solid friable area of size \geq 2cm and requires prolonged contact between epithelium and cyst contents. Malignant transformation can also happen in GTS, but only in 3%. Common histological patterns are adenocarcinoma, sarcoma or primitive neuroectodermal tumour.³

Complete surgical excision is the treatment of choice in GTS which is resistant to chemo and radiotherapy. Five-year overall survival of GTS is 89%. Majority of mortality of GTS is related to postoperative complications. Recurrence rate with complete resection is 0 – 12.7% Incomplete resection recurrence rate is 72 – 83%. Regular follow up with CT scan is recommended 6 monthly for first year

and yearly thereafter for first 4 years.⁵ Squamous cell carcinoma arising in teratoma is having poor outcome. Early detection and complete surgical excision are crucial for patient survival. Limited number of cases for analysis makes it difficult to establish definite conclusion regarding treatment for this disease.⁶

4. Conclusion

Our patient is a 37-year-old female who developed squamous cell carcinoma in hepatic teratoma of growing teratoma syndrome which is not reported till yet. She had immature teratoma of ovary Grade I. After 8 years following chemotherapy, she developed GTS ie in mediastinum. Other fact which makes this case interesting is that patient developed malignant transformation in second recurrence.

5. Source of Funding

None.

6. Conflict of Interest

None.

References

1. Abdulraheem EA, Sait MK, Sait KH, Anfinan NM, Elkadi OR. <p>Growing teratoma syndrome with porta hepatis involvement – a case report</p>. *Int J Clin Pathol Diagn*. 2019;11(2):75–8.

2. Nair I, Anupama R, Chaya P, Sarala S. Somatic Tumors Arising in Ovarian Teratomas-Experience from an Oncology Center in South India. *Int J Clin Pathol Diagn*. 2019;2.
3. Kikawa S, Todo Y, Minobe S, Yamashiro K, Kato H, Sakuragi N. Growing teratoma syndrome of the Ovary: A case report with FDG - PET findings. *J Obstet Gynaecology Res*. 2011;37(7):926–32.
4. Üstün M, Karaca AC, Yoldaş T, Sezer TÖ, Çalışkan C. Growing Teratoma Syndrome: A Report of a Rare Case with a Detailed Review of the Literature. *World J Surg Surg Res*. 2018;1(1).
5. Saso S, Galazis N, Iacovou C, Kappatou K, Tzafetas M, Jones B, et al. Managing growing teratoma syndrome: new insights and clinical applications. *Future Sci OA*. 2019;5(9):FSO419.
6. Chiang AJ, Chen MY, Weng CS, Lin H, Lu CH, Wang PH, et al. Malignant transformation of ovarian mature cystic teratoma into squamous cell carcinoma: a Taiwanese Gynecologic Oncology Group (TGOG) study. *J Gynecol Oncol*. 2017;28(5):69.

Author biography

Jasmin Scaria Junior Resident

Geethu G Nair Assistant Professor

Shali A S Assistant Professor

Sathi P P Professor and HOD

Cite this article: Scaria J, Nair GG, Shali A S , Sathi P P . **Somatic malignancy arising in growing teratoma syndrome – A case report.** *IP Arch Cytol Histopathology Res* 2020;5(2):169-172.