



## Original Research Article

## Oral Lichen Planus in Kashmiri Population-a clinical prospective study

Altaf Hussain Chalkoo<sup>1</sup>, Tauseefa Jan<sup>1,\*</sup>, Bashir Ahmad Wani<sup>1</sup>, Rayees Ahmad Sheikh<sup>1</sup><sup>1</sup>Department of Oral Medicine and Radiology, Government Dental College, Srinagar, Jammu and Kashmir, India

## ARTICLE INFO

## Article history:

Received 27-06-2020

Accepted 18-08-2020

Available online 20-10-2020

## Keywords:

Greenspan syndrome

Wickham striae

Nikolsky's sign

## ABSTRACT

**Objectives:** The purpose of this clinical prospective study was to determine the location, clinical presentation, and gender distribution of oral lichen planus patients attending the department of oral medicine and radiology, Government dental college Srinagar in Kashmiri population.

**Materials and Methods:** This prospective clinical study included 200 patients reported to the Department of Oral Medicine and Radiology, Government Dental College Srinagar, with the clinical and pathological diagnosis of OLP. Data was compiled for each case, documenting information relating to age, gender, medication, habits (smoking, oral hygiene), anamnesis (reason for consultation, symptomatology, evolution).

**Results:** Out of 200 patients, 116 (58%) were females and 84 (42%) were males indicating higher prevalence of OLP in females. Buccal mucosa being the most common site affected in 132 patients (66%), followed by tongue in 46 patients (23%) and the least frequent involved site was palate in 2 patients (1%). The most common clinical presentation was of reticular type in 128 patients (64%), and the least common was bullous type in 3 patients (1.5%).

**Conclusion:** Lichen planus is one of the mucocutaneous disorders which involve skin, scalp, nails and oral mucosa. Lichen planus of skin is known as cutaneous lichen planus that is characterized by most common symptoms of pigmented cutaneous lesions which are pruritic. For a general practitioner it is very important to know the important clinical features, diagnosis and treatment plan for this disease in order to differentiate it from other mucocutaneous lesions and to educate the patient about the premalignant nature of disease.

© 2020 Published by Innovative Publication. This is an open access article under the CC BY-NC license (<https://creativecommons.org/licenses/by-nc/4.0/>)

## 1. Introduction

Lichen planus is a chronic inflammatory, autoimmune, mucocutaneous disease of unknown etiology. The word lichen planus is derived from Greek word “lichen” means tree moss and “planus” means flat.<sup>1</sup> In Indian population the prevalence of oral lichen planus is 2.6% with female preponderance.<sup>2</sup> The malignant transformation rate of OLP is 0.5% to 2% and is considered to be a potentially malignant lesion.<sup>3</sup> The mean age of OLP onset is the fifth decade of life, and there is a gender predilection with a female/male ratio of 2 to 3:1.<sup>4</sup> The lesions may be single, or multiple, unilateral or bilateral. Lichen planus involving skin is the cutaneous counterpart of OLP affecting

stratified squamous epithelium. Oral lesions are distributed symmetrically and bilaterally and appear as white streaks with radiating lines on erythematous areas. Buccal mucosa is the most common affected site, tongue, and gingiva, floor of mouth, palate are the other common sites affected by OLP.<sup>5</sup> The exact etiology is not known, certain factors which are considered to be etiological factors include.<sup>6</sup>

1. Autoimmunity: As OLP is itself an autoimmune disease, it may occur as an isolated finding or may occasionally be associated with other autoimmune disorders such as primary biliary cirrhosis, chronic active hepatitis, ulcerative colitis, myasthenia gravis, and thymoma.<sup>7</sup>
2. Immunodeficiency

\* Corresponding author.

E-mail address: [tauseefa110364@gmail.com](mailto:tauseefa110364@gmail.com) (T. Jan).

3. Food allergies: Food and some of food additives such as cinnamon aldehyde may act as allergen and have been found to be associated with OLP.<sup>8</sup>
4. Stress: Some of the studies in literature reveal the role of the psychological stress in the etiology of OLP.<sup>9</sup>
5. Trauma: Trauma like tooth brush trauma, cheek biting as such has not been quoted as an etiological factor in LP, although it may be the mechanism by which other etiological factors exert their effects.<sup>10</sup>
6. Diabetes, hypertension Studies have revealed that both diabetes mellitus (DM) and high blood pressure are associated with OLP<sup>11–13</sup> (Greenspan syndrome: Triad of DM, hypertension and OLP)
7. HCV: Detection of HCV RNA in the mucosal lesions of patients with OLP and the presence of HCV-specific CD4+ and CD8+ T lymphocytes in OLP lesions suggest that epithelial cells expressing HCV antigens may be targets for the immunopathogenesis of OLP.<sup>14</sup>

The cutaneous form of lichen planus presents with lesions that can be described as purplish, polygonal, planar, pruritic papules and plaques (6 p's). These skin lesions mostly occur on the flexor surfaces of the legs and arms, especially the wrists. The nail beds may also be involved, with ridging, thinning and subungual hyperkeratosis. Scalp involvement, if untreated, can lead to scarring and permanent hair loss.<sup>15</sup>

OLP may present in six forms as:<sup>16</sup>

### 1.1. Reticular

A fine, asymptomatic inter-wined lace-like pattern called "Wickham striae" in a bilateral symmetrical form and involves the posterior mucosa of the cheek in most cases is the characteristic feature of OLP. This is the most common clinical form of this disease (Figure 1a).

### 1.2. Erosive

A symptomatic lesion characterized by fine radiant keratinized striae with a network appearance surrounding an erythematous central zone of lesion. This is the most significant form of the disease (Figure 1 b).

### 1.3. Papular

This form is rarely observed and is normally in present with other forms of OLP. It presents with small white papules with fine striae in its periphery (Figure 1c).<sup>17</sup>

### 1.4. Atrophic

It exhibits diffuse red lesions and it may resemble the combination of two clinical forms, such as the presence of white striae characteristic of the reticular type surrounded by an erythematous area.<sup>17</sup>

### 1.5. Plaque

A whitish homogeneous patch similar to leukoplakia, mainly involving the dorsum of the tongue and the buccal mucosa. (Figure 1d).<sup>17</sup>

### Bullous

It is the most unusual clinical form, characterized by formation of blisters that gradually increases in size and tend to rupture, leaving the surface painful and ulcerated surrounded by fine radiating striae of reticular type . Nikolsky's sign may be positive. (Figure 1e)

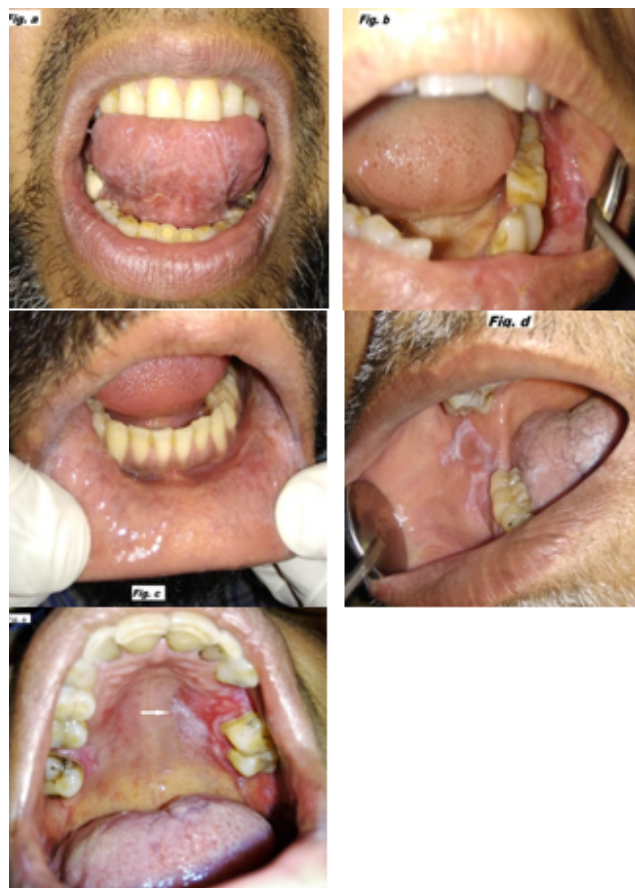

Fig. 1: 1a-e

The aim of this study was to determine the gender distribution, location, clinical presentation of oral lichen planus in Kashmiri population.

## 2. Materials and Methods

This prospective clinical study included 200 patients reported to the Department of Oral Medicine and Radiology, Government Dental College Srinagar. Diagnosed cases were taken for study. Diagnosis is made on the basis of clinical and histopathological criterias. The study included both males and females with age range of 16-65 years. The lowest age was 16 year old female. Van der Meij et

al. in 2003 proposed diagnostic criteria for identifying the cases of OLP which is based on the WHO definition of OLP. These included clinical as well as histopathological features.<sup>18</sup>

1. The clinical criteria included the presence of bilateral, mostly symmetrical lesions, presence of lace-like network of slightly raised white lines (reticular pattern), erosive, atrophic, bullous, and plaque type lesions.
2. Histopathological criteria included hypergranulosis, parakeratosis, acanthosis, “liquefaction degeneration” of cells within the basal layer and presence of lymphohistiocytic infiltrate in a band-like pattern at the level of papillary dermis and absence of epithelial dysplasia.<sup>11</sup>

Type of the lesion (reticular, erosive, bullous, and plaque), location of lesions, clinical presentation, age of the patient, gender, skin involvement were the criterias included in the study.

### 2.1. Exclusion criteria

1. Oral lichenoid contact lesions [OLCL], most commonly in areas which are in direct contact to dental restorative materials (allergic contact stomatitis in oral cavity) and in skin known as contact dermatitis like allergic reaction to latex gloves.
2. Oral lichenoid drug reactions [OLDR], which arise in response to use of some medications [e.g. oral hypoglycaemic agents and angiotensin-converting enzyme inhibitors].

## 3. Results

There were 200 patients of OLP with age range of 16 to 65 years, out of which 116 (58%) were females and 84(42%) were males indicating higher prevalence of OLP in females. Figure 2 shows gender distribution of OLP with higher prevalence in females.

Various sites of oral cavity involved by OLP include buccal mucosa, tongue, gingiva, floor of mouth, labial mucosa and palate. The most frequent site involved was buccal mucosa 132 (66%) out of 200 cases followed by tongue 46(23%) and the least frequent involved site was palate 2(1%). Table 1 shows the site wise distribution of OLP in males and females.

The various clinical presentation of OLP include reticular, erosive, plaque or bullous. The most common clinical presentation was of reticular type in 125 cases (64%), followed by erosive in 59 cases (29.5%), plaque in 12 cases (6%) and the least common was bullous type in 4 cases (2%). Figure 3 shows the distribution of OLP on the basis of clinical presentation.

Table 2 shows association of OLP with systemic disease like hypertension, diabetes and hypothyroidism.

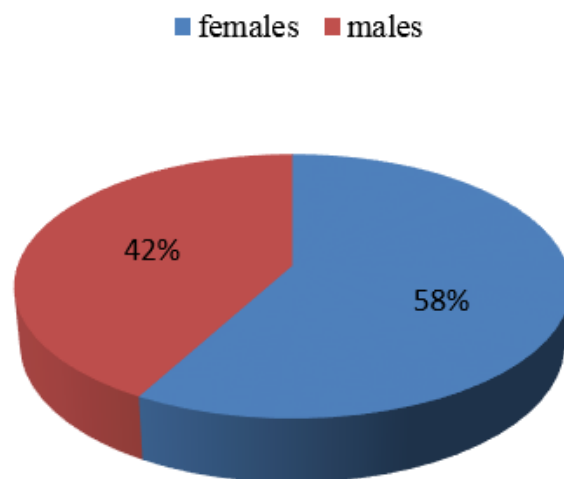


Fig. 2: Shows gender distribution of OLP

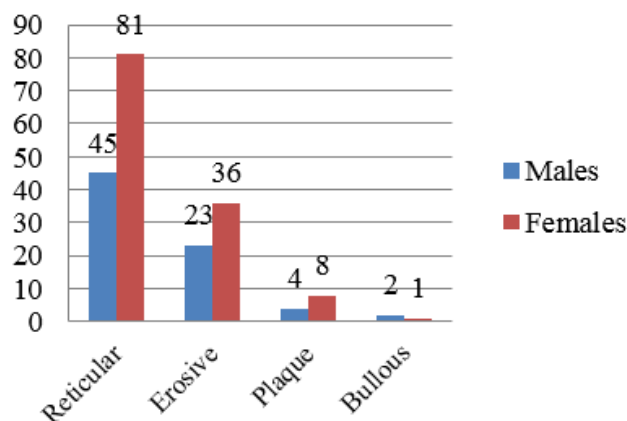


Fig. 3: Various clinical presentation of OLP

## 4. Discussion

The pathogenesis of Lichen planus is believed to result from an abnormal T-cell-mediated immune response in which basal epithelial cells are recognized as foreign because of changes in the antigenicity of their cell surface.<sup>19</sup> OLP is considered to be a counter- part of hypersensitivity-mediated disease. Molecular mimicry and epitope spreading are two mechanisms by which hypersensitivity reaction recognizes normal host cells as foreign. Exogenous substance triggers an immune response against the host antigens by phenomena of molecular mimicry. When there is present molecular similarity between self- antigen and exposed foreign peptide, auto-reactive T lymphocyte can be activated, thereby destroying even the self- antigen.<sup>20</sup> In hypersensitivity-induced lichen planus lesions, foreign antigenic peptides which resemble MHC-derived peptides and self- antigens in presence of preexisting inflammation

**Table 1:** Showing site wise distribution of OLP in males and females

Site	Males	Females	Total
Buccal mucosa	33	46	79(39.5%)
Buccal mucosa+ Tongue	17	21	38(19%)
Buccal mucosa + Tongue + Gingiva	10	11	21(10.5%)
Buccal mucosa + Gingiva + Labial mucosa	8	12	20(10%)
Buccal mucosa + Tongue + Gingiva + Labial mucosa	6	10	16(8%)
Buccal mucosa + Tongue + Floor of mouth	5	9	14(7%)
Buccal mucosa + Retromolar area	4	6	10(5%)
Buccal mucosa + Palate	1	1	2(1%)
Total	84(42%)	116(58%)	200(100%)

**Table 2:** Showing association of OLP with systemic diseases

System Disease	Females	Males	Total
Hypertension	18	30	48
Diabetes	19	25	44
Hypothyroidism	36	26	52

can break immunological self-tolerance when presented to T lymphocyte. A pathogen-specific immune response develops which cross-reacts with host structures, thereby causing tissue destruction. In lichen planus, along with exogenous antigenic peptides, the self- antigenic peptides (basal cell keratinocytes) could be presented to CD8+ cytotoxic T cells by antigenic mimicry mechanism at the expense of hypersensitivity reactions. Development of self-reactive T cell expansion known as epitope spreading can cause tissue damage by host antigenic determinants.<sup>21</sup> Damage in basal cell keratinocyte could result in epitope spreading causing tissue damage in lichen planus.

The data presented in this study was consistent with data from previous OLP studies in regard to location of lesion, symptoms, clinical presentation, disease chronicity, and medical history. After the diagnosis of OLP, according to the clinical and histopathological criteria of the WHO, the results of this study revealed that OLP was seen in middle-aged patients, with sex predilection for females, and it involved buccal mucosa bilaterally in symmetrical distribution, gingiva and tongue. In most of the studies done in different parts of the world a female predominance was reported.<sup>22</sup> In the present study, Burning sensation on taking spicy foods was observed in patients in the form of pain and soreness.<sup>23</sup> Reticular type was the most common clinical presentation followed by erosive type and the less frequent were plaque and bullous form of OLP. Bilateral symmetrical involvement of buccal mucosa was consistent with the findings of previous literature.<sup>22</sup> OLP involving gingiva was associated with clinical presentation of desquamative gingivitis. In addition, the symptoms of OLP may be aggravated by heat and other irritants in smoking and alcohol.<sup>24</sup> In the present study lichen planus was significantly more prevalent among women as compared to men. This is in agreement with findings

from previous studies.<sup>25–27</sup> According to the findings by Pindborg and coworkers,<sup>28</sup> who reported absence of a sex predominance and Ikeda and coworkers<sup>29</sup> who found lichen planus only in women. The reticular form is most common in this study (64%), and this is in accordance with findings from general population.<sup>30–32</sup> The most common site affected by OLP is buccal mucosa. Pindborg and coworkers<sup>27</sup> registered 84.3% of all lesions located to the buccal mucosa, Salem<sup>27</sup> found lesions in this location in 86% of the cases, Silverman<sup>33</sup> found in 79% of the cases and Bagan<sup>30</sup> in 88.2% of the cases. These figures are consistent with the findings in the present study as buccal lesions were found among 66 % of the individuals with oral lichen planus.

Provisional diagnosis of this disease is based on the symptoms and typical clinical presentation of oral lesions, skin and nail lesions and final diagnosis is based on histopathological features. Biopsy is the recommended procedure to differentiate it from other lesions.

## 5. Conclusion

Lichen planus is one of the mucocutaneous disorder in which oral involvement precedes the appearance of other symptoms or lesions at other locations. As oral lichen planus is a premalignant lesion of oral cavity with a malignant potential of 0.5% - 2%, it is very essential for a general practitioner to know the important clinical features, diagnosis and treatment plan for this disease so to differentiate it from other lesions and educate the patient about the malignant transformation of disease.

## 6. Source of Funding

None.

## 7. Conflict of Interest

None.

## References

- Farhi D, Dupin N. Pathophysiology, etiologic factors, and clinical management of oral lichen planus, part I: facts and controversies. *Clin Dermatol*. 2010;28(1):100–8.
- Murti PR, Daftary DK, Bhonsle RB, Gupta PC, Mehta FS, Pindborg JJ, et al. Malignant potential of oral lichen planus: observations in 722 patients from India. *J Oral Pathol Med*. 1986;15(2):71–7.
- Mattsson U, Jontell M, Holmström P. Oral Lichen Planus and Malignant Transformation: Is a Recall of Patients Justified? *Crit Rev Oral Biol Med*. 2002;13(5):390–6.
- Ismail SB, Kumar SKS, Zain RB. Oral lichen planus and lichenoid reactions: etiopathogenesis, diagnosis, management and malignant transformation. *J Oral Sci*. 2007;49(2):89–106.
- Sugerman PB, Savage NW. Oral lichen planus: causes, diagnosis and management. *Aust Dent J*. 2002;47:290–7.
- Roopashree MR, Gondhalekar RV, Shashikanth MC, George J, Thippeswamy SH, Shukla A, et al. Pathogenesis of oral lichen planus - a review. *J Oral Pathol Med*. 2010;39(10):729–34.
- Abbate G, Foscolo AM, Gallotti M, Lancellata A, Mingo F, et al. Neoplastic transformation of oral lichen: Case report and review of the literature. *Acta Otorhinolaryngol Ital*. 2006;26:47–52.
- Scully C, Beyli M, Ferreiro MC, Ficarra G, Gill Y, Griffiths M, et al. Update On Oral Lichen Planus: Etiopathogenesis and Management. *Crit Rev Oral Biol Med*. 1998;9(1):86–122.
- Eltawil M, Sediki N, Hassan H. Psychobiological aspects of patients with lichen planus. *Curr Psychiatr*. 2009;16:370–80.
- Scully C, Beyli M, Ferreiro MC, Ficarra G, Gill Y, Griffiths M, et al. Update On Oral Lichen Planus: Etiopathogenesis and Management. *Crit Rev Oral Biol Med*. 1998;9(1):86–122.
- Torrente-Castells E, Figueiredo R, Berini-Ayres L, Gay-Escoda C. Clinical features of oral lichen planus. A retrospective study of 65 cases. *Med Oral Patol Oral y Cirugia Bucal*. 2010;15:e685–90.
- Albrecht M, Bănóczy J, Dinya E, Tamás G. Jr Occurrence of oral leukoplakia and lichen planus in diabetes mellitus. *J Oral Pathol Med*. 1992;21:364–6.
- Ahmed I, Nasreen S, Jehangir U, Wahid Z. Frequency of oral lichen planus in patients with noninsulin dependent diabetes mellitus. *J Pak Assoc Derm*. 2012;22:30–4.
- Pilli M, Penna A, Zerbini A. Oral lichen planus pathogenesis: a role for the HCV-specific cellular immune response. *Hepatology*. 2002;36:1446–52.
- Katta R. Lichen. Lichen planus. *Am Fam Physician*. 2000;61(11):3319–28.
- Andreasen JO. Oral lichen planus. 1. A clinical evaluation of 115 cases. *Oral Surg Oral Med Oral Pathol*. 1968;25:31–42.
- Canto AM, Müller H, Freitas RR, Santos PS. Oral lichen planus (OLP): Clinical and complementary diagnosis. *An Bras Dermatol*. 2010;85:669–75.
- van der Meij EH, Schepman KP, van der Waal I. The possible premalignant character of oral lichen planus and oral lichenoid lesions: a prospective study. *Oral Surg Oral Med Oral Pathol Oral Radiol Endod*. 2003;96:164–71.
- Sapp JP, Eversole LR, Wysocki GP. Contemporary oral and maxillofacial pathology. St. Louis (MI: Mosby; 1997.
- Acharya S, Shukla S, Mahajan SN, Diwan SK. Molecular mimicry in human diseases: phenomena or epiphenomena? *J Assoc Physicians India*. 2010;58:163–8.
- Tchernev G, Orfanos CE. Antigen mimicry, epitope spreading and the pathogenesis of pemphigus. *Tissue Antigens*. 2006;68(4):280–6.
- Ingafou M, Leao JC, Porter SR, Scully C. Oral lichen planus: a retrospective study of 690 British patients. *Oral Dis*. 2006;12(5):463–8.
- Biocina-Lukenda D, Vidović-Juras D. Oral lichen planus: a retrospective comparative study between Thai and Croatian patients. *Acta Dermatovenerol Croat*. 2009;17:2–8.
- Gorsky M, Epstein JB, Hasson-Kanfi H, Kaufman E. Smoking Habits Among Patients Diagnosed with Oral Lichen Planus. *Tob Indu Dis*. 2004;2(1):9.
- Salonen L, Axell T, Hellden L. Occurrence of oral mucosal lesions, the influence of tobacco habits and an estimate of treatment time in an adult Swedish population. *J Oral Pathol Med*. 1990;19(4):170–6.
- Cekic-Aramba\_In A, Biocina-Lukenda D, Lazic-Segula B. Characteristics of oral lichen in the Croatian population. *Coll Antropol*. 1998;22:73–81.
- Salem G. Oral lichen planus among 4277 patients from Gizan, Saudi Arabia. *Comm Dent Oral Epidemiol*. 1989;17(6):322–4.
- Pindborg JJ, Mehta FS, Daftary DK, Gupta PC, Bhonsle RB. Prevalence of oral lichen planus among 7,639 India villages in Kerala South India. *Acta Dermatovenerol (Stokholm)*. 1972;52:216–20.
- Ikeda N, Ishii T, Iida S, Kawai T. Epidemiological study of oral leukoplakia based on mass screening for oral mucosal diseases in a selected Japanese population. *Comm Dent Oral Epidemiol*. 1991;19(3):160–3.
- Bagan JU, Ramon C, Gonzalez L, Diago M, Milian MA, Cors R, et al. Preliminary investigation of the association of oral lichen planus and hepatitis C. *Oral Surg Oral Med Oral Pathol*. 1998;85:532–6.
- Axell T, Rundquist L. Oral lichen planus - a demographic study. *Comm Dent Oral Epidemiol*. 1987;15(1):52–6.
- Cekic-Aramba\_In A, Biocina-Lukenda D, Lazic-Segula B. Characteristics of oral lichen in the Croatian population. *Coll Antropol*. 1998;22:73–81.
- Silverman S, Bahl S. Oral lichen planus update: clinical characteristics, treatment responses and malignant transformation. *Am J Dent*. 1997;10:259–63.

## Author biography

**Altat Hussain Chalkoo** Professor

**Tauseefa Jan** Post Graduate Student

**Bashir Ahmad Wani** Post Graduate Student

**Rayees Ahmad Sheikh** Post Graduate Student

**Cite this article:** Chalkoo AH, Jan T, Wani BA, Sheikh RA. Oral Lichen Planus in Kashmiri Population-a clinical prospective study. *IP Arch Cytol Histopathology Res* 2020;5(3):229-233.