



## Original Research Article

## Extranodal non-Hodgkin's lymphoma: A case series at a tertiary care hospital

Ravi Swami<sup>1</sup>, Shashank Singh<sup>1</sup>, Pomilla Singh<sup>1,\*</sup>, N S Mani<sup>1</sup>, M N Karandikar<sup>1</sup><sup>1</sup>Dept. of Pathology, Bharati Vidyapeeth Medical College, Pune, Maharashtra, India

## ARTICLE INFO

## Article history:

Received 16-12-2020

Accepted 19-12-2020

Available online 30-12-2020

## Keywords:

Immunohistochemistry

Extranodal

NonHodgkin lymphoma

## ABSTRACT

**Objective:** To study and findings in a case series of Extra Nodal Non Hodgkin Lymphomas (EN NHL).**Materials and Methods:** 17 cases of primary, collected during a period of November 2019 to November 2020 (one year), wherein the clinical data included age, gender, site, clinical presentation and findings were collected and staining was done along with (IHC) using a panel of antibodies depending on the morphology.**Result:** 17 cases of primary taken. Majority of our patients were from higher age group, presenting in sixth decade, though the age range was wide between 5-92 years. Our study included 12 males and 5 females, with a male: female ratio of 2.4:1. We found masses and GIT as the most common site for. Weight loss followed by fever was the most common clinical presentation in our study presentation. Ann Arbor Staging was done in 16/17 cases where 35% (6/17) belonged to stage I, 35% (6/17) cases belonged to stage II, 17.6 (3/17) belonged to stage III and 1.5% (1/17) belonged to Eastern cooperative oncology group performance scale (ECOG) was also calculated and documented.**Conclusion:** This study highlights importance of diagnosing Non Hodgkin's Lymphomas as a separate entity since its clinical presentation, prognosis, staging and management differs from Nodal NonHodgkins lymphoma.© This is an open access article distributed under the terms of the Creative Commons Attribution License (<https://creativecommons.org/licenses/by/4.0/>) which permits unrestricted use, distribution, and reproduction in any medium, provided the original author and source are credited.

## 1. Introduction

First definition of Extra Nodal Non Hodgkin Lymphomas (EN NHL) were first given by Dawson for gastrointestinal lymphomas.<sup>1</sup> The original Dawson criteria defined primary gastric lymphoma. It was later refined by Lewin<sup>2</sup> and Herrmann,<sup>3</sup> these criteria were relaxed to allow for contiguous involvement of other organs (e.g. liver, spleen), and for distant nodal disease, providing that the extranodal lesion was the presenting site and, after routine staging procedures, constituted the predominant disease bulk, to which primary treatment must be directed.<sup>4</sup>

The definition of primary EN-NHL is a controversial issue, especially in patients where both nodal and extranodal sites are involved. Some series on primary ENNHL have included patients with only localized disease. On the other hand, studies that use more liberal

criteria for EN-NHL include patients with disseminated disease (Rudders et al. Moller et al., 2004).<sup>5,6</sup>

Clearly, any chosen definition inevitably introduces a selection bias; a Dutch study from a different geographical population-based registry showed that the frequency of extranodal NHL fluctuated from 20% to 34%, depending on the adopted designation criteria.<sup>7</sup>

Various studies have reported incidence rates ranging from 10 to 48%.<sup>8,9</sup> The incidence of extranodal NHL in developing countries is largely unknown.

In the population-based cancer registries of the National Cancer Institute's Surveillance, Epidemiology, and End Results (SEER) Program, approximately 30% of all lymphomas were extranodal and almost half of all extranodal NHL cases reported had diffuse large B-cell lymphoma (DLBCL) histology.<sup>10</sup>

With this case series we aim to describe the anatomic distribution, clinical features, Immunohistochemical typing

\* Corresponding author.

E-mail address: [drravimswami@gmail.com](mailto:drravimswami@gmail.com) (P. Singh).

and outcome of EN NHL patients.

**2. Materials and Methods**

This is a descriptive case series of 17 cases of primary ENNHLs, collected during a period of 1 year. The number includes all cases of ENNHL diagnosed and confirmed on routine histopathology in the department of pathology. The tissue processing was done in 10% formalin and 5 paraffin sections were stained with hematoxylin and eosin (HE). Immunohistochemistry (IHC) was performed using a panel of antibodies depending on the morphology. The IHC was performed manually on the paraffin embedded tissue sections by using a panel of monoclonal antibodies. Antigen retrieval was done by pretreatment of paraffin sections by heating in a microwave in 0.01 M citrate buffer (pH6.0). The panel of antibodies used for IHC includes pancytokeratin, leukocyte common antigen, CD3, CD5, CD19, CD20, CD23, CD10, Bcl2, Bcl6, Tdt. Data pertaining to patients’ demography, clinical presentation, immune status, routine complete blood count, and microbiological (HIV, EBV, H.pylori, HCV, and HBV) status were obtained from the LIS. Molecular diagnostic techniques such as cytogenetics/fluorescence in situ hybridization were not performed in any of the cases

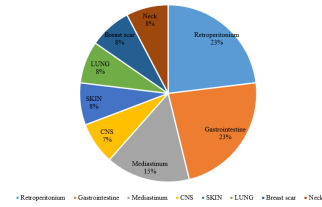
The cases includes all patients who present with NHL that apparently originated at an extranodal site, even in the presence of disseminated disease, as long as the extranodal component was clinically dominant as proposed by Krol et al.<sup>11</sup> Cases of tonsillar and Waldeyer’s ring lymphoma were excluded due to controversial status as extranodal site.<sup>12</sup>

All cases were classified based upon morphologic and immunophenotypic criteria according to World Health Organization (WHO) 2008 classification.<sup>13</sup> Clinical stage was defined according to the Ann Arbor classification.<sup>14</sup>

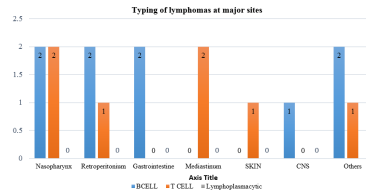
**3. Results**

Primary extranodal NHL constituted 26.9% (17/63) of all NHL diagnosed over a period of 1-year were included in the study. Majority of our patients were from higher age group, presenting in sixth decade, though the age range was wide between 5-92 years. Our study included 12 males and 5 females, with a male: female ratio of 2.4:1. Graph 1 describes the distribution of cases according to the site. Graph 2 describes the typing of lymphomas according to Immunohistochemistry. Graph 3 describes the clinical presentation of all cases.

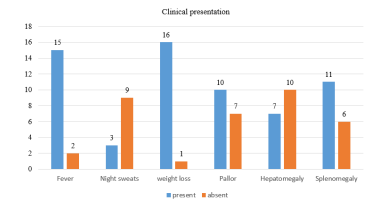
Ann Arbor Staging was done in 16/17 cases where 35% (6/17) belonged to stage I, 35% (6/17) cases belonged to stage II, 17.6 (3/17) belonged to stage III and 1.5% (1/17) belonged to stageIV as described in Table 1. Eastern cooperative oncology group performance scale (ECOG) was also calculated in these cases which are described in Table 2.



Graph 1: Distribution of EN-NHL



Graph 2: Typing of lymphomas at major site



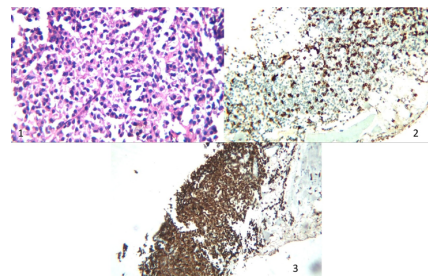
Graph 3: Clinical presentation in cases of EN-NHL

**Table 1: Stage (Ann Arbor system)**

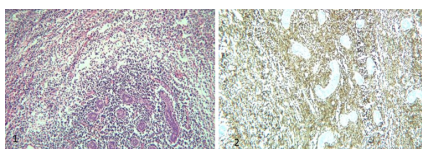
Ann Arbor Stage	Number of patients
I	6 (35%)
II	6 (35%)
III	3 (17.6%)
IV	1 (5.8%)

**Table 2: ECOG=Eastern cooperative oncology group performance scale**

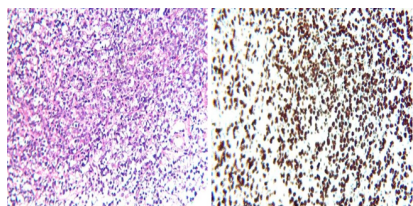
ECOG Score	Number of patients
0	3
1	4
2	4
3	3
4	2



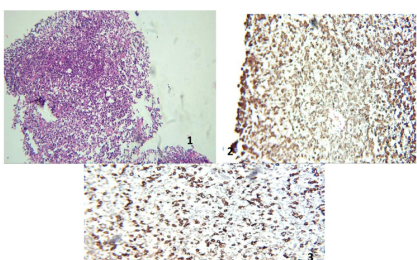
**Fig. 1:** H&E showing replacement of normal lung parenchyma with lymphoid cells, 2) CD79a Positive in lymphoid cells, 3) CD3 Positive.



**Fig. 2:** H&E showing lymphocytic infiltration in a cases of retroperitoneal mass, 2) Image shows IHCTdT positivity in a case of burkitt lymphoma



**Fig. 3:** 1)H&E from DLBCL cases showing large lymphocytes replacing normal architecture, 2) High Ki67 count



**Fig. 4:** 1) H&E image showing lymphocytic infiltration in soft tissue taken from nasalmsaa biopsy, 2abd 3) IHC CD3 and CD5, positive in T cell lymphoma

#### 4. Discussion

Primary extra nodal lymphomas have long been known for their heterogeneity because of its varied epidemiology and etiology. Studies from Western countries have reported the occurrence of extranodal NHL as 24-48% of all NHL.<sup>11,14–16</sup> In contrast to Asian studies the incidence varies from widely in China (44.9-61.4%), however most of country claim similar incidence of around 40 to 50%.<sup>17–20</sup> In India, the incidence and the sites varies widely. A study from Northern India by Singh et al. showed extranodal lymphomas constitute 44% with the most common site being the head and neck,<sup>21</sup> whereas a study conducted by Padhi et al. from Southern India showed extranodal lymphomas constituted 22% and the most common site being the central nervous system.<sup>23</sup> Western India shows incidence of 28% and GIT being the most common site that is affected.<sup>22</sup> Our study showed incidence of 25.3% with Nasopharynx (4/17) being the most common site of EN NHL, followed by retroperitoneal masses (3/17). The incidence is much lower, which may be due to shorter duration of the study and due to variation in genetic and ethnic factors, as well as the diverse

definition criteria. Diffuse large B-cell lymphoma (8/17) was the most common histological subtype found in the current series. It is in concordance with many studies on EN-NHL.<sup>21,23–26</sup> Nasopharyngeal lymphoma is a rare extranodal lymphoma with a variety of histopathologic subtypes, and the incidences of different subtypes are quite different among different areas. Diffuse large B cell lymphoma (DLBCL) and NK/T cell lymphoma (NKTCL) are the two most common pathologic diagnoses.<sup>27,28</sup> The prognosis is different in different forms, however a correlation with disease stage has been noted. The current series report 2 cases of NP DLBCL, while other 2 were T cell lymphoma. Ye et al. also found an equal incidence of B-cell (51%) and T-cell (49%) lymphomas in the nasopharynx among 54 cases.<sup>29</sup> While, in the another study of 113 patients reported by Cheung et al. lymphoma involving the nasal cavity was mostly of NK/T-cell or T-cell lineage, while almost half of the lymphomas involving the nasopharynx were of B-cell lineage.<sup>30</sup> one case of DLBCL of Central Nervous System, another nasopharyngeal T cell lymphoma was seen in HIV positive patients. Extranodal DLBCL is the most commonly presenting lymphomas in immunocompetent HIV patients, and similar to this patient presents at a higher stage of disease. However Tcell lymphoma is a very rare such patients. The present case series includes one case of Primary Pulmonary Lymphoma (PPL), which histologically was B-cell NHL. PPL is a very rare neoplasms, presenting as only 0.4% of lymphomas.<sup>31</sup> It is defined as a clonal lymphoid proliferation affecting one or both lungs in a patients with no detectable extrapulmonary involvement at diagnosis or subsequent 3 months.<sup>32</sup> One large series of 70 patients reported 94% survival at 5 years for low grade PPL.<sup>32–34</sup>

#### 5. Conclusion

Primary extranodal lymphomas constitute a diverse group of hematology malignancies whose prognosis depends upon the primary site. The incidence of pENL is low in India compared to data from other parts of the world. With this case series we add to the literature basic knowledge about ENNHL.

#### 6. Source of Funding

No financial support was received for the work within this manuscript.

#### 7. Conflict of Interest

The authors declare they have no conflict of interest.

#### References

1. Cavalli F. Rare syndromes in Hodgkin's disease. *Ann Oncol.* 1998;9(5):s109–13. doi:10.1093/annonc/9.suppl\_5.s109.

2. Sapozink M, Kaplan H. Intracranial Hodgkin's disease. A report of 12 cases and review of the literature. *Cancer*. 1983;52(7):1301–7.
3. Akyüz C, Yalcin B, Atahan IL, Varan A, Kutluk MT, Büyükpamukçu M, et al. INTRACRANIAL INVOLVEMENT IN HODGKIN'S DISEASE. *Pediatr Hematol Oncol* . 2005;22(7):589–96. doi:10.1080/08880010500198863.
4. Re D. CNS involvement in Hodgkin's lymphoma. *J Clin Oncol*. 2002;25(21):441–51.
5. Rudders RA, Ross ME, Delellis RA. Extranodallymphoma: Response to treatment and factors influencingprognosis. *Cancer*. 1978;42:406–422.
6. Möller MB, Pedersen NT, Christensen BE. Diffuse large B-cell lymphoma: clinical implications of extranodal versus nodal presentation - a population-based study of 1575 cases. *Br J Haematol*. 2004;124(2):151–9. doi:10.1046/j.1365-2141.2003.04749.x.
7. Gates AE, Kaplan LD. AIDS malignancies in the era of highly active antiretroviral therapy. *Oncol (Williston Park)*. 2002;16(5):657–65.
8. Zucca E, Cavalli F. Extranodal lymphomas. *Ann Oncol*. 2000;11(3):219–22. Available from: <http://annonc.oxfordjournals.org/>.
9. Rehman SA, Sidique M, Ahmad G, Naiz M. Extra nodal lymphoma. *Prof Med J*. 2005;12:223–9.
10. Howlader N, Noone AM, Krapcho M, Miller D, Brest A, Yu M. SEER Cancer Statistics Review. In: 1975–2017, National Cancer Institute. Bethesda, MD. [https://seer.cancer.gov/csr/1975\\_](https://seer.cancer.gov/csr/1975_); 1975. Available from: [https://seer.cancer.gov/csr/1975\\_2017](https://seer.cancer.gov/csr/1975_2017).
11. Krol ADG, le Cessie S, Snijder S, Kluin-Nelemans JC, Kluin PM, Noordijk EM. Primary extranodal non-Hodgkin's lymphoma (NHL): the impact of alternative definitions tested in the Comprehensive Cancer Centre West population-based NHL registry. *Ann Oncol*. 2003;14(1):131–9. doi:10.1093/annonc/mdg004.
12. Cavalli F, Lymphomas. Extranodal lymphomas. In: Magrath IT, editor. *The non-Hodgkin's Lymphomas*. 2nd edn. London: Arnold; 1997. p. 1007–27.
13. Swerdlow SH, Campo E, Harris NL, Jaffe ES, Pileri SA, Stein H, et al. World Health Organization Classification of Tumours of Haematopoietic and Lymphoid Tissues. In: 4th Edn. Lyon, France: IARC; 2008.
14. Carbone PP, Kaplan HS, Musshoff K, Smithers DW, Tubiana M. Report of the Committee on Hodgkin's disease staging classification. *Cancer Res*. 1971;31:1860–1.
15. Zucca E, Roggero E, Bertoni F, Cavalli F. Primary extranodal non-Hodgkin's lymphomas. Part 1: Gastrointestinal, cutaneous and genitourinary lymphomas. *Ann Oncol*. 1997;8(8):727–37. doi:10.1023/a:1008282818705.
16. Zucca E, Roggero E, Bertoni F, Conconi A, Cavalli F. Primary extranodal non-Hodgkin's lymphomas. Part 2: Head and neck, central nervous system and other less common sites. *Ann Oncol*. 1999;10(9):1023–33. doi:10.1023/a:1008313229892.
17. Fujita A, Tomita N, Fujita H, Motohashi K, Hyo R, Yamazaki E, et al. Features of primary extranodal lymphoma in Kanagawa, a human T-cell leukemia virus type 1 nonendemic area in Japan. *Med Oncol*. 2009;26(1):49–54. doi:10.1007/s12032-008-9080-0.
18. Yoon SO, Suh C, Lee DH, Chi HS, Park CJ, Jang SS, et al. Distribution of lymphoid neoplasms in the Republic of Korea: Analysis of 5318 cases according to the World Health Organization classification. *Am J Hematol*. 2010;85:760–4.
19. Sukpanichnant S. Analysis of 1983 cases of malignant lymphoma in Thailand according to the world health organization classification. *Hum Pathol*. 2004;35(2):224–30. doi:10.1016/j.humpath.2003.10.007.
20. Aoki R, Karube K, Sugita Y, Nomura Y, Shimizu K, Kimura Y. Distribution of malignant lymphoma in Japan: Analysis of 2260 cases. *PatholInt*. 2001;58:174–82.
21. Singh D, Kumar L, Goyal H, Raina V, Bijlani L, Wadhwa J, et al. Primaryextranodal non-Hodgkin's lymphoma in Northern India. *Proc Am Soc Clin Oncol*. 2003;22:2457.
22. Gross SA, Zhu X, Bao L, Ryder J, Le A, Chen Y, et al. A prospective study of 728 cases of non-Hodgkin lymphoma from a single laboratory in Shanghai, China. *Int J Hematol* . 2008;88(2):165–73. doi:10.1007/s12185-008-0132-1.
23. Padhi S, Paul TR, Challa S, Prayaga AK, Rajappa S, Raghunadharao D, et al. Primary Extra Nodal Non Hodgkin Lymphoma: A 5 Year Retrospective Analysis. *Asian Pac J Cancer Prev* . 2012;13(10):4889–95. doi:10.7314/apjcp.2012.13.10.4889.
24. Kim JM, YH K, Huh J, Kang TS, Kim CW. WHO classification of malignant lymphomas in Korea: Report of the third nationwide study. *Korean J Pathol*. 2011;45:254–60.
25. Yang QP, Zhang WY, Yu JB, Zhao S, Xu H, Wang WY, et al. Subtypedistribution of lymphomas in Southwest China: Analysis of 6,382 casesusing WHO classification in a single institution. *Diagn Pathol*. 2011;6:77.
26. Fujita A, Tomita N, Fujita H, Motohashi K, Hyo R, Yamazaki E, et al. Features of primary extranodal lymphoma in Kanagawa, a human T-cell leukemia virus type 1 nonendemic area in Japan. *Med Oncol*. 2009;26(1):49–54. doi:10.1007/s12032-008-9080-0.
27. Wu RY, Li YX, Wang WH, Jin J, Wang SL, Liu YP, et al. Clinical disparity and favorable prognoses for patients with Waldeyer ring extranodal nasal-type NK/T-cell lymphoma and diffuse large B-cell lymphoma. *Am J Clin Oncol*. 2014;37:41–6.
28. Han AY, Kuan EC, Alonso JE, Badran KW, John MAS. Epidemiology of Nasopharyngeal Lymphoma in the United States: A Population-Based Analysis of 1119 Cases. *Otolaryngol Head Neck Surg*. 2017;156(5):870–6. doi:10.1177/0194599817695808.
29. Lei KIK, Suen JJS, Hui P, Tong M, Li W, Yau SH, et al. Primary Nasal and Nasopharyngeal Lymphomas: A Comparative Study of Clinical Presentation and Treatment Outcome. *Clin Oncol*. 1999;11(6):379–87. doi:10.1053/clon.1999.9088.
30. Cheung MM, Chan JK, Lau WH, Foo W, Chan PT, Ng CS, et al. Primary non-Hodgkin's lymphoma of the nose and nasopharynx: clinical features, tumor immunophenotype, and treatment outcome in 113 patients. *J Clin Oncol*. 1998;16(1):70–7. doi:10.1200/jco.1998.16.1.70.
31. Ferraro P, Trastek VF, Adlakha H, Deschamps C, Allen MS, Pairolero PC, et al. Primary non-Hodgkin's lymphoma of the lung. *Ann Thorac Surg*. 2000;69(4):993–7. doi:10.1016/s0003-4975(99)01535-0.
32. Rivera CM, Vilaplana MB, Adiego CS, Forgué AP, Zuza JP, Lauro IS, et al. Primary Pulmonary Lymphoma Presenting as a Pulmonary Mass With Cavitation. *Arch Bronconeumol*. 2004;40(2):94–6. doi:10.1016/s1579-2129(06)60201-2.
33. Kim JH, Lee SH, Park J, Kim HY, Lee SI, Park JO, et al. Primary pulmonary non-hodgkin's lymphoma. *Jpn J Clin Oncol*. 2004;34:510–4.
34. Graham BB, Mathisen DJ, Mark EJ, Takvorian RW. Primary Pulmonary Lymphoma. *Ann Thoracic Surg*. 2005;80(4):1248–53. doi:10.1016/j.athoracsur.2005.04.014.

## Author biography

**Ravi Swami**, Associate Professor

**Shashank Singh**, Postgraduate Resident

**Pomilla Singh**, Assistant Professor

**N S Mani**, Professor

**M N Karandikar**, Professor

**Cite this article:** Swami R, Singh S, Singh P, Mani NS, Karandikar MN. Extranodal non-Hodgkin's lymphoma: A case series at a tertiary care hospital. *IP Arch Cytol Histopathology Res* 2020;5(4):302-305.