



Case Report

Granular cell tumor of nasal cavity: An uncommon occurrence with review of literature

Punam Prasad Bhadani^{1,*}, Iffat Jamal²

¹Dept. of Pathology, All India Institute of Medical Sciences, Patna, Bihar, India

²Dept. of Pathology, Indira Gandhi Institute of Medical Sciences, Patna, Bihar, India



ARTICLE INFO

Article history:

Received 10-10-2020

Accepted 03-12-2020

Available online 30-12-2020

Keywords:

Granular cell tumors (GCTs)

ABSTRACT

Granular cell tumors (GCTs) are uncommon benign lesions which usually occur in head and neck region, with tongue being the most common site. Lesions involving nasal and paranasal areas are extremely rare. We report a case of GCT arising from left nasal cavity in a 15 year old female who presented with unilateral epistaxis since 4-5 months.

© This is an open access article distributed under the terms of the Creative Commons Attribution License (<https://creativecommons.org/licenses/by/4.0/>) which permits unrestricted use, distribution, and reproduction in any medium, provided the original author and source are credited.

1. Introduction

GCTs are rare benign neoplasms affecting mucus membranes of upper aerodigestive tract. About one - third of all GCTs occur in head and neck region. The most common site is anterior part of tongue. Most GCTs are benign with 10% malignant behaviour. GCTs are most commonly seen in 4th -6th decades of life.¹

2. Case Report

A 15 year old female patient presented with a fleshy mass protruding from left nasal cavity associated with epistaxis since 4-5 months. On examination the entire left nasal cavity was filled with reddish brown polypoidal fleshy mass protruding outside. (Figure 1) CT scan revealed normal paranasal sinuses and oral cavity. A clinico -radiological diagnosis of foreign body associated Polypoidal growth was suspected. The mass was excised and sent for histopathology. Grossly a globular greyish white soft tissue mass was received of size 5x 2x 1.5 cm. Cut section was solid, greyish white, homogenous with tiny cystic areas. (Figure 2)

Microscopy revealed sheets of plump polygonal cells arranged in nests and diffuse sheets having centrally placed round nuclei with abundant eosinophilic granular cytoplasm. At places chronic inflammatory infiltrate and bacterial colonies also noted. Special stain PAS revealed diffuse, intense and granular cytoplasmic positivity in tumor cells (Figure 3). IHC S-100 was recommended for further confirmation, IHC was done outside the Institute, which showed immunoreactivity with this marker. Based on these findings a histopathological diagnosis of Granular cell tumor (GCT) was rendered.

3. Discussion

Abrikosoff first described GCT as granular cell myoblastoma in 1926 as it was thought to originate from myoblast initially.² Holland et al. proposed a neurogenic origin on the basis of close association of tumor with nerves and similar ultrastructural findings.³

Nasal masses can have a wide variety of possible differential diagnoses, including inflammatory proliferative lesions, infective lesions, and neoplastic conditions that are either benign or malignant. A GCT is also one of the possibilities as well. There is a wide age -range of occurrence in GCTs as they have been reported in patients as young as 11 months and as old as 104 years, but these

* Corresponding author.

E-mail address: bhadanipunam@gmail.com (P. P. Bhadani).

lesions occur most frequently in patients who are in between their fourth and sixth decades.⁴

GCTs are seen frequently arising in the head and neck regions; they are found most often on the tongue, but also occur on the skin and in the stomach, bronchi, and bile ducts. Within the head and neck regions, GCTs have been found in the larynx, soft palate, labial mucosa, uvula, oral floor, gingivae, orbits, lacrimal sacs, nasolacrimal ducts, and parotid glands. (Table 1).^{5,6} It is difficult to differentiate GCT in nasal cavity from Congenital epulis, Granular cell ameloblastoma and rhabdomyoma clinically.

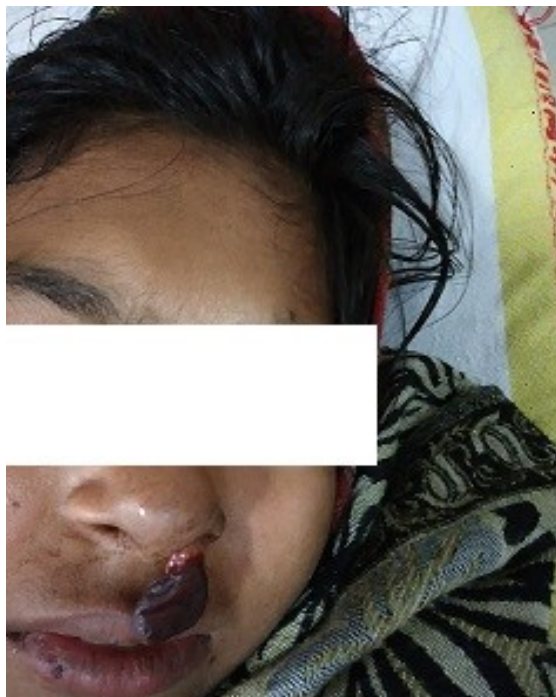

Fig. 1: Clinical photograph of patient showing a reddish polypoidal mass projecting from left nasal cavity.

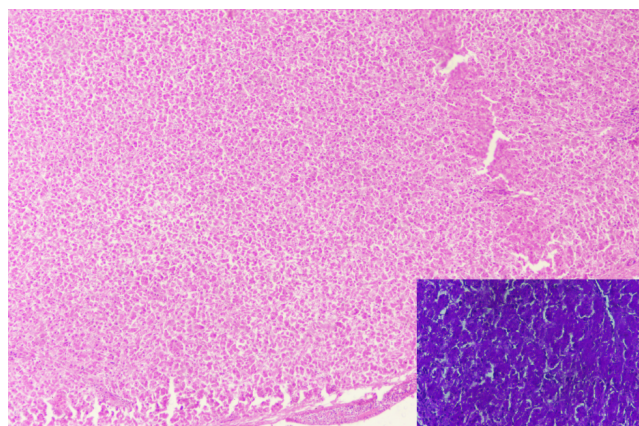


Fig. 2: Gross photograph of excised mass in pieces having a solid, greyish white, homogenous appearance.

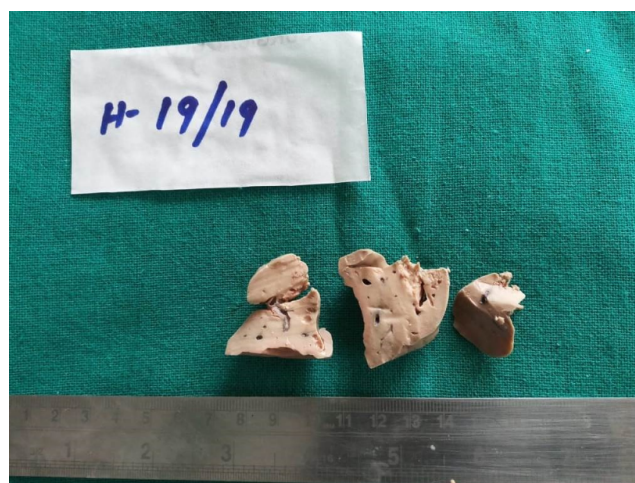


Fig. 3: Microphotograph of excised mass showing sheets of polygonal cells with abundant eosinophilic cytoplasm (H & E; 100X), Inset show diffuse strong PAS positivity (PAS stain; 400x)

Two distinct subtypes have been described. 1) A congenital epulis or gingival GCT of infancy and 2) adult GCT. The tumor mostly presents as solitary lesion, with multifocal presentation accounting for only 5-10% of all cases.^{5,6}

GCTs are microscopically characterised by sheets and nests of large, polygonal, pale to eosinophilic tumor cells with a granular cytoplasm and centrally placed bland nuclei. Microscopically it resembles sheets of histiocytes where it is often misdiagnosed as an inflammatory condition.⁸ Most GCTs are benign but malignancy is reported in approximately 10% of cases.⁷ The malignant potential of GCT is reflected by cellular and nuclear pleomorphism, necrosis and increase mitotic activity. Such cases require close long term follow up. Large size of the lesion, rapid growth, infiltration of adjacent bony and soft tissues and metastasis to regional and distant lymph nodes denotes malignant potential of this lesion.^{7,9,10} GCTs express S-100, Neuron specific enolase and also CD68 which is a histiocytic marker.¹¹

Histopathologically, GCTs can mimic granular cell variants of other tumors, such as leiomyoma, dermatofibrosarcoma, and angiosarcoma. Immunohistochemistry can be used to confirm a GCT diagnosis: GCTs are consistently positive for the S-100 protein and consistently negative for desmin, cytokeratins, the smooth muscle antigen and the epithelial membrane antigen.¹²

Surgical excision is the first choice of treatment for GCTs originating in common sites such as the skin. However when they arise in the nasal cavity, there are no accepted standards for the management of GCTs.¹³

Table 1: Summary of GCT in nasal and paranasal sinus reported in literature.

Study	Age in years	Sex	Location	Size	Presentation	Treatment
Salman et al. (1989) ⁷	22	Male	Maxillary sinus	NA	Facial swelling	Partial maxillectomy
Hwang et al. (2001) ⁴	6	Female	Nasal septum	0.6 cm	Nasal discharge	Excision biopsy
Sasaki et al. (2007) ⁸	69	Female	Nasal septum	0.19 cm	Recurrent epistaxis	Excision biopsy
Yang et al. (2012) ⁹	24	Male	Maxillary sinus	0.13 cm	Nasal discharge	Multiple sinusectomy
Present study (2020)	15	Female	Nasal cavity	5cm	Nasal obstruction with epistaxis	Excision biopsy

4. Conclusion

GCT is a rare soft tissue tumor arising from mucosa of nasal cavity. The small size of this lesion and unusual location makes clinical and radiological diagnosis difficult. Histopathology along with IHC plays a vital role in correct diagnosis.

5. Source of Funding

No financial support was received for the work within this manuscript.

6. Conflict of Interest

The authors declare they have no conflict of interest.

References

- Bitar M, Afif KA, Fatani MI. Granular cell tumor: Case report. *J Saudi Soc Dermatol Dermatol Surg.* 2011;15(1):25–7. doi:10.1016/j.jssdds.2010.10.005.
- Lee H, Goh E, Park S, Kong S. A case of granular cell tumor of postauricular area. *Korean J Otorhinolaryngol Head Neck Surg.* 2009;52:921–3.
- Fanburg-Smith JC, Meis-Kindblom JM, Fante R, Kindblom LG. Malignant granular cell tumor of soft tissue: diagnostic criteria and clinicopathologic correlation. *Am J Surg Pathol.* 1998;22:779–94.
- Hwang JSG, Ang HK, Aw CY. Case report of a granular cell tumour in the nasal septum of a child. *Singapore Med J.* 2001;42(8):378–9.
- Elkousy H, Harrelson J, Dodd L, Martinez S, Scully S. Granular Cell Tumors of the Extremities. *Clin Orthop Related Res.* 2000;380:191–8. doi:10.1097/00003086-200011000-00026.
- Kim DJ, Kim HW, Park SB, Choi CW, Kang DH, Hong JB, et al. A case of gastric granular cell tumor: review of literature and features of endoscopic ultrasonography. *Korean J Helicobacter Upper Gastrointestinal Res.* 2015;15(1):59–63.
- Salman RA, Leonetti JA, Salman L, Chaudhry AP. Adult benign granular cell tumor of the maxilla. *J Oral Pathol Med.* 1989;18(9):517–9. doi:10.1111/j.1600-0714.1989.tb01354.x.
- Sasaki T, Yamamoto K, Akashi T. Granular cell tumour arising from the Kiesselbach's area of the nasal septum. *J Laryngology Otol.* 2007;121(2):170–3. doi:10.1017/s002221510600394x.
- Yang C, Chin S. Granular cell tumor of the left maxillary paranasal sinus in a 24-year-old man. *Tzu Chi Med J.* 2012;24(1):16–8.
- Rekhi B, Jambhekar NA. Morphologic spectrum, immunohistochemical analysis, and clinical features of a series of granular cell tumors of soft tissues: a study from a tertiary referral cancer center. *Ann Diagn Pathol.* 2010;14(3):162–7. doi:10.1016/j.anndiagpath.2010.01.005.
- Ramos PC, Kapp DS, Longacre TA, Teng NNH. Malignant granular cell tumor of the vulva in a 17-year-old: Case report and literature review. *Int J Gynecol Cancer.* 2000;10(5):429–34. doi:10.1046/j.1525-1438.2000.010005429.x.
- Fanburg-Smith JC, Meis-Kindblom JM, Fante R, Kindblom LG. Malignant granular cell tumor of soft tissue: diagnostic criteria and clinicopathologic correlation. *Am J Surg Pathol.* 1998;22:779–94.
- Kim HJ, Lee MG. Granular cell tumors on unusual anatomic locations. *Yonsei Med J.* 2015;56:1731–1735.

Author biography

Punam Prasad Bhadani, Professor and Head

Iffat Jamal, Assistant Professor

Cite this article: Bhadani PP, Jamal I. Granular cell tumor of nasal cavity: An uncommon occurrence with review of literature. *IP Arch Cytol Histopathology Res* 2020;5(4):309-311.