



Case Report

Carcinoma of unknown primary: Extensive search for the culprit-A rare case entity

Dhiraj B Nikumbh^{1,*}, Parvez Mujawar², Roopali D Nikumbh³

¹Dept. of Pathology, SBH, Government Medical College, Dhule, Maharashtra, India

²Dept. of Surgery, SBH Government Medical College, Dhule, Maharashtra, India

³Dept. of Anatomy, SBH Government Medical College, Dhule, Maharashtra, India



ARTICLE INFO

Article history:

Received 01-12-2020

Accepted 20-12-2020

Available online 30-12-2020

Keywords:

Occult

Immunohistochemistry

Carcinoma

Unknown origin

ABSTRACT

Carcinoma of unknown primary (CUP) is commonly known as ‘occult primary cancer’. It’s defined as metastatic malignant cancer confined by pathology in absence of clinically detectable, anatomically defined primary tumor site after an adequate pretreatment diagnostic evaluation.

Herein we present a case of 35 year old female of CUP presented with pain in left axillary region that is vague clinical manifestation. Histopathologically it was proved as metastatic adenocarcinoma on axillary mass probably of breast origin. Primary nature is not diagnosed even on IHC.

The aim of this case report is to highlight role of ancillary pathology techniques in challenging cases like CUP.

© This is an open access article distributed under the terms of the Creative Commons Attribution License (<https://creativecommons.org/licenses/by/4.0/>) which permits unrestricted use, distribution, and reproduction in any medium, provided the original author and source are credited.

1. Introduction

Carcinoma of unknown primary (CUP) or ‘occult primary cancer’ is defined as metastatic malignant cancer confined by histopathology in absence of clinically detectable primary tumor site after an adequate pretreatment diagnostic evaluation.^{1,2} CUP as rare entity pose a significant diagnostic and therapeutic challenge for treating clinician.² CUP has poorer prognosis as compared to known primary origin. It constitute 3-5% of new carcinoma cases annually and constitute fourth major cause of cancer related mortality in western world.^{3,4} We aimed to present this case report in view of its unknown primary nature, great diagnostic and therapeutic challenge to clinician. Immunohistochemistry (IHC) assays are most diagnostic tool used to detect primary nature of cancer but surprisingly fail to identify in one third of cases, as seen in our case. Recently, microRNA expression assay demonstrate a definite role in diagnosis of CUP.¹

2. Case Report

A 35 year old female presented to the surgical department of our hospital with chief complaints of left axillary pain since 1 month. Clinical examination revealed mobile, firm, mild tender axillary mass? lymph nodes measuring 12x9x7cms. On clinical examination suspected as matted lymph nodes of Koch’s. Outside FNAC was reported as necrotizing lymphadenitis. Both the breast and cervical region showed no palpable nodule or mass. Pre-operative investigations were within normal limit. Wide local excision of axillary mass was done and specimen sent for histopathology.

Received excised grey yellow soft tissue mass measured 11x7x5 cms. E/S-yellowish with grey brown areas. On C/S-6 lymph nodes seen, larger measures 4x4 cms with central grey white and occasional hemorrhagic areas (Figure 1). Light microscopy shows lymph nodes with complete effacement of architecture and replaced by tumor (Figure 2A,B). The pericapsular and all rest of the cortex of nodes are filled with tumor. The tumor composed of neoplastic cells arranged in sheets, tubules, acini and cords (Figure 3). Individual tumor cells are large round to

* Corresponding author.

E-mail address: drdhirajnikumbh@gmail.com (D. B. Nikumbh).

oval with hyperchromatic to vesicular nuclei with prominent nucleoli with moderate amount of pale to eosinophilic cytoplasm (Figure 4). Comedo type of necrosis surrounded by tumor cells are evident. Many mitotic figures and glandular structures around vessels are noted. Large areas of necrosis with infiltration of tumor in perinodal tissue are seen. Final impression given was positive for epithelial malignancy s/o Metastatic adenocarcinoma of left axillary lymphadenopathy.

Immunohistochemistry was done with 13 panels to know the site of primary in our case. Tumor was immunopositive for CK7 and immunonegative for CK20/mammoglobin /ER, PR/GCDFP15/GATA3/TTF1/Napsin /CDX2/CEA/ Pax8/p40/uropalakin III. Due to combination of CK7 positivity and CK 20 negative, most likely site of primary tumor suspected was the breast. PET scan revealed metastasis in the liver with no detectable primary site of origin including breast, GIT and ovary. Patient was sent for oncology center for further treatment.



Fig. 1: Cut section showed grey white multiple lymph nodes with focal hemorrhagic areas.

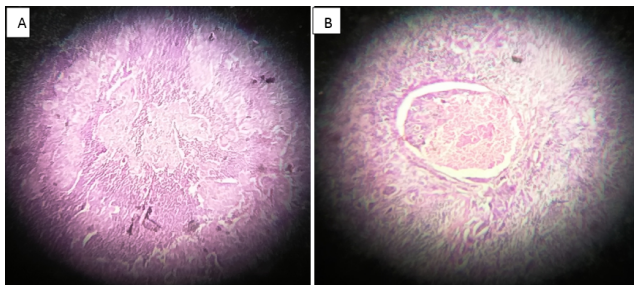


Fig. 2: A,B: Light microscopy showed replacement of lymph node by tumor. The tumor composed of neoplastic cells arranged in sheets, tubules, acini and cords. (H &E stain, x100).

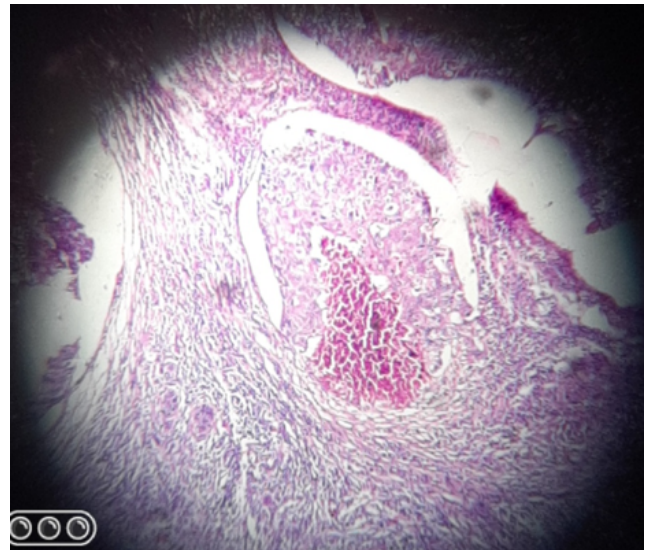


Fig. 3: Individual tumor cells are large round to oval with hyperchromatic to vesicular nuclei with prominent nucleoli with moderate amount of pale to eosinophilic cytoplasm (H &E stain, x100).

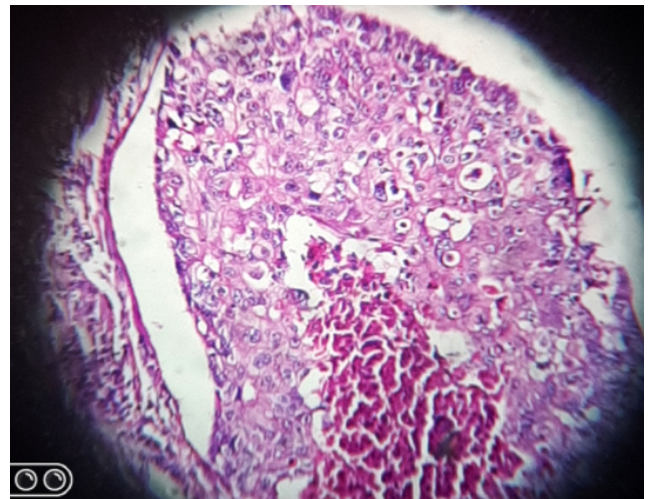


Fig. 4: Individual tumor cells on high power with comedo necrosis (H &E stain, x400).

3. Discussion

Carcinoma of unknown primary is a rare, heterogeneous malignancy with unknown site of origin and comprises 3 to 5% of all malignancies.^{5,6} Majority of the CUP are adenocarcinomas in 80-90% of cases.^{7,8} It is also called as 'occult cancer or orphan disease' diagnosed on histopathology of metastases while the anatomical site of origin remains elusive after initial workup.⁸ CUP has aggressive clinical course, short preclinical history, early spread and resistance to treatment as radio or chemotherapy. The overall prognosis is poor with median survival of 3 to 4

months after initial diagnosis.^{1,9}

Diagnostic criteria for CUP includes – metastatic cancer confirmed by the following-Complete clinical history, physical examination, laboratory investigations, imaging and invasive procedures according to presentation along with pathological examination by H&E staining and IHC.¹⁰ In less than 30% of cases only, primary site of CUP is identified by IHC and even on autopsies it can be successful in 20 to 50% of cases.¹⁰ Rest of the cases are undiagnosed or probably reached the diagnosis upto most likely organ etc, like in our case. In CUP, both the genders are equally affected with median of presentation is 60 years.¹⁰ Unfortunately, our patient is quite young one and specific registry for CUP is lacking globally.¹⁰

The CUP has varied and poorly comprehended etiopathogenesis. The symptoms and signs of CUP are vary depending upon the site of metastasis but usually presented with other vague or pressure symptoms.¹¹ The patients of CUP has varied clinical presentation and different histological tumor types as encountered in our case. The hypothesized reason for CUP is regression of primary tumor after the metastasis or the primary is too small to be detected within the present imaging modalities.¹⁰ Other author suggest that primary one is not elucidated due to its elimination or contained by the immune system.¹⁰ Hence diagnostic and therapeutic approach for CUP is quite challenging to both the pathologist and clinicians. Therefore, the approach is quite complicated and should not be limited to the form of presentation. On histopathology five broad subtypes of CUP can be identified as per Schwartz AM¹² as moderate adenocarcinoma (60%), undifferentiated adenocarcinoma (29%), squamous cell carcinoma (5%), undifferentiated carcinoma (3%), neuroendocrine carcinoma(2%).¹² IHC helps and acts as vital component in investigating CUP malignancies. However it lacks specificity and sensitivity as CUP is not uniformly site specific or sensitive.¹² In our case, 13 IHC stains were used but only CK 7 is positive. Rest all are negative, giving most likely organ as breast. Now a days, genomic profiling (mRNA) for the primary site of origin is effective, fast way and integral tool in CUP cancers as it identify the cell of origin.

4. Conclusion

Diagnosis of CUP necessitates a careful clinical workup and thorough histopathological examination as well as concomitant IHC and imaging studies like PET-Scan. However even with above modalities, it's not possible to diagnose primary site of origin in CUP. Now days in this uncertain landscape, immuno and genomic profiling is a valuable tool to determine tumor type and likely tissue of origin to overcome the challenges in diagnosing carcinoma

of unknown origin.

5. Source of Funding

No financial support was received for the work within this manuscript.


6. Conflict of Interest

The authors declare they have no conflict of interest.

References

1. Rigakos G, Vakos A, Papadopoulos S, Vernadou A, Tsimpidakis A, Papachristou D, et al. Cancer of unknown primary ultimately diagnosed as male breast cancer: A rare case report. *Mol Clin Oncol*. 2016;5(2):263–6. doi:10.3892/mco.2016.912.
2. Varadhachary GR, Raber MN. Cancer of Unknown Primary Site. *N Engl J Med*. 2014;371(8):757–60. doi:10.1056/nejmra1303917.
3. Pavlidis N, Fizaki K. Cancer of unknown primary. *Crit Rev Oncol Hematol*. 2005;54:243–50.
4. Pavlidis N, Briasoulis E, Hainsworth J, Greco FA. Diagnostic and therapeutic management of cancer of an unknown primary. *Eur J Cancer*. 2003;39(14):1990–2005. doi:10.1016/s0959-8049(03)00547-1.
5. Alkabi S, Bello B, Martinez RF, Gwis WP, Ballos MS. Metastatic adenocarcinoma of unknown origin presenting as small bowel obstruction. A case report and literature review. *J Inv Med High Impact Case Rep*. 2007;.
6. Pavlidis N, Pentheroadakis G. Cancer of unknown primary site. *Lancet*. 2012;379:1428–35.
7. Greco FA, Hainsworth JD. Introduction: Unknown Primary Cancer. *Semin Oncol*. 2009;36(1):6–7. doi:10.1053/j.seminoncol.2008.10.007.
8. Kaals R, Sookthai D, Hemminki KEA. Risk factor for cancer of unknown primary :Results from the prospective EPIC cohort. *Int J Cancer*. 2014;135:2475–81.
9. Riihimaki M, Thomson H, Hemminki K, Sundquist K, Hamminski K, et al. Comparison of survival of patients with metastasis from known vs unknown primaries:Survival in metastatic cancer. *BMC Cancer*. 2013;13:26.
10. Heredia RD, Kuba DM, Raiz-Morules JM, Ochoa CV, Tera RD. Metastasis from a cancer of unknown primary. *Case Rep Oncol*. 2018;11:541–8.
11. Varadhachary GR, Raber MN. Cancer of Unknown Primary Site. *N Engl J Med*. 2014;371(8):762–5. doi:10.1056/nejmra1303917.
12. Schwartz AM, Harpe N. A primary approach to cancers of unknown primary. *J Natl Cancer Inst*. 2003;(11):759–61.

Author biography

Dhiraj B Nikumbh, Associate Professor  <https://orcid.org/0000-0002-7440-9007>

Parvez Mujawar, Professor

Roopali D Nikumbh, Assistant Professor

Cite this article: Nikumbh DB, Mujawar P, Nikumbh RD. Carcinoma of unknown primary: Extensive search for the culprit-A rare case entity. *IP Arch Cytol Histopathology Res* 2020;5(4):331–333.