



Case Report

Aggressive thyroid malignancy presenting with unusual site cutaneous metastasis

Gagan Kumar Rangari^{1,*}, Mary June Nongphud¹, Neeraj Dhameja¹,
Shankhanila Mazumdar¹, Neelu Kashyap¹

¹Dept. of Pathology, Institute of Medical Sciences, Banaras Hindu University, Varanasi, Uttar Pradesh, India



ARTICLE INFO

Article history:

Received 06-01-2021

Accepted 08-02-2021

Available online 03-04-2021

Keywords:

Anaplastic Thyroid Carcinoma
Bethesda Thyroid cytopathology
Cutaneous metastasis
Squamoid differentiation
Thyroid Fine Needle Aspiration

ABSTRACT

Introduction: Anaplastic thyroid carcinoma (ATC) presenting with cutaneous metastasis is rare and only few cases have been reported so far. Commonly involved sites are the cervical region and the thorax. Anaplastic thyroid carcinoma has poor prognosis and no standard treatment has been documented however extensive surgery with curative treatment often with adjuvant radiation and chemotherapy are effective. Most common genetic mutation in ATC is P53 (20-83% cases), RAS mutation (up to 50%), BRAFV600E mutation (25%) p13KCA mutation (12-23%) and copy gain leading to Akt activation (38-61%).

Case Presentation: In our study, we have reported a case of a 66 years old male patient who presented with thyroid, back and the ribs (right side) swelling with a radiological diagnosis of malignant thyroid lesion, FNAC was done from all of the above mentioned sites. FNAC smears from all sites showed pleomorphic atypical cells. A diagnosis suggestive of High Grade Epithelial Neoplastic lesion was given with a possibility of Anaplastic thyroid carcinoma with cutaneous metastasis.

Conclusion: Anaplastic thyroid carcinomas (ATC) with cutaneous metastasis often present with solitary or multiple swellings as seen in many studies. Very few cases has been reported which has been diagnosed on FNAC. The case reported highlights multiple nodular swelling in neck, right side back and ribs. Cytomorphologically it was suggestive of anaplastic thyroid carcinoma with cutaneous metastasis, which is rare and only few cases documented.

© This is an open access article distributed under the terms of the Creative Commons Attribution License (<https://creativecommons.org/licenses/by/4.0/>) which permits unrestricted use, distribution, and reproduction in any medium, provided the original author and source are credited.

1. Introduction

Anaplastic thyroid carcinoma (ATC) is a high grade tumor that usually shows undifferentiated morphology composed of undifferentiated follicular thyroid cells. Mean age range is 55-65 years with female preponderance. Causative risk factors and etiology is mostly unknown but it has been found to be associated with radiation and iodine deficiency.^{1,2} Anaplastic thyroid carcinoma with cutaneous metastasis is extremely rare and only few cases have been reported till date. FNAC is an important rapid diagnostic method for such lesions. Clinical, histopathological and immunohistochemistry assessment is useful for such lesions for definite confirmation. Only few treatment modalities are

available till date.

2. Case Report

A 66 years male patient presented with multiple nodular swellings on the neck, back and ribs (right side) along with symptoms of neck pain, chest pain, dysphagia, cough and hoarseness of voice. Physical examination showed a midline neck nodular swelling and multiple right side back and ribs swellings. The swelling was firm in consistency, movable and non-tender. Neck computed tomography (CT) scan done which showed evidence of a multi-lobulated heterogeneous soft tissue density lesion with multiple calcific foci at the right lower neck involving the thyroid lobe extending to the right side of the superior mediastinum with compression of adjacent vessels. CT

* Corresponding author.

E-mail address: gagan13690@gmail.com (G. K. Rangari).

scan was suggestive of malignant thyroid lesion. FNAC from the neck, back and ribs swelling was performed and the slides were stained by Papanicolaou stain (PAP) and May-Grunwald Giemsa (MGG) stain. FNAC smears from all sites were cellular and showed many clusters and dispersed population of atypical cells which showed nuclear pleomorphism with prominent nucleoli along with mitosis. Necrosis and Squamoid differentiation was seen at places and many inflammatory infiltrates including neutrophils were also seen in the background. No features of well differentiated thyroid carcinoma were identified.

3. Result

Based on the Cyto-morphological findings, features suggested of high grade epithelial neoplastic lesion with first possibility of Anaplastic thyroid carcinoma.

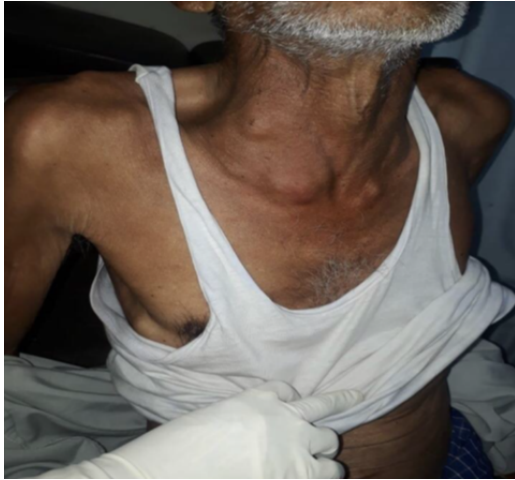

Fig. 1: Multiple nodular neck swelling.

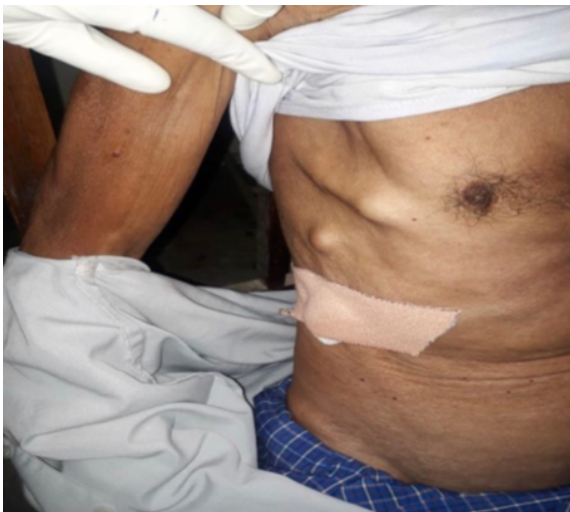

Fig. 2: Ribs nodular swelling.

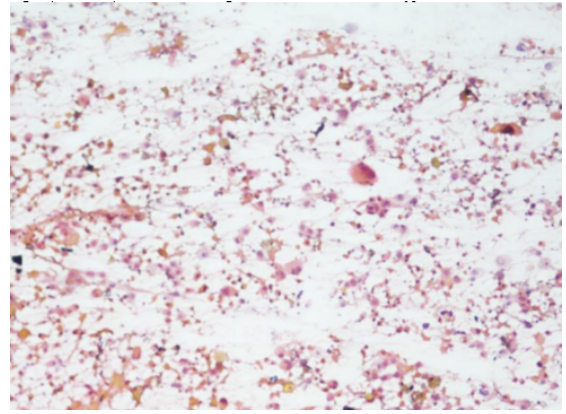


Fig. 3: (10X, PAP). Smears show single and scattered clusters of atypical cells.

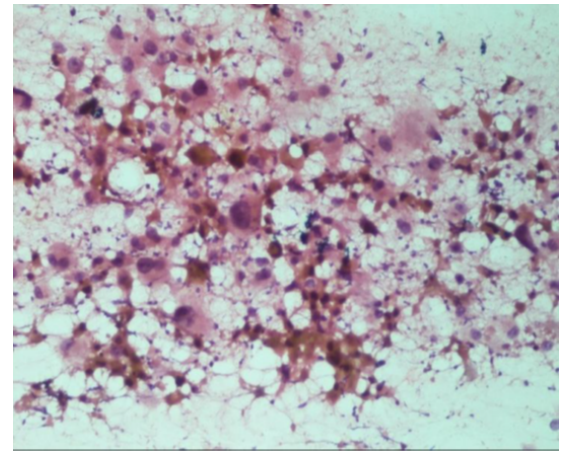


Fig. 4: (20X, PAP) The cells displayed nuclear pleomorphism with enlarged nucleus and moderate to increased amount of cytoplasm.

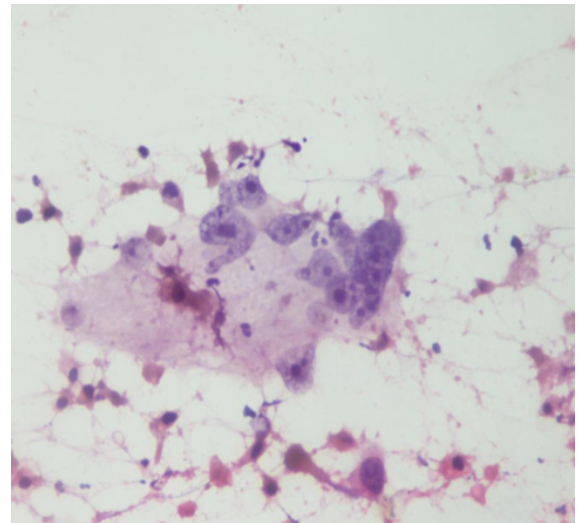


Fig. 5: (40x, PAP) Smears show pleomorphic cells with enlarged nuclei coarse chromatin, prominent nucleoli and moderate amount of cytoplasm.

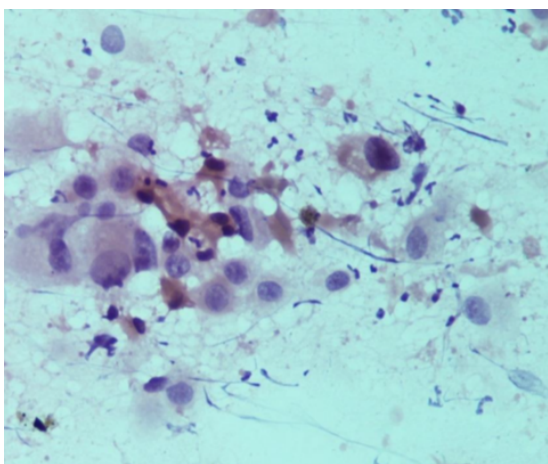


Fig. 6: (40X, PAP) Pleomorphic cells with squamous differentiation. Necrosis also seen in the background.

4. Discussion

Anaplastic thyroid carcinomas (ATC) with cutaneous metastasis often present with solitary or multiple swellings as seen in many studies. Very few cases of cutaneous metastasis have been reported which were diagnosed on FNAC. These tumors represent 5% of all thyroid malignancy with less than 1 year survival rate.^{2,3} Anaplastic thyroid carcinoma prognosis is extremely poor with few available treatment modalities.³ Clinically the patients present with symptoms of pain, dysphagia, hoarseness and breathing difficulty.⁴ Anaplastic thyroid carcinoma can present with metastasis to regional lymph nodes and distant sites. The FNAC findings in our study were similar to that of Lin Yun H et al⁴ study where the patient presented with a nodule on the right lower neck with enlarged unmovable lymph nodes and a chest nodule IHC in this case was negative for TTF and PAX8.⁴ Systemic metastasis occurs most frequently in lung (80%), bone (6-15%) and brain (5-13%).^{5,6} Anaplastic thyroid carcinoma presenting with cutaneous metastasis to the right side back & ribs is very rare and only few cases documented. Cutaneous metastasis occurs in various thyroid malignancy including papillary carcinoma thyroid (41%) which is the most common as reported by Dahl et al⁷ and other studies followed by follicular (28%), medullary (15%) and anaplastic (15%). Danaialan R et al⁸ study on the other hand was a case of ATC with cutaneous metastasis exhibiting exclusively spindle morphology in a 65 year old patient with thyroid swelling and multiple lymphadenopathy and a chest swelling which had developed nine months after initial diagnosis. In our case squamoid differentiation was also seen which can be seen in ATC but it also offered a possibility of Metastatic epithelial lesion probably squamous cell carcinoma however, only few such

keratinized cells were seen and other features of ATC like neutrophilic infiltrate in the background and within the neoplastic cells was seen. Immunohistochemistry could not be done in this case because of non-availability of tissue however, in view of clinical, radiological and pathological features, a diagnosis of ATC was made.

5. Conclusion

The case reported highlights multiple nodular swelling in neck, right side back and ribs. Cyto-morphologically it was suggestive of anaplastic thyroid carcinoma with cutaneous metastasis, which is rare and only few cases documented. ATC with cutaneous metastasis has poor prognosis and few treatment modalities are available.

Dr Gagan Kumar Rangari and Dr Mary June Nongphud contributed to research, literature search and paper writing, Prof Dr Neeraj Dhameja has contributed by giving cytopathological diagnosis of the case, Dr Neelu Kashyap and Dr Shankhanila Mazumdar have contributed by doing fine needle aspiration cytology (FNAC) of the lesion.

6. Conflicts of Interest

All contributing authors declare no conflicts of interest.


7. Source of Funding

None.

References

- Lloyd RV, Osamura RY. Anaplastic thyroid carcinoma. In: WHO classification of tumors of endocrine organs, 4th Edn. Lyon: IARC Press; 2017. p. 104–6.
- Baloch ZW, Volsi VA. Thyroid and Parathyroid. In: Mills SE, Greenon J, editors. In: Sternberg's diagnostic surgical pathology, 6th Edn. Philadelphia: Wolters Kluwer; 2015. p. 561–3.
- Dey P. Thyroid. In: In: Fine needle aspiration cytology interpretation and diagnostic difficulties. 2nd Edn. New Delhi: Jaypee brothers medical publishers; 2015. p. 142–4.
- Yun-Hsuan L, Chiau-Sheng J, Chieh-Shan W, Hsu L. Unusual presentation of anaplastic thyroid carcinoma with diffuse neck and thoracic nodules and hyperthyroidism. *Dermatol Sin*. 2017;35(2):85–7. doi:10.1016/j.dsi.2017.01.003.
- Hunnur B, Thomas BM, Ahmed Z, Umaru N. Cutaneous metastases of follicular carcinoma thyroid diagnosed by fine needle aspiration cytology. *J Evol Med Dent Sci*. 2013;2(14):2293–5. doi:10.14260/jemds/530.
- Altinay S, Taş B. Aynur Özen and Pelin Altinok Süt: Anaplastic thyroid carcinoma with diffuse thoracic skin metastasis. *Oncol Lett*. 2014;7:1767–70.
- Medina MG, Shaif MS, Chadrick R, Yusufshaq, Alameer E. Evans: Papillary Thyroid Cancer Cutaneous Metastasis. *J Clin Trials Case Rep*. 2018;1:109–9.
- Danaialan R, Tetzlaff MT, Torres-Cabala CA, Mays SR, Prieto VG, Bell D, et al. Cutaneous metastasis from anaplastic thyroid carcinoma exhibiting exclusively a spindle cell morphology. A case report and review of literature. *J Cutan Pathol*. 2016;43(3):252–7. doi:10.1111/cup.12618.

Author biography

Gagan Kumar Rangari, Junior Resident  <https://orcid.org/0000-0002-5471-5998>

Mary June Nongphud, Junior Resident

Neeraj Dhameja, Professor

Shankhanila Mazumdar, Junior Resident

Neelu Kashyap, Senior Resident

Cite this article: Rangari GK, Nongphud MJ, Dhameja N, Mazumdar S, Kashyap N. Aggressive thyroid malignancy presenting with unusual site cutaneous metastasis. *IP Arch Cytol Histopathology Res* 2021;6(1):45-48.