



Case Report

Enterobius vermicularis appendicitis –An unexpected guest

Priyatharsini Pari^{1,*}, Bharathi U¹, Priyadharsini J¹, Pammy Sinha¹

¹Dept. of Pathology, Sri Lakshmi Narayana Institute of Medical Sciences, Kudapakkam, 009, Puducherry, India



ARTICLE INFO

Article history:

Received 08-03-2021

Accepted 11-03-2021

Available online 03-04-2021

Keywords:

Enterobius vermicularis

Appendicitis

Pinworm

Diagnosis

ABSTRACT

Background : Enterobius vermicularis appendicitis is one of the rare finding in the appendectomy specimens. It is most often an incidental finding and its role in the causation of acute appendicitis is the topic of controversy.

Case Report : An Indian 27-year-old male presented with symptoms of acute appendicitis. His physical examination and laboratory investigations point towards the diagnosis of acute appendicitis following which open appendectomy was performed. Histopathological evaluation suggests Enterobius vermicularis appendicitis. Patient was given antihelminthic medications and his post-operative course was uneventful.

Conclusion : All appendectomy specimens must be searched for the parasite since it has varied histopathological spectrum, and its presence helps in the initiation of appropriate medications.

© This is an open access article distributed under the terms of the Creative Commons Attribution License (<https://creativecommons.org/licenses/by/4.0/>) which permits unrestricted use, distribution, and reproduction in any medium, provided the original author and source are credited.

1. Introduction

The Vermiform appendix is a rudimentary organ in human beings. It originates from the medial caecal wall and measures about 6-7 cm in length and 0.7 cm in greatest diameter. The position of the appendix varies and its most common location is posterior to the caecum or ascending colon. The function of the appendix is debatable.¹ Enterobius vermicularis also known as Oxyuris vermicularis is one of the most common nematode infection in the world. The infection is common in temperate climate. Enterobius vermicularis causing acute appendicitis is the topic of debate.²

Enterobius vermicularis commonly known as pinworm affect the children and adolescents. Its mode of transmission is feco-oral route. Fomites can also aid in transmission. Following ingestion the, eggs hatch in the intestine and the adult worm resides in the caecum, appendix and colorectum. Extraintestinal presentations are rare.^{3,4} Pinworm infestation in appendix is mostly asymptomatic and is encountered as an incidental finding in appendectomy

specimens.⁴ Hereby we report a case of Acute appendicitis with Enterobius vermicularis infection in a resected appendectomy specimen.

2. Case Report

A 27 year old Indian male admitted in casualty with complaints of lower abdominal pain, fever and vomiting. On examination tenderness was present at McBurney's point. Rovsing's sign was positive. Patient had tachycardia with low grade fever. Blood count revealed leucocytosis with total WBC count of 14,000 cells/cu.mm. ESR and CRP was elevated. USG findings were directed towards the diagnosis of appendicitis. Following which an open appendectomy was performed. The resected specimen measured 8x2.3 cm with an average luminal wall thickness of 0.4 cm. Serosa was congested and lumen was filled with fecolith. Histopathological examination showed surface epithelial ulceration with dense acute and chronic inflammatory cell infiltrate comprising of lymphocytes, eosinophils, neutrophils and plasma cells involving entire thickness of appendix. Lymphoid hyperplasia is also noted. Lumen of the appendix showed enterobius vermicularis.

* Corresponding author.

E-mail address: dr.priyadharsini@gmail.com (P. Pari).

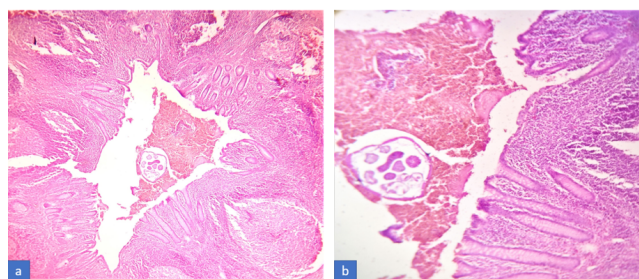


Fig. 1: Microphotograph showing appendix with dense acute and chronic inflammatory cell infiltrate along with lymphoid hyperplasia. (a H&E,10x). Microphotograph showing Enterobius vermicularis with lateral alae in the lumen of the appendix. (b H&E,40x)

3. Discussion

The reported incidence of pinworm infestations, in patients with appendicitis ranges from 0.2-41.8% globally. The mean age of the patients who are infected with Enterobius Vermicularis infections was 24.6 years with a higher preponderance of females.⁵ Poor personal or group hygiene and overcrowding facilitates the infestation of pinworm. This aids in the transmission of egg from person to person either directly from anus to mouth route and hand contamination or indirectly by fomites.⁶ Male pinworm measures 2 to 5 mm in length and the females measures 8 to 13 mm in length. Pinworms preferentially live in cecum and the gravid female migrates from the cecum at night to lay up to 15,000 eggs. These eggs are ingested and they hatch in the duodenum to release larvae which mature during their migration to the large bowel. In general, female pinworms lay their eggs on the anal skin, and some of them may dislodge from the perianal region and fall on clothing or bedding which leads to infection either through ingestion or inhalation of infective eggs or retrograde migration of hatched larvae from the anus to the intestines.⁷

Enterobius vermicularis infection is mostly asymptomatic, sometimes it present with perianal itching, especially at night. In this case no such symptoms have been reported by the patient. However, cases with symptoms in enterobius vermicularis infection have been reported in literature.⁸ The pinworm infection have female preponderance, in this case the affected patient is adult male, hence it is epidemiologically important. In a recent study by Sinha and Dey, out of 140 appendectomy specimens only 3 cases showed E.vermicularis which was an incidental finding.^{5,9} In this case the patient doesn't have symptoms of pinworm infestation and it was an incidental finding. Thus, the histopathological examination of appendix serves two purposes, first it helps in the confirmation of acute appendicitis and secondly it discloses any additional pathological information that is not evident grossly or intraoperatively. The spectrum of histopathological findings of enterobius vermicularis appendicitis range from normal

to various inflammatory patterns. In this case there was dense acute and chronic inflammatory infiltrate. Lumen of the appendix showed pinworms.¹⁰ The cross section of the worm shows the characteristic lateral projections (alae) from its wall. Within the wall numerous annular structures are seen which corresponds to its bowel. Adult male genitals are round and finely granular while gravid female have many oval eggs.¹¹

4. Conclusion

The clinical picture and histopathological findings of Enterobius Vermicularis appendicitis is highly variable. Hence, all appendectomy specimen must be carefully examined for the presence of the parasite, so that appropriate anti helminthic medication is initiated.

5. Conflicts of Interest

All contributing authors declare no conflicts of interest.

6. Source of Funding

None.

References

- Deshmukh S, Verde F, Johnson PT, Fishman EK, Macura KJ. Anatomical variants and pathologies of the vermiform appendix. *Emerg Radiol.* 2014;21(5):543–52. doi:10.1007/s10140-014-1206-4.
- Gatti S, Lopes R, Cevini C, Ijaoba B, Bruno A, Bernuzzi AM, et al. Intestinal parasitic infections in an institution for the mentally retarded. *Ann Trop Med Parasitol.* 2000;94(5):453–60. doi:10.1080/00034983.2000.11813564.
- Ash LR, Orihel TC. Enterobius vermicularis. In: Ash and Orihel's Atlas of Human Parasitology, 5th Edn. Chicago: ASCP Press; 2007. p. 191–5.
- Sodergren MH, Jethwa P, Wilkinson S, Kerwat R. Presenting features of Enterobius vermicularis in the vermiform appendix. *Scandinavian J Gastroenterol.* 2009;44(4):457–61. doi:10.1080/00365520802624227.
- Ahmed MU, Bilal M, Anis K. The Frequency of Enterobius Vermicularis Infections in Patients Diagnosed With Acute Appendicitis in Pakistan. *Glob J Health Sci.* 2015;7(5):196–201.
- Burkhart CN, Burkhart CG. Assessment of frequency, transmission, and genitourinary complications of enterobiasis (pinworms). *Int J Dermatol.* 2005;44(10):837–40. doi:10.1111/j.1365-4632.2004.02332.x.
- Fan CK, Chuang TW, Huang YC. Enterobius vermicularis infection: prevalence and risk factors among preschool children in kindergarten in the capital area, Republic of the Marshall Islands. *BMC Infect Dis.* 2019;19:536.
- Ariyathenam AV, Nachimuthu S, Tang TY, Courtney ED, Harris SA, Harris AM, et al. Enterobius vermicularis infestation of the appendix and management at the time of laparoscopic appendicectomy: Case series and literature review. *Int J Surg.* 2010;8(6):466–9. doi:10.1016/j.ijsu.2010.06.007.
- Sinha RT, Dey A. A Retrospective Study of Histopathological Features of Appendectomy Specimens – What All can Expect? *J Med Sci Health.* 2016;02(02):6–12. doi:10.46347/jmsh.2016.v02i02.002.
- Panidis S, Paramythiotis D, Panagiotou D, Batsis G, Salonikidis S, Kaloutsis V, et al. Acute appendicitis secondary to Enterobius vermicularis infection in a middle-aged man: a case report. *J Med Case Rep.* 2011;5(1):559. doi:10.1186/1752-1947-5-559.

11. Lauwers G, Mino-Kenudson M, Kradin RL. Infections of the gastrointestinal tract. In: Kradin R, editor. Diagnostic pathology of infectious disease. Philadelphia: Elsevier; 2010. p. 246–7.

Priyadharsini J, Associate Professor

Pammy Sinha, Professor

Author biography

Priyadharsini Pari, Assistant Professor

Bharathi U, Assistant Professor

Cite this article: Pari P, Bharathi U, Priyadharsini J, Sinha P. *Enterobius vermicularis* appendicitis –An unexpected guest. *IP Arch Cytol Histopathology Res* 2021;6(1):57-59.