



Case Report

Amlodipine induced generalized gingival overgrowth: A clinical case

Sayani Shome^{1,*}, Amit De², Arup Ghosh¹, Ankita Saraf³

¹Dept. of Oral & Maxillofacial Pathology and Microbiology, Haldia Institute of Dental Sciences and Research, Banbishnupur, West Bengal, India

²Dept. of Periodontology, Haldia Institute of Dental Sciences and Research, Banbishnupur, West Bengal, India

³Dept. of Oral Maxillofacial Surgery, Haldia Institute of Dental Sciences and Research, Banbishnupur, West Bengal, India



ARTICLE INFO

Article history:

Received 27-04-2021

Accepted 06-05-2021

Available online 29-05-2021

Keywords:

Drug induced gingival overgrowth

Amlodipine

Gingival fibroblast

ABSTRACT

Calcium channel blockers (CCB) like Amlodipine, Nifedipine etc are widely used as anti-hypertensive drugs which on chronic intake shows gingival enlargement. It is an iatrogenic response of gingival tissue to these drugs along with other category of medications like antiepileptics and immunosuppressants. A unique case of long standing gingival overgrowth due to prolonged usage of CCB such as Amlodipine in a geriatric patient are portrayed herewith clinical, histopathological attributes and management protocol.

© This is an open access article distributed under the terms of the Creative Commons Attribution License (<https://creativecommons.org/licenses/by/4.0/>) which permits unrestricted use, distribution, and reproduction in any medium, provided the original author and source are credited.

1. Introduction

Gingiva is an oral tissue which are often exposed to local or systemic foreign bodies and it responds accordingly. There are three major causes depicted for gingival enlargement are non-inflammatory, reaction to drugs, chronic inflammatory hyperplasia or combined causes of these three.¹ Drug induced gingival overgrowth (DIGO) are considered as adverse effects to certain drugs like Phenytoin, Cyclosporin, CCBs like Amlodipine, Nifedipine, Nitrendipine, Felodipine etc.² It is hypothesized that there are some genetic preponderance of the host tissue to withstand the drug metabolically which varies individually.² CCBs like Amlodipine are widely prescribed to avoid hypertensive complications and fatal cardiac events in middle aged patients.³ It is a dihydropyridine which causes arterial and peripheral vasodilation to mitigate blood pressure and detectable in gingival crevicular fluid (GCF).^{4,5} Seymour et al. was the pioneer to discover the first incidence of gingival enlargement due to administration of Amlodipine in 1994.⁶ An elderly male patient with chronic

habit of Amlodipine intake presented with generalized gingival enlargement. Appropriate clinical intervention and histopathological evaluation were performed.

2. Case Report

A 72 years old male patient reported to us with a chief complaint gingival overgrowth in the upper and lower arches since 2 years. He was hypertensive since 5 years and on Amlodipine 10 mg/day since then. He was a chronic smoker since 40 years. Extraoral examination revealed no abnormality. Intraorally, pale-pink, non-tender, soft to firm, loulated gingival overgrowth was noted both in maxillary and mandibular arches in lingual and buccal aspect [Figure 1 a,b]. Presence of generalized periodontal pockets and periodontitis were evident. No bleeding on probing was observed. Orthopantomogram showed presence of generalized bone loss on both the arches [Figure 2]. His hematological parameters and pre-operative serology were within normal limit. Gingivectomy followed by oral prophylaxis were opted as treatment options. Gingivectomy specimen was send for histoathology.

* Corresponding author.

E-mail address: sayanishome1991@gmail.com (S. Shome).

Sections stained with Hematoxyline and Eosin [Figure 3a,b,c] revealed the presence of hyperplastic parakeratotic stratified squamous surface epithelium backed by fibrovascular connective tissue stroma. Rete-ridges are narrow and elongated in nature. The most striking feature is the presence of bundles of dense collagen fibres along with spindle-shaped fibroblasts and varying degrees of non-specific chronic inflammatory cell infiltrates, chiefly lymphocytes in the underlying connective tissue.

Healing was uneventful. Patient was followed up for next one year without any sign of recurrence.

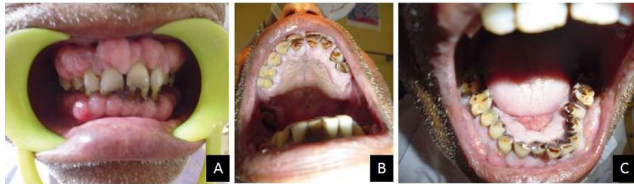


Fig. 1: Intra-oral photographs (A, B, C) showed nodular gingival enlargement in maxillary and mandibular arch.

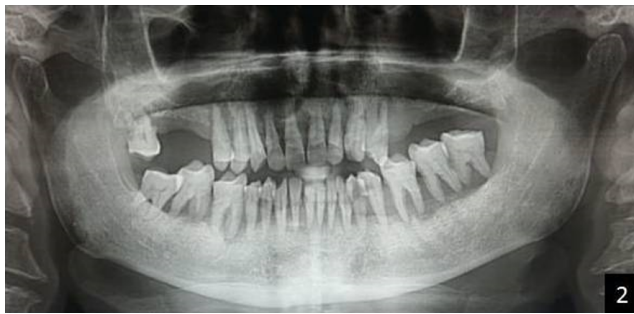

Fig. 2: Orthopantomogram revealed presence of generalized bone loss

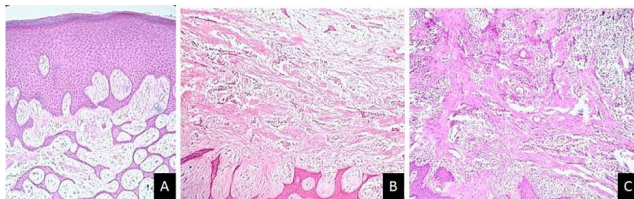


Fig. 3: Photomicrographs (H and E, 10x, 40x, 40x) (A, B, C) revealed epithelial hyperplasia with dense, compact underlying fibrous connective tissue

3. Discussion

Amlodipine is a second-generation dihydropyridine calcium channel blocker which causes gingival hypertrophy with an incidence of 1.7% to 3.3%.⁷ Episodes of CCB induced gingival hypertrophy is 3.3 times more prevalent in males which is often corroborated to deleterious oral

habits pertaining to poor oral hygiene.⁸ Tissue overgrowth involves mechanism of cell proliferation upon the activity of growth factors like Transforming Growth Factor β (TGF β).² Evidence of altered growth kinetics of gingival fibroblasts, increased collagen synthesis, non-collagenous matrix protein synthesis and cytokine expression had already been reported on administration of Amlodipine like CCBs.⁹ The target cell being the gingival fibroblast, where their turn over capacity and function are altered being amalgamated with chronic inflammatory condition of the periodontium.¹⁰ Lafzi et al reported rapid development of gingival hyperplasia within two months of drug intake in patients receiving Amlodipine 10 mg once daily.¹¹ DIGO is also associated with anti-epileptics like Phenytoin and immunosuppressants like Cyclosporins.¹⁰ Among CCBs, Nifedipine is mostly responsible for causing gingival enlargement followed by Amlodipine.¹² In the present case, the patient was a male and on Amlodipine which correlates the previous articles.

Poor oral hygiene is considered as one of the predisposing factors that prevails drug induced gingival enlargement.¹³ Most reports on the relationship between bacterial plaque and gingival overgrowth have been derived from cross-sectional studies, but there is lack of proper evidence.¹³ In our case, poor periodontal health was evident in the patient which was an associated finding along with DIGO. Besides inflammation, proposed non-inflammatory mechanisms upholds that include defective collagenase activity due to decreased uptake of folic acid, blockage of aldosterone synthesis, in adrenal cortex and consequent feedback increase in the adrenocorticotrophic hormone level and upregulation of keratinocyte growth factor consequently leading to overexpression of fibrogenic factor TGF β .¹⁰ On the other hand bacterial toxins in GCF evokes inflammatory changes coupled with drug-induced gingival enlargement.¹⁰ Abnormal individual susceptibility of gingival fibroblasts to definite drug metabolites act as variable factor of DIGO from person to person.¹⁰

Treatment is generally aimed on drug substitution and effective control of local inflammatory factor by improving oral hygiene.¹⁴ Failure of these treatment modalities inevitably invites the way of surgical intervention, though rate of recurrence is not that much low.¹⁰ Surgical intervention is mostly to alleviate aesthetic problems and difficulties in oral functions. Oral prophylaxis and gingivectomy were carried out in our patient, which shows complete absence of recurrences after one year.

4. Conclusion

Drug induced gingival hypertrophy is often encountered in dental clinic but unfortunately it remains neglected from the part of diagnosis and management. Understanding the pharmacokinetics of the concerned drugs and molecular pathology of the target cells are of utmost importance to

allocate the judicious management of such cases.

5. Source of Funding

No financial support was received for the work within this manuscript.

6. Conflict of Interest

The authors declare that they have no conflict of interest.

References

- Hall EE. Prevention and treatment consideration in patients with drug-induced gingival enlargement. *Curr Opin Periodontol*. 1997;4:59–63.
- Nishikawa S. Pathogenesis of Drug-Induced Gingival Overgrowth. A Review of Studies in the Rat Model. *J Periodontol*. 1996;67(5):463–71.
- Henry PD. Comparative pharmacology of calcium antagonists: Nifedipine, Verapamil and diltiazem. *Am J Cardiol*. 1980;46:1047–58.
- Ellis JS, Seymour RA, Monkman SC, Idle JR. Gingival sequestration of nifedipine induced gingival overgrowth. *Lancet*. 1992;39:1382–3.
- Grover V, Kapoor A, Marya CM. Amlodipine Induced Gingival Hyperplasia. *J Oral Health Comm Dent*. 2007;1(1):19–22. doi:10.5005/johcd-1-1-19.
- Jose J, Santhosh YL, Naveen MR, Kumar V. Case report of amlodipine induced gingival hyperplasia - late onset at a low dose. *Asian J Pharm Clin Res*. 2011;4:65–71.
- Sucu M, Yuce M, Davatoglu V. Amlodipine induced massive gingival hypertrophy. *Can Fam Physician*. 2011;57:436–43.
- Prisant LM, Herman W. Calcium Channel Blocker Induced Gingival Overgrowth. *The Journal of Clinical Hypertension*. 2002;4(4):310–1. doi:10.1111/j.1524-6175.2002.01095.x.
- McCulloch CAG, Knowles GC. Deficiencies in collagen phagocytosis by human fibroblasts in vitro: A mechanism for fibrosis? *J Cell Physiol*. 1993;155(3):461–71. doi:10.1002/jcp.1041550305.
- Madi M. Amlodipine-induced Gingival Hyperplasia - A Case Report and Review. *West Indian Med J*. 2015;64(3):279.
- Lafzi A, Farahani RM, Shoja MA. Amlodipine induced gingival hyperplasia. *Med Oral Patol Oral Cir Bucal*. 2006;11:480–2.
- Pradhan S, Mishra P, Joshi S. Drug induced gingival enlargement-a review. *PGNM*. 2009;8.
- Taib H, Ali T, Kamin S. Amlodipine induced gingival overgrowth: a case report. *Arch Orofac Sci*. 2007;2:61–4.
- Mehta DS, Triveni MG, Rudrakshi C. Amlodipine-induced gingival overgrowth. *J Indian Soc Periodontol*. 2009;13(3):160–3. doi:10.4103/0972-124x.60231.

Author biography

Sayani Shome, Assistant Professor

Amit De, Associate Professor

Arup Ghosh, Professor and Head

Ankita Saraf, Assistant Professor

Cite this article: Shome S, De A, Ghosh A, Saraf A. Amlodipine induced generalized gingival overgrowth: A clinical case. *IP Arch Cytol Histopathology Res* 2021;6(2):125-127.