



Case Report

Bilateral Schneiderian (sinonasal) papilloma: An uncommon rare entity

Partho Protim Barman¹, Priyadharisini J^{1,*}

¹Dept. of Pathology, Sri Lakshmi Narayana Institute of Medical Science Medical College & Hospital, Kudapakkam, Puducherry, India



ARTICLE INFO

Article history:

Received 08-05-2021

Accepted 15-05-2021

Available online 29-05-2021

Keywords:

Sinonasal papilloma

Bilateral

Pathology

ABSTRACT

Sinonasal papilloma is a benign surface mucosal neoplasm with variable growth pattern and cytological features. It is a rare benign tumor with tendency to recur and also malignant transformation. The most common sites of inverting papillomata are lateral nasal wall and middle meatus and are usually unilateral. Rarely Bilateral disease can occur, which may be due to direct extension of the tumour, but can also occur as two distinct lesions. The etiology still remains unclear, even though the morphology and clinical behavior of this lesion has been well described. Here we report a case of recurrent bilateral nasal polyposis, histologically diagnosed as Inverted sinonasal papilloma, which is a rare entity.

© This is an open access article distributed under the terms of the Creative Commons Attribution License (<https://creativecommons.org/licenses/by/4.0/>) which permits unrestricted use, distribution, and reproduction in any medium, provided the original author and source are credited.

1. Introduction

Sinonasal papilloma (SNP) is a benign surface mucosal neoplasm with an incidence rate of 0.6 cases/100,000 people/year.¹ It comprises 0.5–4% of all primary nasal tumors,^{2,3} and is more common in males around a 5–6th decade. It is a rare benign tumor with the tendency to recur and even malignant transformation. Its etiology remains still controversial. Sinonasal papilloma can develop from any part of the Schneiderian membrane in the nose and paranasal sinuses, however, the most common sites include the lateral nasal wall and middle meatus. WHO classifies SNP into 3 histological subtypes based on the growth pattern and cytology, which includes Inverted sinonasal papilloma (ISP), Exophytic sinonasal papilloma (ESP), and oncocytic sinonasal papilloma (OSP). An Inverted sinonasal papilloma (ISP) is a distinctive growth pattern of sinonasal papilloma which usually presents as a unilateral nasal polyp, and therefore bilateral involvement of the nose and paranasal sinuses is a rare entity.

2. Case Report

A 60-year-old male patient presented with a chief complaint of nasal blockage more on the right side and nasal discharge for 5 years. It was slowly progressive since onset. The patient also gave past history of similar complaints at 10 and 25 years back, for which he was operated upon in a private clinic and the mass was removed, however, the histopathology reports are not available. On anterior rhinoscopy, a multiple, pinkish, pedunculated, irregular, firm mass was located in the right nasal cavity. X-ray reveals bilateral nasal mass with associated opacification of the adjacent maxillary antrum. A provisional clinical diagnosis of recurrent nasal polyposis was given. The mass was surgically excised by transnasal endoscopic approach and the excised tissue was sent for histopathological examination. On histological examination, the hematoxylin and eosin-stained section showed polypoid tissue covered with non-keratinized stratified squamous epithelium with focal area pseudostratified columnar ciliated epithelium with admixed mucocytes (goblet cells) and intraepithelial neutrophils, which showed inversion into the underlying connective tissue stroma to form nests and islands. The epithelium shows prominent mitosis involving the

* Corresponding author.

E-mail address: priyadharsini158@gmail.com (Priyadharisini J).

basal layer of epithelium, however no evidence of atypia/malignancy. Stroma shows edema and congested vessels along with chronic inflammatory infiltrate composed of lymphocytes, plasma cells, and eosinophils (Figures 1, 2 and 3). The clinicopathologic correlation was suggestive of a final diagnosis of Inverted Sinonasal papilloma (Schneiderian Papilloma).

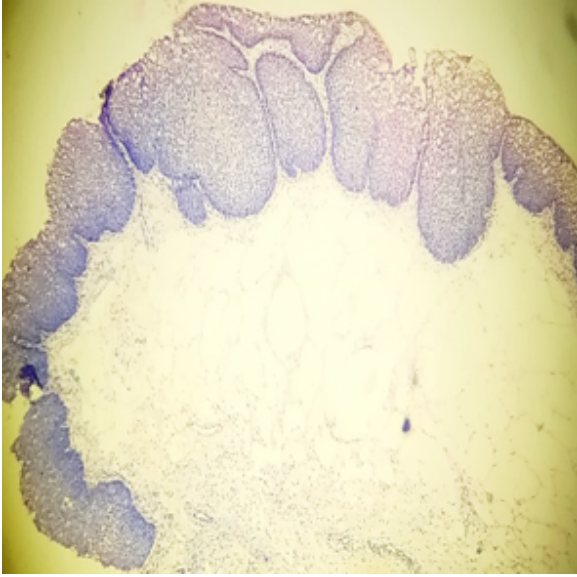


Fig. 1: HPE shows polypoid structure lining by thickened non-keratinizing squamous epithelium with down growth of epithelium into stroma showing edema.(H&E,X100)

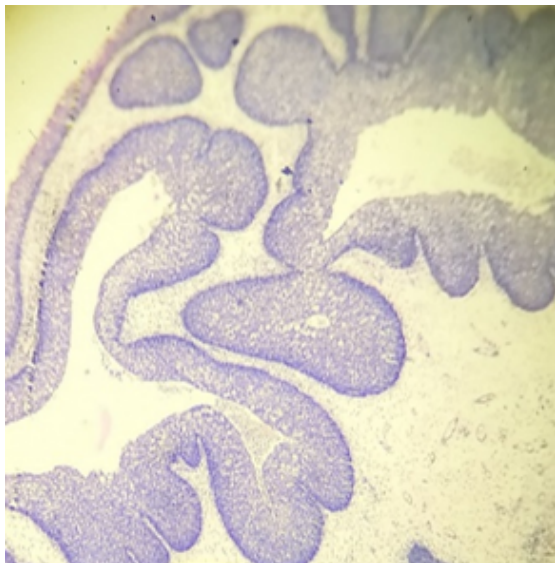


Fig. 2: Transition of ciliated columnar and squamous epithelium with down growth into underlying stroma.(H&E,X100)

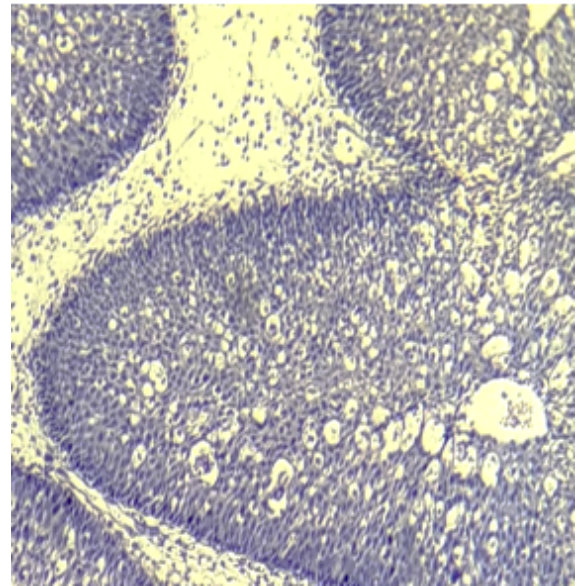


Fig. 3: Shows intraepithelial pseudocysts and neutrophilic abscess. (H&E,X400)

3. Discussion

Inverted papilloma (also known as Transitional cell papilloma, Schneiderian cell papilloma, sinonasal-type papilloma) can be defined as a group of benign neoplasm arising from the sinonasal (Schneiderian) mucosa and is composed of squamous or columnar epithelial proliferation with associated mucous cells.⁴

Sinonasal papilloma usually presents as a unilateral nasal polyp and obstruction, however bilateral involvement is a rare entity. However, in the case of bilateral disease, appropriate clinical evaluation is necessary to exclude the possibility of extension from unilateral disease. Bilateral involvement is considered only if a lesion certainly crosses through a solid midline structure (e.g., nasal septum). Inverted sinonasal Papilloma with bilateral involvement is rare, with a reported rate of up to 5%.⁵ It has been suggested that bilateral and multicentric presentations could be the result of the extension of the lesion through metaplasia of the adjacent mucosa.^{6,7}

Sinonasal papilloma shows variable growth patterns and cytology features on histopathology. WHO classification shows 3 histological subtypes of SNP, which include inverted, exophytic, and oncocytic sinonasal papilloma. Of which Inverted variant shows association with EGFR mutation. Histologically, inverted papillomas have an endophytic/ inverted growth of markedly thickened non-keratinizing squamous epithelial proliferation growing into the underlying connective tissue stroma to form large islands. The epithelium can show variable cellularity composed of squamous, transitional or columnar cells) with admixed mucocytes (goblet cells) and intraepithelial

microcysts /neutrophil collection. A mixed chronic inflammatory cell infiltrate is characteristically seen within all layers of the surface epithelium. The cells are relatively bland, however, may show mild pleomorphism and atypia. The stromal components vary from myxoid to fibrous, with admixed chronic inflammatory cells and variable vascularity.

A series published from the UK had a reported rate of just under 7% for bilateral involvement⁸ whilst other series report rates typically between 2%,4%, and 5%.^{5,9,10} It is mandatory to resect not only the tumor but also to remove the mucoperiosteum, which is the site of origin, in order to avoid recurrences. Intraoperatively histologic control by frozen section is strongly recommended, however not performed regularly.

The recurrence rate of sinonasal papilloma is 5-25%, most commonly within 24 months in many cases as per kinds of literature. The malignant transformation from the sinonasal papilloma is about 2-10%. Malignant transformation and concurrent malignant disease are well recognized in this benign sinonasal tumor with rates in the literature ranging from 6 to 14.5%¹¹ No histological features predict later malignant transformation, rather increased mitosis and atypia are common in recurrent lesions. Inverted and oncocytic variant shows more propensity for malignant transformation than exophytic sinonasal papilloma. The most common form of malignant transformation is squamous cell carcinoma.¹²

Differential diagnosis includes Inflammatory polyp with squamous metaplasia, Rhinosporidiosis, REAH (Respiratory epithelial adenomatoid hamartoma), and sinonasal epithelial malignancies such as Non-keratinising squamous cell carcinoma. Inflammatory polyp with squamous metaplasia shows absent thick non keratinized stratified squamous epithelium or downward growth which is seen in inverted sinonasal papilloma. Rhinosporidiosis imitates intraepithelial pseudocysts of ISP, however, doesn't show a significant degree of inflammation seen in rhinosporidiosis. REAH also shows downward epithelial growth from ciliated columnar surface however lacks epithelial thickening, mucous cells, and microcysts of ISP. Non-keratinizing squamous cell carcinoma mimics the architecture of ISP, however, the cytology of Nonkeratinizing SCC shows high-grade atypia, mitosis, and necrosis.¹³

4. Conclusion

Bilateral inverted papillomas are rare and can present with bilateral nasal obstruction. The treatment of choice is based on the extent of the lesion and should be aimed at avoiding recurrence. Thorough histological examination of sinonasal papilloma is recommended to rule out the possibility of malignant transformation. Patients with bilateral disease should have long-term surveillance for recurrence and/or malignancy

5. Source of Funding

No financial support was received for the work within this manuscript.

6. Conflict of Interest

The authors declare that they have no conflict of interest.

References

1. Buchwald C, Nielsen LH, Nielsen P, Ahlgren P, Tos M. Inverted papilloma: A follow-up study including primarily unacknowledged cases. *Am J Otolaryngol*. 1989;10(4):273–81. doi:10.1016/0196-0709(89)90008-2.
2. Vrabec DP. The inverted schneiderian papilloma: A 25-year study. *Laryngoscope*. 1994;104(5):582–605. doi:10.1002/lary.5541040513.
3. Upadhyaya N, Khandekar S, Dive A, Mishra R. Sinonasal inverted papilloma: A case report and mini review of histopathological features. *J Oral and Maxillofacial Pathol*. 2015;19(3):405. doi:10.4103/0973-029x.174644.
4. Lawson W, Bengner JL, Som P, Bernard PJ, Biller HF. Inverted papilloma: An analysis of 87 cases. *Laryngoscope*. 1989;99:1117–24.
5. Murphy JT, Chandran A, Strachan DR, Sood S. Bilateral inverted papilloma: A report of two cases and review of the current literature. *Indian J Otolaryngol Head Neck Surg*. 2010;62(3):313–6. doi:10.1007/s12070-010-0079-4.
6. Ming-Jie W, Noel JE. Etiology of sinonasal inverted papilloma: A narrative review. *World J Otorhinolaryngol - Head Neck Surg*. 2017;3(1):54–8. doi:10.1016/j.wjorl.2016.11.004.
7. Hosal S, Freeman JL. Bilateral lateral rhinotomy for resection of bilateral inverted papilloma. *Otolaryngol - Head Neck Surg*. 1996;114(1):103–5. doi:10.1016/s0194-5998(96)70292-9.
8. Mirza S, Bradley PJ, Acharya A, Stacey M, Jones NS. Sinonasal inverted papillomas: recurrence, and synchronous and metachronous malignancy. *J Laryngol Otol*. 2007;121(9):857–64. doi:10.1017/s002221510700624x.
9. Lawson W, Kaufman MR, Biller HF. Treatment Outcomes in the Management of Inverted Papilloma: An Analysis of 160 Cases. *Laryngoscope*. 2003;113(9):1548–56. doi:10.1097/00005537-200309000-00026.
10. Hyams VJ. Papillomas of the Nasal Cavity and Paranasal Sinuses. *Ann Otol, Rhinol Laryngol*. 1971;80(2):192–206. doi:10.1177/000348947108000205.
11. Tanvetyanon T, Qin D, Padhya T, Kapoor R, Mccaffrey J. A TrovitiSurvival outcomes of squamous cell carcinoma arising from sinonasal inverted papilloma: report of 6 cases with systematic review and pooled analysis. *Am J Otolaryngol*. 2009;30(1):38–43.
12. Sun Q, An L, Zheng J, Zhu D. Advances in recurrence and malignant transformation of sinonasal inverted papillomas. *Oncol Letters*. 2017;13(6):4585–92. doi:10.3892/ol.2017.6089.
13. Gnepp D, Bishop J. Gnepp's Diagnostic Surgical Pathology of the Head and Neck. In: 3rd Edn. Elsevier; 2020.

Author biography

Partho Protim Barman, Professor

Priyadharisini J, Associate Professor

Cite this article: Barman PP, Priyadharisini J. Bilateral Schneiderian (sinonasal) papilloma: An uncommon rare entity. *IP Arch Cytol Histopathology Res* 2021;6(2):132-134.